

## Case Series

# Experience with virtual planning and stereolithographic models in plastic surgery

Jorge Gaviria-Pinzon\*, Giancarlo Ruiz, Maria Paula Garcia, Carlos David Gutierrez, Luis Eduardo Bermudez

Department of Plastic and Reconstructive Surgery, Hospital Militar Central Colombia, Nueva Granada Military University, Bogota, Colombia

**Received:** 15 July 2022

**Revised:** 28 July 2022

**Accepted:** 30 July 2022

### \*Correspondence:

Dr. Jorge Gaviria-Pinzon,

E-mail: [jorgegaviria10@gmail.com](mailto:jorgegaviria10@gmail.com)

**Copyright:** © the author(s), publisher and licensee Medip Academy. This is an open-access article distributed under the terms of the Creative Commons Attribution Non-Commercial License, which permits unrestricted non-commercial use, distribution, and reproduction in any medium, provided the original work is properly cited.

## ABSTRACT

The use of stereolithographic models and virtual planning in plastic surgery have been used mainly in craniomaxillofacial reconstructions secondary to trauma, oncological reconstructions, orthognathic surgery and correction of craniofacial developmental anomalies of craniofacial development, among others, making surgical planning a less tedious process and reducing surgical time. In this article we present the experience using this technology in a referral center. Eight cases are exposed where the different applications of virtual planning and 3D models can be evidenced. Pre-op and post-op images are presented showing the similarity with the planning. We have implemented its use not only for facial trauma reconstructions with free flaps, but also for the correction of sequelae, correction of complex craniofacial abnormalities, oncological defects, and hand reconstructions. Our experience has been favorable since it allowed us to obtain satisfactory functional and predictable results and a reduced surgical time, especially in complex cases. If available, this technology should be considered as a useful tool to obtain predictable and reliable results.

**Keywords:** Stereolithographic model, Virtual planning, Plastic surgery, 3D model, Head reconstruction, Head trauma

## INTRODUCTION

The use of new technologies in the field of plastic surgery has made it possible to improve post-operative results, reduce surgery times and reduce the morbidity of complex surgical procedures.<sup>1</sup> Virtual planning and the use of stereolithographic models began to be used in reconstructive procedures since the late 1980s, gaining greater popularity in recent years as their accessibility and availability increased. These technologies have been used mainly in craniomaxillofacial reconstructions secondary to trauma, oncological reconstructions, orthognathic surgery and correction of craniofacial developmental anomalies.<sup>2</sup> By means of these tools, a high-precision physical model of both the patient and the defect to be reconstructed can be manufactured. Additionally, custom pre molded plates and personalized

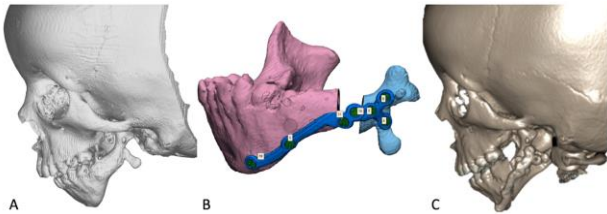
anatomical implants can be manufactured, making surgical planning a less tedious process and more in line with the reconstructive objective; in addition, it offers a guide for an adequate intraoperative execution, obtaining functional results with technical precision and aesthetic contour.<sup>3</sup> We present a case series of patients who underwent virtual planning and printing of stereolithographic models at the Hospital Militar Central, in Bogota, Colombia.

## CASE SERIES

### Case 1

A five-year-old patient diagnosed with Goldenhar Syndrome and hemifacial microsomia, who underwent two previous mandibular distraction osteogenesis without

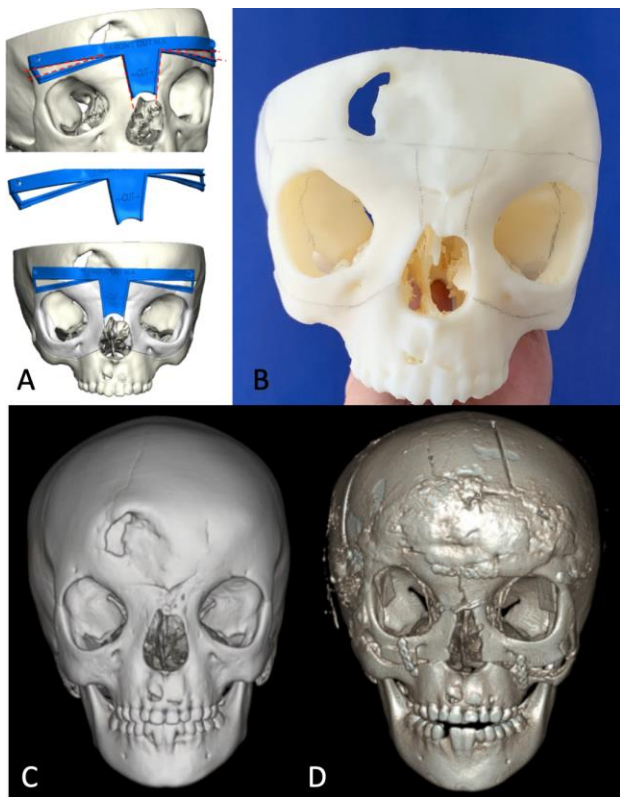
success. Virtual planning was made with the aim of performing an advancement osteotomy with bone graft and preformed mandibular plate to achieve facial symmetry. Figure 1 shows the preoperative 3D CT scan, the virtual planning of the advancement osteotomy with the adaptation of the preformed plate (A-B) and the CT of the patient immediate postoperative result (C).



**Figure 1 (A-C): Preoperative CT reconstruction, presurgical planning and postoperative result.**

### Case 2

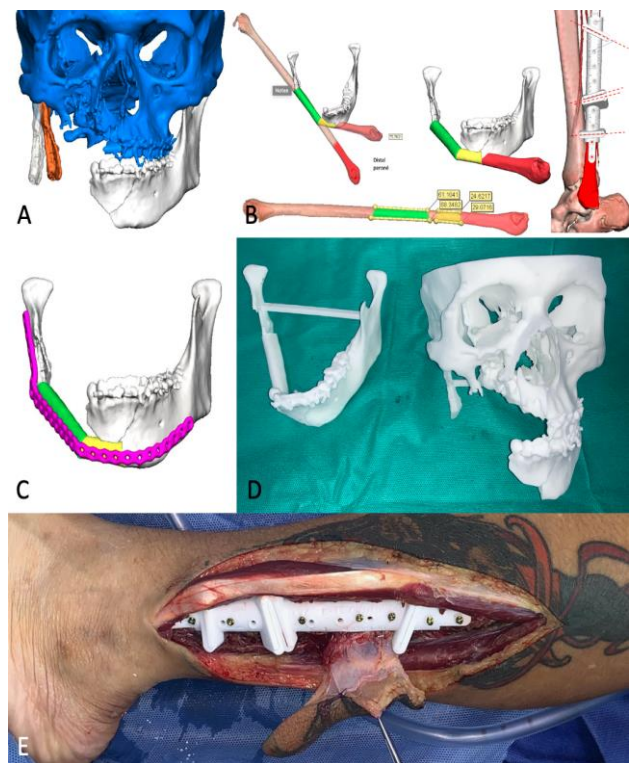
Six-year-old patient diagnosed with ocular hypertelorism and frontal encephalocele, the latter corrected during the first months of life. Figure 2 shows the planning of the cutting guides to achieve bipartition and medialization of both hemifaces. Additionally, the complete printed model was requested, which facilitated communication with the neurosurgery service and served as a guide during the surgery period.



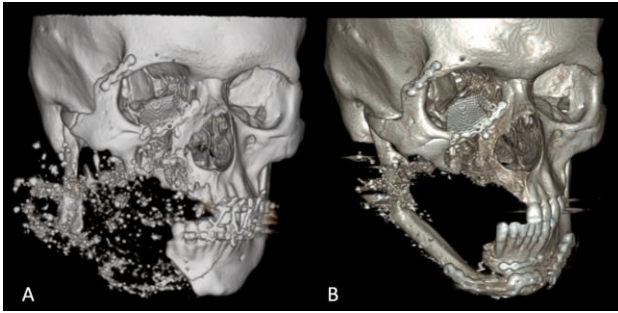
**Figure 2 (A-D): Planning and printing of cutting guides, 3D printed model, preoperative CT scan and postoperative result.**

### Case 3

Twenty-year-old patient with a high-velocity firearm injury in the face, and multiple comminuted fractures in the middle and upper third, with a mandibular bone gap associated. He underwent multiple surgical debridements and an open reduction with internal fixation of his facial fractures. During virtual planning, correction of the external rotation of the right mandibular segment was requested. Cutting guides were designed to regularize the ends of the left and right segments, as well as cutting guides for the design of the fibular free flap used for reconstruction and continuity, to reach the desired mandibular contour. Once the bony contour was restored, a mandibular reconstruction plate was designed with an angle that could suit the reconstruction for an adequate fixation of the mandibular segments and the fibular free flap. Printed models were requested to allow intraoperative corroboration of the fibula flap and the desired design of the mandibular plate. Figure 4 shows the preoperative computed tomography, and the postoperative computed tomography 6 months later, observing an adequate survival and integration of the flap.



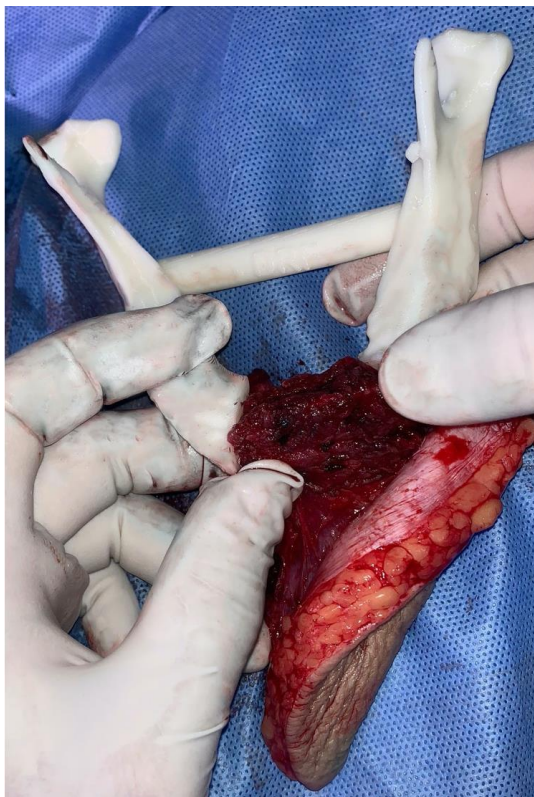
**Figure 3 (A-E): Medialization of external rotation presented in the right mandibular segment. Planning the cutting guides in the fibula to achieve the desired mandibular reconstruction. Pre contoured mandibular reconstruction plate design. Stereolithographic models for mandibular reconstruction with fibular free flap. Use of custom printed cutting guides during surgery.**



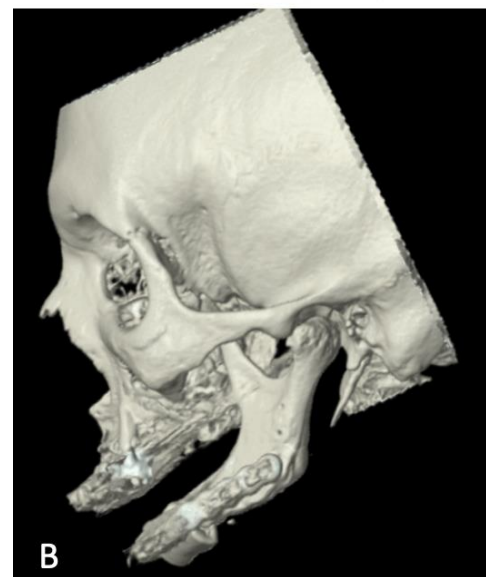
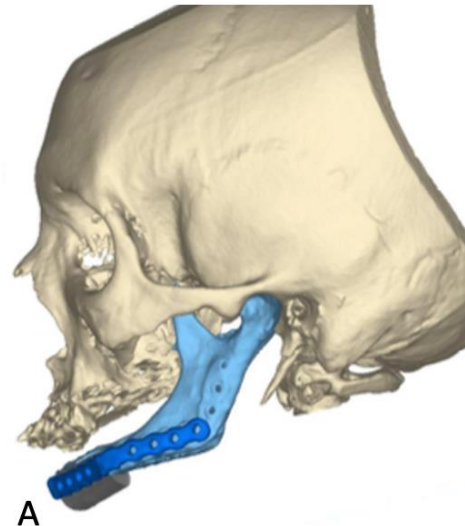
**Figure 4 (A and B): Presurgical CT and postoperative computed tomography 6 months later.**

#### Case 4

A seventy-six-year-old edentulous patient with a history of mandibular osteoradionecrosis upon receiving radiotherapy for squamous cell carcinoma of the tongue, who was initially managed with a mandibular reconstruction plate and partial mandibulectomy, with subsequent exposure of osteosynthesis material. Virtual planning was performed to simulate plate removal and mandibular segment repositioning, to design cutting guides for the fibula, and to design a customized mandibular plate. Figure 5 shows a printed model where the adequate design of the fibular free flap is corroborated. Figure 6 shows the correlation between virtual planning and immediate postoperative results.



**Figure 5: Stereolithographic model confirming the adequate design of the fibular free flap for mandibular reconstruction.**

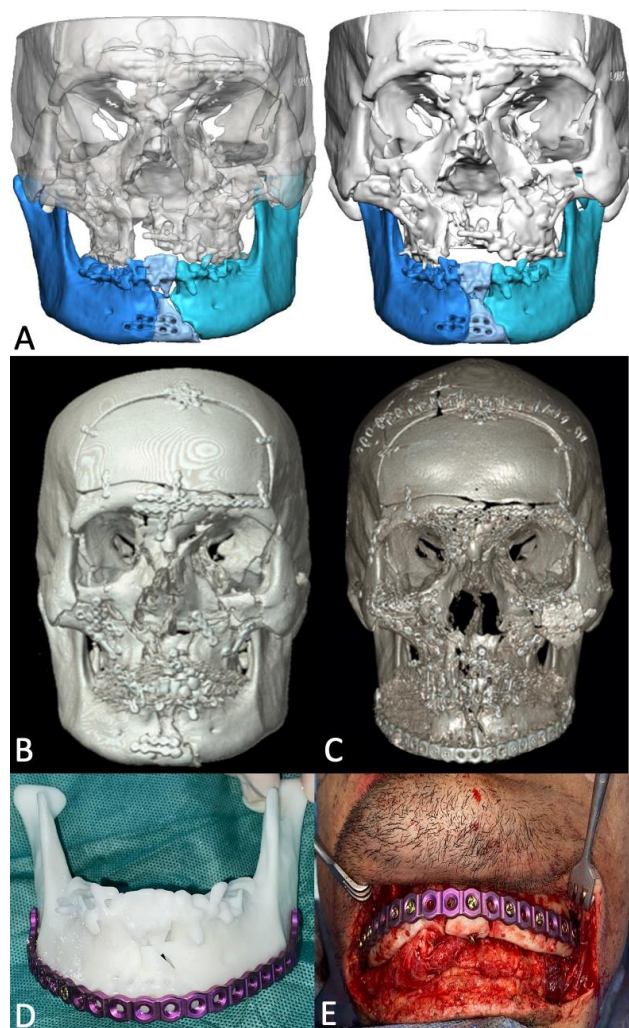


**Figure 6 (A and B): Comparison of virtual planning with results in the postoperative.**

#### Case 5

A nineteen-year-old patient who suffered a traffic accident and diagnosis of panfacial fractures, managed at the referral center with open reduction and internal fixation with screws and plates. The patient was admitted to our institution 3 weeks later, an inadequate reduction associated with an increased mandibular transverse diameter was observed. Initially, we performed a removal of osteosynthesis material with a new reduction of the facial fractures. Nevertheless, the inadequate reduction of the mandible persisted, for which a study was requested. In the virtual planning, simulation of the removal of the previous reconstruction plate and medialization of the mandibular segments was performed to correct the increased transverse diameter. Likewise, a customized double angle mandibular reconstruction plate was requested to achieve the planned fixation. The pre- and post-op tomography shows adequate correction of facial

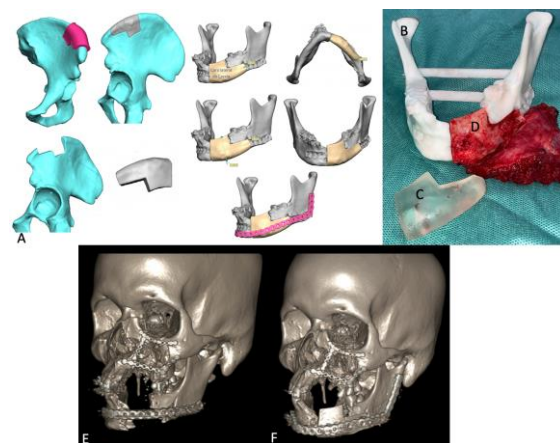
fractures and recovery of the mandibular transverse diameter (Figure 7).



**Figure 7 (A-E): Virtual planning for reduction of mandibular transverse diameter. Preoperative CT scan with increased mandibular transverse angle. Postoperative CT. Printed model and customized mandible plate. Open reduction internal fixation with the customized plate.**

#### Case 6

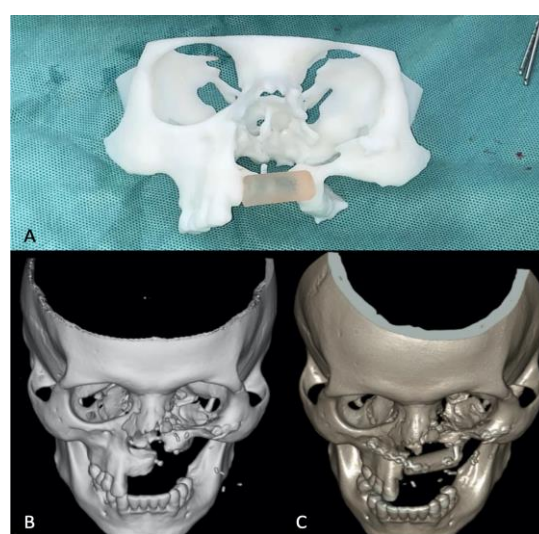
A eighteen-year-old patient with a self-inflicted gunshot wound, presenting multiple facial fractures associated with a mandibular segmental bone defect. He was brought in for multiple surgical scrubs and fixation of facial fractures. Later planning and model for mandibular reconstruction with iliac crest free flap was proposed. The cutting guides for the donor area and the model were designed and printed, as well as the customized mandibular reconstruction plate. Figure 8 shows the printed model of the mandible and the flap, as well as the adequate design of the iliac crest flap. It also shows the presurgical and postsurgical tomography with a satisfactory result.



**Figure 8 (A-F): Iliac crest free flap cutting guide and mold for mandibular reconstruction. 3D Printed model with the mandibular gap. 3D Printed model of the flap. Iliac crest free flap filling the bone gap. Preoperative CT with mandibular bone defect. Postsurgical CT with iliac crest free flap reconstruction.**

#### Case 7

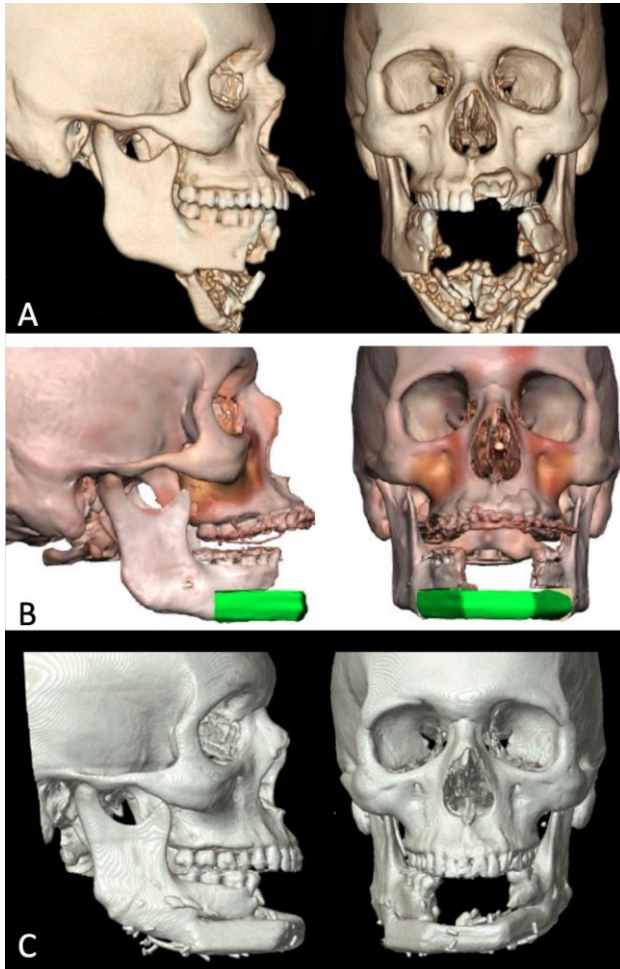
A thirty-seven-year-old patient with sequels of a gunshot wound to the facial region, presented a segmental bone defect at the level of the left maxilla. Virtual planning and printing of the stereolithographic model. He presented a segmental bone defect at the level of the left maxilla. Virtual planning and impression of the stereolithographic model were designed with cutting guides to regularize the maxillary defect and to harvest the fibula flap. The customized titanium plate was requested to achieve a stable fixation according to patient's anatomy. Figure 9 shows preoperative tomography and immediate postoperative result.



**Figure 9 (A-C): Facial middle third and flap 3D printed stereolithographic models. Preoperative CT. Postoperative CT with fibular free flap filling the maxillary gap.**

### Case 8

A twenty-seven-year-old patient who presented facial trauma due to an explosive device. On admission, there was evidence of segmental bone loss from in the anterior part of the mandible. Virtual planning was carried out with printing of models and customized plates. Figure 10 shows the pre-surgical tomography, the virtual planning and the results 18 months post-surgery observing results in accordance with the planning. The mandibular plate was removed because of the increased projection of the chin.



**Figure 10 (A-C): Preoperative CT, computer assisted virtual planning and CT scan 18 months postoperative.**

### DISCUSSION

Stereolithography consists in converting a two-dimensional image of a CT scan into a three-dimensional model made of different materials as necessary for the surgical purpose.<sup>2</sup> Among the materials described so far are resins, starch cellulose, hydroxyapatite, calcium phosphate cements and, more recently, multilayered models made of different materials. There have been described models with three layers, the first one using salt

granules to represent the bone. The latter can be made up of salt granules to represent the bone part of the model, silicone for the subcutaneous cellular tissue and polyurethane for the skin, to obtain a model that faithfully represents the patient and achieve surgical planning with high levels of precision, reliability and accuracy.<sup>4</sup> To determine the material to be used, the surgeon and its multidisciplinary team must evaluate the material's properties, price, and whether admission to the surgical field is required, given the need for resistance to the sterilization process.<sup>5</sup>

The planning and manufacturing process requires a CT scan with slice thickness from 0.5 to 1 mm and a software that allows planning, modification, and representation of post-operative results. This process permits the printing of representative models of the current state of the patient and the desired result, as well as the printing of cutting guides to obtain custom-made osteotomies.

Some of the advantages of using stereolithographic models are an increase in surgical prediction reliability, improvements in the efficiency and precision of the procedure, reduction in surgical times and increases in patient safety.<sup>6-8</sup> Additionally, it favors the learning process of medical students and residents, as well as the education of both the patient and the family about their clinical condition and what is planned to be done.<sup>2,4</sup> As well as the education of not only the patient but also the family about the patient's clinical condition and the surgical plan. Some authors found it useful in reducing the mistakes during the fixation of the plates.<sup>9</sup>

Among the disadvantages found we have a higher production cost, the need for a previous meeting between the surgical group and the manufacturers, and the time required to send the material to the hospital and its sterilization.<sup>10</sup>

In our experience, stereolithographic models have been very useful. Our institution is a trauma referral hospital, so we have implemented the use of these not only for facial trauma reconstructions with free flaps, but also for the correction of sequelae. Likewise, we have carried out planning for the correction of complex craniofacial abnormalities, oncological defects, and hand reconstructions. The planning has been carried out using the Nemotec and Nemofab software from Walter Lorenz®, and Techfit from Sampedro®.

### CONCLUSION

The use of virtual planning and stereolithographic models in plastic surgery has a wide field of application. Our experience has been favorable since it allowed us to obtain satisfactory functional results and specially in complex cases it saved surgical time, as it was not consumed by planning the osteotomies, given that this time was used during the previous planning.

*Funding: No funding sources*

*Conflict of interest: None declared*

*Ethical approval: Not required*

## REFERENCES

1. Antony AK, Chen WF, Kolokythas A, Weimer KA, Cohen MN. Use of virtual surgery and stereolithography-guided osteotomy for mandibular reconstruction with the free fibula. *Plast Reconstr Surg*. 2011;128(5):1080-84.
2. Cunningham LL Jr, Madsen MJ, Peterson G. Stereolithographic modeling technology applied to tumor resection. *J Oral Maxillofac Surg*. 2005;63(6):873-8.
3. Maniskas S, Pourtaheri N, Chandler L, Lu X, Bruckman KC, Steinbacher DM. Conformity of the Virtual Surgical Plan to the Actual Result Comparing Five Craniofacial Procedure Types. *Plast Reconstr Surg*. 2021;147(4):915-24.
4. Ueda K, Kino H, Katayama M, Hirota Y. Simulation Surgery Using 3D 3-layer Models for Congenital Anomaly. *Plast Reconstr Surg Glob Open*. 2020;8(8):e3072.
5. Mehera P, Miner J, D'innocenzo R, Nadershah M. Use of 3-D Stereolithographic Models in Oral and Maxillofacial Surgery. *Journal of Maxillofacial and Oral Surgery*. 2011;10(1): 6-13.
6. Miranda J, Barajas H, Miranda E. Efectividad del modelo estereolitográfico en cirugía predictiva craneomaxilofacial en el Hospital Regional «General Ignacio Zaragoza» del ISSSTE. Reporte de investigación. *Revista mexicana de Cirugía Oral y Maxilofacial*. 2014;10(2):57-64
7. Hsu SS, Gateno J, Bell RB. Accuracy of a computer-aided surgical simulation protocol for orthognathic surgery: a prospective multicenter study. *J Oral Maxillofac Surg*. 2013;71(1):128-142.
8. Maniskas S, Pourtaheri N, Chandler L, Lu X, Bruckman K, Steinbacher D. Conformity of the Virtual Surgical Plan to the Actual Result Comparing Five Craniofacial Procedure Types. *Plast Reconstr Surg*. 2021;147(4):915-24.
9. Fleury CM, Sayyed AA, Baker SB. Custom Plates in Orthognathic Surgery: A Single Surgeon's Experience and Learning Curve. *J Craniofac Surg*. 2022;10.1097/SCS.
10. Chang YM, Wei FC. Fibula Jaw-in-a-Day with Minimal Computer-Aided Design and Manufacturing: Maximizing Efficiency, Cost-Effectiveness, Intraoperative Flexibility, and Quality. *Plast Reconstr Surg*. 2021;147(2):476-9.

**Cite this article as:** Gaviria-Pinzon J, Ruiz G, Garcia MP, Gutierrez CD, Bermudez LE. Experience with virtual planning and stereolithographic models in plastic surgery. *Int Surg J* 2022;9:1607-12.