

## Original Research Article

# Effectiveness of mammogram and ultra-sonogram in the diagnosis of breast cancer in asymptomatic women at Central Karnataka

Sunil S. Byadgi<sup>1</sup>, Vijaya Kumar<sup>2</sup>, Pramod Heggeri<sup>2</sup>, Nagaraj V. Patil<sup>2</sup>,  
Parvathreddy Yerriswamy<sup>3\*</sup>, V. L. Jayasimha<sup>4</sup>, Nishanth Somashekar<sup>5</sup>, Vinodkumar C. S.<sup>4</sup>

<sup>1</sup>Department of General Surgery, Basaveshwara Medical College and Research Centre, NH-4, Bypass Road, Chitradurga, Karnataka, India

<sup>2</sup>Department of General Surgery, <sup>3</sup>Department of Emergency Medicine, <sup>4</sup>Department of Microbiology, S. S. Institute of Medical Sciences and Research Centre, Davangere, Karnataka, India

<sup>5</sup>S. S. Institute of Medical Sciences and Research Centre, Davangere, Karnataka, India

**Received:** 13 July 2022

**Revised:** 27 July 2022

**Accepted:** 28 July 2022

### \*Correspondence:

Dr. Parvathreddy Yerriswamy,

E-mail: [drparvathreddy@gmail.com](mailto:drparvathreddy@gmail.com)

**Copyright:** © the author(s), publisher and licensee Medip Academy. This is an open-access article distributed under the terms of the Creative Commons Attribution Non-Commercial License, which permits unrestricted non-commercial use, distribution, and reproduction in any medium, provided the original work is properly cited.

## ABSTRACT

**Background:** Breast cancer is one of the most common cancers among women around the world. Some occult breast cancers can be missed when using ultrasound or mammogram alone. Considering this background, the study was performed to highlight the improved diagnostic efficacy of identifying breast cancer when using both ultrasound and mammogram as a combined modality.

**Methods:** A total of 150 cases of suspected breast cancer were studied over a period of 2 years. Ultrasonography, and mammography were done by two independent radiologists and the results were analyzed. The patients were tested for BRCA1/2 gene mutations. Histopathology was done finally to confirm the diagnoses.

**Results:** The 39 cases out of 150 asymptomatic women screened for breast cancer showed that they were positive for breast cancer by histopathology and 38 were positive by mammogram and ultra-sonogram. Cancer was prominently diagnosed in the age group of more than 40 years (92.3%) and 82.1% of women were in premenopausal stage. High BMI had a statistically significant correlation with breast cancer. The 71.7% of breast cancer cases were obese and 25.6% were overweight individuals. 89.7% of breast cancer cases were from the urban population. Detection of mutation in the BRCA gene showed 28 cases with a mutation in the BRCA-1 gene and 4 cases with a mutation in the BRCA-2 gene.

**Conclusions:** The study confirms that mammography in addition to ultrasonography improves the sensitivity of detection of occult breast cancer in asymptomatic women.

**Keywords:** Ultrasonography, Mammography, Breast cancer, Histopathology

## INTRODUCTION

The incidence of breast cancer is on rising among young women in India. An estimated 2.3 million females were diagnosed with breast cancer in the year 2020, accounting for approximately 24.5% of all the cancer cases worldwide.<sup>1</sup>

Breast cancer is more common in the younger age group. Almost 50% of all stages of the diseases are in the age group of 25-50. Breast cancer survival in the advanced stage of the disease becomes difficult and around 50-55% of women in India suffer from stage 3 and 4 compared to 75% of women in developed World have poor survival and high mortality.<sup>2-4</sup>

The only way to bring down the incidence of breast cancer among young adults is by increasing awareness and emphasizing that breast cancer is a treatable disease and chances of survival are higher if it's detected in time. Diagnosing the disease at a primitive stage increases the chances of cure and also reduces morbidity and mortality.<sup>5-7</sup> The aim of the study was to screen asymptomatic women for breast cancer using mammogram and ultrasound and comparing it with the histopathology reports and to recognize any diagnostic gains that might be available when both the diagnostic tools are used complementary to one another.

## **METHODS**

### ***Study design***

This is a prospective cross-sectional study. Patients who come to the outpatient department of the oncology unit of S. S. institute of medical sciences and research centre, Basaveshwara medical college and research centre, and Sukshema hospital, Davangere were included in the study. SPSS Statistics version 26 with build 1.0. 0.1275 was used to analyze data.

### ***Ethical approval***

The study protocol was approved by institutional ethics review board, S. S. institute of medical sciences and research centre.

### ***Number of samples***

The 150 cases of suspected breast cancer were included in the present study over the period of 2 years from April 2020 to March 2022.

### ***Demographic features***

Demographic features such as employment status, body mass index, times of pregnancy and delivery, history of breastfeeding, menstrual history, smoking, insomnia, diets and alcohol, medication history, and hormone replacement were taken.

### ***Inclusion criteria***

The 150 asymptomatic women referred for routine breast examination were included in the study.

### ***Exclusion criteria***

Women who were diagnosed with breast cancer and who refused to consent to the study were not considered not included in the study.

### ***Investigations done***

***Mammography:*** Mammography was performed using dedicated equipment, mammographic cassettes, and

radiographic films, and standard craniocaudal, mediolateral and oblique projections were taken. Immediately after the examination, the mammograms were evaluated separately by 2 radiologists, both experts in the field of breast examination.<sup>9,10</sup>

***Ultrasonography:*** Ultrasonographic examination was performed using Samsung 730 Pro, with a linear 10-13 MHz probe. The patients were examined in the supine position with their arms raised above their head. All four quadrants of the breast as well as the nipple were studied, and the examination included classification of the parenchymal structures according to the presence of hypoechoic glandular tissue or hyperechoic fibrous tissue.<sup>10,11</sup> The lesions were identified due to the presence of nodular masses, posterior shadowing or anomalies/distortions in the breast structure, and they were further characterized by the evaluation of the form, margins, vascularization and changes in the surrounding echo structure.

### ***BRCA gene test***

The BRCA gene test is a blood test that uses DNA analysis to identify mutation in either one of the two breast cancer susceptibility genes-BRCA1 and BRCA2.<sup>4-6</sup>

### ***Histopathological evaluation***

Biopsies were sent from all 150 asymptomatic cases for histopathological evaluation for histological type, stage, grade, lymphovascular invasion, and lymph node involvement by microscopic examination of hematoxylin and eosin-stained tissue sections.<sup>5,7,11</sup>

### ***Statistically tool***

Descriptive statistics was used for the analysis of the result using SPSS 20 software.

## **RESULTS**

### ***Demographic features***

Among 150 asymptomatic patients, 55 women were of the age 30-40 years, 48 women were of the age 41-50 years, 32 women were of the age >50 years and 15 women were of the age <30 years. The 120 women were from the city and 30 women were from rural backgrounds. The body mass index of 150 women revealed that 110 women were obese, 35 were overweight and 5 women were normal. The 105 (70%) were premenopausal and 45 (30%) were postmenopausal (Table 1). The average age at menopause in the postmenopausal subjects was 46.4 years (SD=0.48). The average age for menarche in all subjects was 14.2 years (SD=1.06). There were 148 (98.67%) subjects who had at least one child during enrollment for the study and who had breastfed at least 12 months.

**Table 1: Demographic features of the study population.**

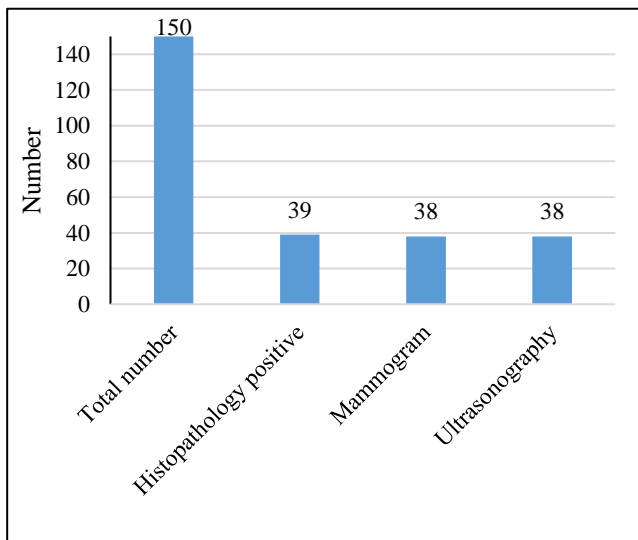
Characteristics	Numbers (%)
<b>Age (Years)</b>	
<30	15 (10.0)
30-40	55 (36.7)
41-50	48 (32.0)
>50	32 (21.3)
<b>Background</b>	
Rural	30 (20.0)
Urban	120 (80.0)
<b>Body mass index (BMI)</b>	
Obese	110 (73.3)
Overweight	35 (23.3)
Normal	5 (3.4)
<b>Menopausal status</b>	
Pre-menopause	45 (30.0)
Post-menopause	105 (70.0)

**Mammography study**

Out of the 150 asymptomatic women examined by mammogram, 38 women showed breast lesions and 112 asymptomatic women did not show any lesion by mammogram.

**Ultrasonography**

150 asymptomatic women were examined by ultrasonography. Thirty-eight cases showed the typical signs of malignancy (Figure 1).



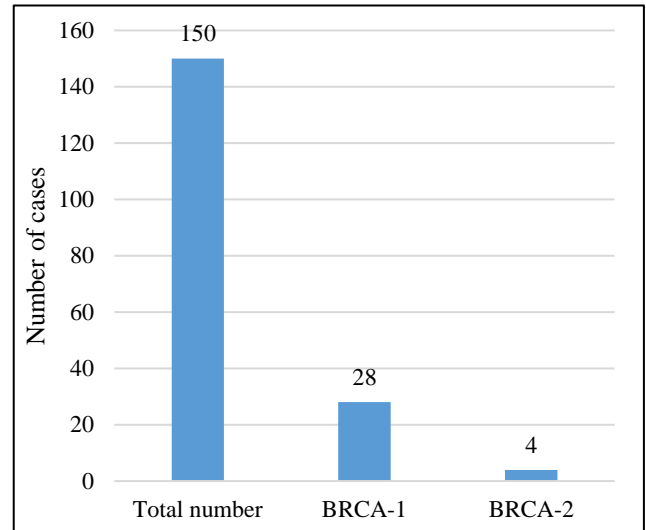
**Figure 1: Incidence of breast cancer by histopathology, mammogram and ultrasonography.**

**Histopathological study**

In our study, invasive ductal carcinoma was observed in 36 cases and carcinoma with medullary was seen in 3 cases (Figure 1).

**BRCA gene test**

Out of 150 asymptomatic women tested for the BRCA gene, 28 women showed a mutation in the BRCA-1 gene and 4 women showed a mutation in the BRCA-2 gene (Figure 2).



**Figure 2: Incidence of BRCA 1 and 2 among asymptomatic women.**

**Comparison of histopathological findings with mammogram, ultra-sonogram, and BRACA genes**

Among 39 cases that showed histopathological changes, both mammogram and ultra-sonogram was positive in 38 cases, and negative in one histopathological positive case. Among 39 histopathological positive cases, 22 showed mutation for the BRCA-1 gene and 1 woman showed mutation for the BRCA-2 gene.

**DISCUSSION**

A total of 39 cases of breast cancer were identified in this study. None of the cases were symptomatic. Demographic data revealed that the breast cancer cases identified in this study were primarily diagnosed in the age group of more than 40 years (92.3%). There were 32 premenopausal cases accounting for 82.1% of the identified breast cancer cases and 7 postmenopausal cases accounting for 17.9%. Our finding corroborates with the finding of Li et al which showed that premenopausal cases accounted for a higher prevalence of breast cancer.<sup>8</sup>

This study found that a high BMI had a statistically significant correlation with breast cancer. The 71.7% of breast cancer cases were obese and 25.6% were overweight individuals. With the changes in lifestyle and improvements in living conditions in India, overweight and obese people account for a large proportion of the population. Increasing urbanization and westernization associated with changing lifestyle and food habits has led breast cancer to attain the top position in the urban

population. The 35 breast cancer cases were from urban population accounting for 89.7%.

Among the investigations done, Histopathologically proved breast cancer cases were 39 out of 150 cases. Mammogram and ultra-sonogram were positive in 38 cases. Out of 150 cases subjected to a blood test for detection of mutation in the BRCA gene revealed 28 cases showed a mutation in the BRCA-1 gene and 4 showed a mutation in the BRCA-2 gene. Among 32 cases positive for the BRCA gene, 18 of the cases were positive for breast cancer by mammogram, ultrasonogram, and by histopathology. Furthermore, early-onset breast cancer patients in the Indian population were found to have BRCA1/2 mutations. Notably, the occurrence rates of BRCA2 mutations were lower than those of BRCA1 in India.

Breast cancer is the second most prevalent cancer in the world and the most frequent among women, therefore it is crucial to diagnose the disease efficiently.<sup>9</sup> Currently, two modalities namely mammography and ultrasonography are primarily used for the initial diagnosis of breast cancer.<sup>10</sup> Mammography is the method of choice in the study of breast carcinoma in asymptomatic women over 40 years of age, and it is considered the most sensitive instrumental examination in the early diagnosis of clinically occult carcinoma.<sup>11</sup> The sensitivity of mammography is higher in the evaluation of breasts consisting mainly of fat tissue (80-98%) as compared to very dense breasts (30-48%). In the present study, 38 cases out of 39 cases were diagnosed having breast cancer.<sup>12</sup> The sensitivity is as high as 97.43%. The false negative was noted in one case out of 39 cases. One reason for false negative results is high breast density. The breast contains both dense tissue and fatty tissue. Fatty tissue appears dark on a mammogram, whereas fibro-glandular tissue appears as a white area. Because fibro-glandular tissue and tumors have similar densities, tumors can be harder to detect in women with denser breasts. Breast ultrasonography is a second-line diagnostic tool, which is useful in the analysis and characterization of specific areas considered suspicious at clinical or mammographic examination.<sup>13</sup> Due to the improved spatial and contrast resolution of modern equipment and as the patient's age has little influence on the diagnostic accuracy of ultrasonography, it is an important tool in the early detection of mammographically occult malignant lesions in women with greater mammographic density.<sup>14</sup> Adjunct (supplemental) screening with ultrasound has the potential to detect breast cancers that may not be visible on mammography. The use of adjunct ultrasonogram is thought to be a safe and inexpensive approach to improve the sensitivity of breast cancer screening along with mammography alone.

The total number of participants in this study was 150, which may not precisely represent the outcome in a larger population. We consider this as a limitation of the present

study. Including more samples in the study will increase the power and credibility this study.

## CONCLUSION

In this study, we have encountered high diagnostic efficacy when using mammogram and ultra-sonogram in the diagnosis of breast cancer in asymptomatic women. We would like to emphasize that the protocol of using mammogram and ultra-sonogram complementing each other should be the standard of care in the screening of breast cancer in women.

## ACKNOWLEDGEMENTS

Authors would like to thank S. S. institute of medical sciences and research centre and Basaveshwara medical college and research centre and Sukshema hospital for the resources and the facility.

*Funding: No funding sources*

*Conflict of interest: None declared*

*Ethical approval: The study was approved by the Institutional Ethics Committee*

## REFERENCES

1. American Cancer Society. Breast Cancer Facts and Figures 2019-2020. Atlanta: American Cancer Society, Inc. 2019. Available at: <https://www.cancer.org/content/dam/cancer-org/research/cancer-facts-and-statistics/breast-cancer-facts-and-figures/breast-cancer-facts-and-figures-2019-2020.pdf>. Accessed on 25 March, 2021.
2. Swanson GM, Lin CS. Survival patterns among younger women with breast cancer: the effects of age, race, stage, and treatment. J Natl Cancer Inst Monogr. 1994;16:69-77.
3. Shoemaker ML, White MC, Wu M, Weir HK, Romieu I. Differences in breast cancer incidence among young women aged 20-49 years by stage and tumor characteristics, age, race, and ethnicity, 2004-2013. Breast Cancer Res Treat. 2018;169(3):595-606.
4. Migowski, A. Early detection of breast cancer and the interpretation of results of survival studies. Cienc. Saude Coletiva. 2015;20:1309.
5. Nelson HD, Tyne K, Naik A, Bougatsos C, Chan BK, Humphrey L; U.S. Preventive Services Task Force. Screening for breast cancer: an update for the U.S. Preventive Services Task Force. Ann Intern Med. 2009;151(10):727-37.
6. Poplack SP, Tosteson AN, Grove MR, Wells WA, Carney PA. Mammography in 53,803 women from the New Hampshire mammography network. Radiology. 2000;217(3):832-40.
7. Sood R, Rositch AF, Shakoor D, Ambinder E, Pool KL, Pollack E et al. Ultrasound for Breast Cancer Detection Globally: A Systematic Review and Meta-Analysis. J Glob Oncol. 2019;5:1-17.

8. Xu Y, Sun Q. Headway in resistance to endocrine therapy in breast cancer. *J Thorac Dis.* 2010;2(3):171-7.
9. Ferlay J, Ervik M, Lam F, Colombet M, Mery L, Piñeros M et al. *Global Cancer Observatory: Cancer Today.* Lyon, France: International Agency for Research on Cancer. 2018.
10. Kolb T.M., Lichy J., Newhouse J.H. Comparison of the performance of screening mammography, physical examination, and breast US and evaluation of factors that influence them: an analysis of 27,825 patient evaluations. *Radiology.* 2002;225:165-75
11. Corsetti V., Ferrari A., Ghirardi M. Role of ultrasonography in detecting mammographically occult breast carcinoma in women with dense breasts. *Radiol Med.* 2006;111:440-8
12. Baker J.A., Soo M.S., Rosen E.L. Artifacts and pitfalls in sonographic imaging of the breast. *AJR Am J Roentgenol.* 2001;176:1261-6.
13. Cha J.H., Moon W.K., Cho N. Differentiation of benign from malignant solid breast masses: conventional US versus spatial compound imaging. *Radiology.* 2005;237:841-6.
14. Health Quality Ontario. *Ultrasound as an Adjunct to Mammography for Breast Cancer Screening: A Health Technology Assessment.* Ont Health Technol Assess Ser. 2016;16(15):1-71.

**Cite this article as:** Byadgi SS, Kumar V, Heggeri P, Patil NV, Yerriswamy P, Jayasimha VL et al. Effectiveness of mammogram and ultra-sonogram in the diagnosis of breast cancer in asymptomatic women at Central Karnataka. *Int Surg J* 2022;9:1548-52.