

## Case Report

# A case report of lumbar hernia

**Rupali Kaur Sachar\*, Hemshankar Rao, Sunita Yadav, Apurva D.**

Department of General Surgery, PIMS Hospital and Medical College, Umarda, Udaipur, Rajasthan, India

**Received:** 11 June 2022

**Revised:** 04 August 2022

**Accepted:** 05 August 2022

**\*Correspondence:**

Rupali Kaur Sachar,

E-mail: [rupalijoy481@yahoo.co.in](mailto:rupalijoy481@yahoo.co.in)

**Copyright:** © the author(s), publisher and licensee Medip Academy. This is an open-access article distributed under the terms of the Creative Commons Attribution Non-Commercial License, which permits unrestricted non-commercial use, distribution, and reproduction in any medium, provided the original work is properly cited.

### ABSTRACT

Lumbar hernia is one of the rare cases that most surgeons are not exposed to. Hence the diagnosis can be easily missed. This leads to delay in the treatment causing increased morbidity. We report a case of lumbar hernia in a middle-aged man. Clinical and MRI findings were correlated to reach the diagnosis. We also highlighted the types, the process of diagnosis and the surgical repair of lumbar hernias.

**Keywords:** Lumbar hernia, Defect, Mesh

## INTRODUCTION

Lumbar hernia is a rare abdominal wall pathology with around 325 cases described in the literature. Hence the diagnosis can be easily missed. This leads to delay in the treatment causing increased morbidity. We reported a case of lumbar hernia in a middle-aged man. It was a case of primary acquired lumbar hernia in the superior lumbar triangle. Clinical and MRI findings were correlated to reach the diagnosis.

We also highlighted the types, the process of diagnosis and the surgical repair of lumbar hernias. We keep the differential diagnosis of the lumbar hernia in mind before diagnosing any lumbar swelling as lipoma.<sup>13</sup>

Recently, a therapeutically aimed classification was proposed analysing the size, location, contents, muscular atrophy, origin, and existence of the previous recurrence.

Surgical repair is the only definitive treatment option through either an open or laparoscopic approach.<sup>8</sup>

## CASE REPORT

A 55 years old male came to consult for swelling in the left lumbar area without traumatic history. A smooth, reducible, and tender mass of 4×3 cm was described since 6 months.

The suspicion of a lumbar hernia was confirmed by lumbar ultrasound and MRI with evidence of a 23 mm abdominal wall defect with the diameter increasing to 33 mm during a Valsalva maneuver. The patient had a primary type A lumbar hernia; therefore, open hernioplasty was performed.

The patient was discharged from the hospital on the fifth postoperative day in optimal clinical condition. His 12-month follow-up examination was uneventful. A lumbar hernia diagnosis can be challenging.

Pre-operative imaging has an important role in assessing the size, location, and hernia contents. The use of a therapeutically aimed classification could be useful for optimal patient management and improvement of surgical outcomes.

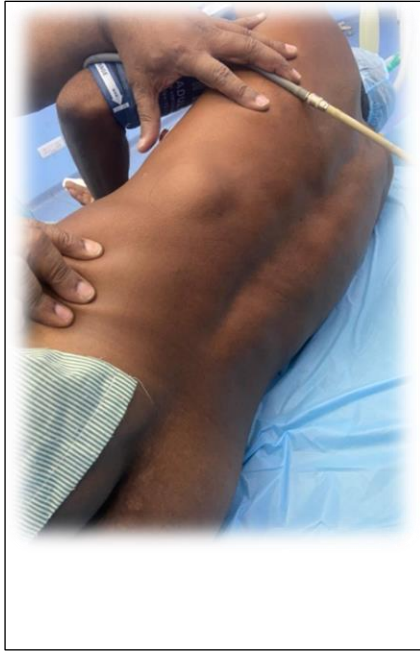

Figure 1: Lumber view.

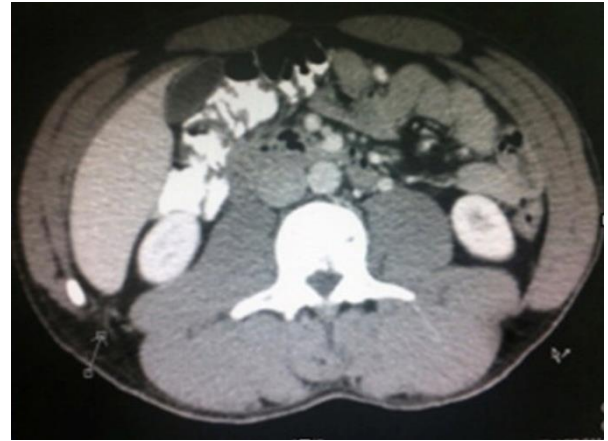

Figure 4: Axial view- CT abdomen the lumbar hernia.

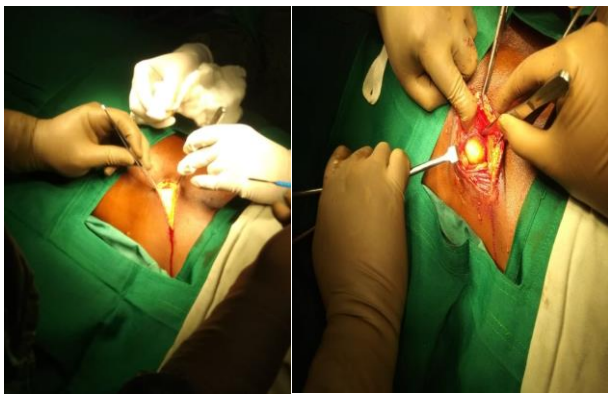


Figure 2: Identification of defect.

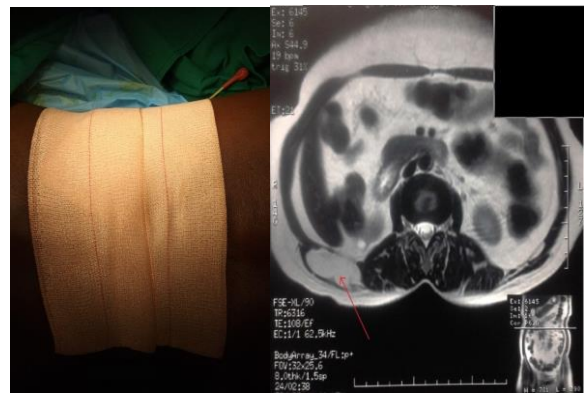


Figure 5: MRI showing hernia content.

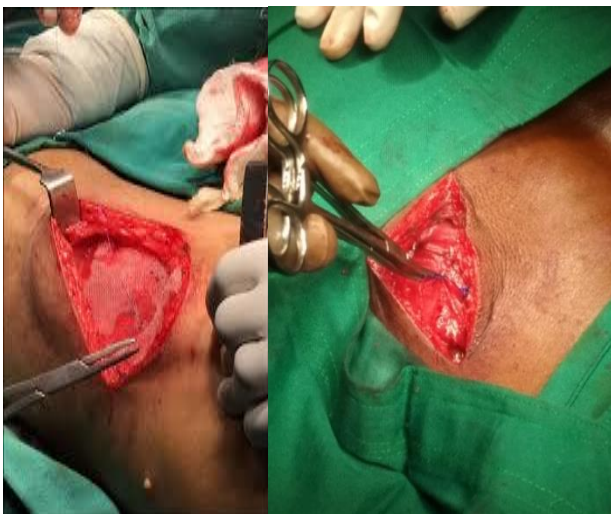

Figure 3: mesh repair after hernia repair hernia posterior.

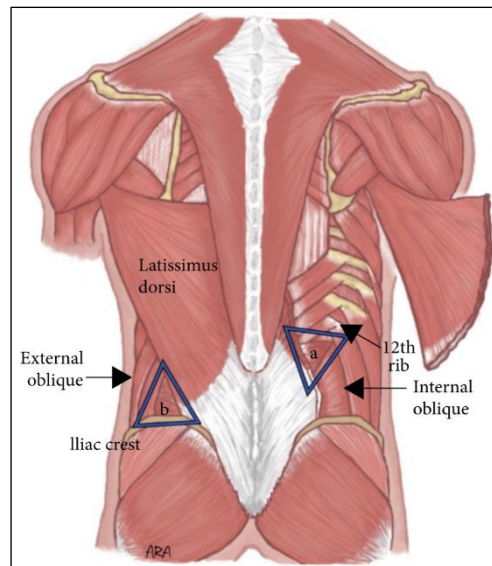


Figure 6: Anatomical borders (a) the superior lumbar triangle bordered by the 12<sup>th</sup> rib, internal oblique, and quadratus (not visualized, deep to the thoracolumbar aponeurosis); and (b) the inferior triangle, bordered by the iliac crest external oblique, and latissimus dorsi.

## Investigations

Routine investigations were normal. MRI showed defect in the lumbar fascia with the protrusion of the abdominal content through the defect. Provisional diagnosis of superior lumbar hernia was given.

## Surgical technique

An oblique incision was given from tip of 12<sup>th</sup> rib to ASIS, in lateral decubitus position and then lumbosacral fascia incised, muscle fibres of latissimusdorsi are split, after putting fat inside the peritoneum, it is closed with interrupted sutures, internal oblique and quadratuslumborumopposed, mesh is placed lateral to the border and latissimusdorsi sutured with prolene, subcutaneous suturing done with vicryl and skin closed with ethylon.

## DISCUSSION

Lumbar hernia is a form of flank hernia. Flank hernia is defined as any hernia from the anterior axillary line to spine and from costal margin to ischial tuberosity. It is of two types: superior lumbar hernia and inferior lumbar hernia according to the anatomical location of the defect, that is, either through the superior or the inferior lumbar triangle. The superior lumbar triangle of Grynfeltt-lesshaft is bounded anteriorly by the latissimus dorsi muscle, posteriorly by the quadrates lumborum and erector spinae muscles and superiorly by the 12th rib and serratus posterior inferior muscle.

The inferior lumbar triangle of petit is bounded anteriorly by the external oblique muscle, posteriorly by the latissimus dorsi muscle and inferiorly by the iliac crest.<sup>7</sup> A lumbar hernia is difficult to diagnose as the patient is either asymptomatic or presents with non-specific symptoms. Clinical feature of a lumbar hernia is usually dull aching pain over an increasing size of lumbar mass. The lumbar mass becomes more prominent on straining and coughing and reduces in size in prone position. Expansile cough impulse is positive in a minority of patients (as found in our case).<sup>1,3</sup> Diagnosis of these hernias may be missed as these are very rare cases.<sup>10</sup>

Lumbar hernias have to be differentiated from lipomas, haematomas, fibromas, abscesses and kidney tumours. Lipomas are usually soft mobile masses which are not attached to the muscle layer. Fibromas are firm masses attached to fascia or muscle. Haematomas present with a history of trauma and local ecchymosis. Abscesses present with pain, oedema, cellulitis, fever and leucocytosis. Kidney tumours are non-painful, firm to hard in consistency, dull on percussion and may be associated with haematuria. None of these differential diagnoses increase in size on straining or decrease in size in prone position. Expansile cough impulse is absent in all of them unlike a lumbar hernia.

A lumbar hernia though rarely may also become incarcerated and strangulated. The most important differential diagnosis of strangulated lumbar hernia is haematoma found in the flanks after trauma. In a case of strangulated lumbar hernia there is bowel obstruction which is not found in haematomas.<sup>1</sup> CT scan or MRI may be performed to confirm the diagnosis.<sup>4</sup> Both can show the defect in the musculofascial layer, the content of the hernia and help us to plan the repair. They can also rule out the other differential diagnoses of lumbar hernia. These hernias should not be managed conservatively without surgery for two reasons. First, around 25% of these hernias are prone to incarceration and 10% to strangulation which may present with features of acute abdomen and need emergency surgery.<sup>5</sup> Second, these hernias tend to increase in size with time. Surgical repair of a large lumbar hernia is difficult. Hence surgical repair without delay is the treatment of choice.

## Clinical message

Lumbar hernia can create diagnostic dilemma with lipoma being the most common differential diagnosis. Treatment should not be delayed as the lumbar hernia becomes more difficult to repair as it increases in size. As much as one of four cases of lumbar hernia is prone to incarcerate and present as acute abdomen. Hence emergency surgeons should keep strangulated lumbar hernia in differential diagnosis of any acute abdomen and a lumbar mass.<sup>9</sup> Diagnosis of a simple lumbar hernia is mostly clinical which can be confirmed with either a CT scan or MRI which shows a defect in the fascia. Treatment is surgical with the use of a large mesh in the pre-peritoneal space either through the open or laparoscopic approach.

## CONCLUSION

Lumbar hernias are rare. A good history and general physical examination can rule out most of the differential diagnoses. CT scan and MRI should be done as a routine prior to planning surgical approach unless the patient presents with life threatening complications. Even though the data available to us regarding the management of lumbar hernias are limited, current literature suggests laparoscopic approach is the best method of treatment. Open surgery should be reserved for patients who have very large defects or after failed laparoscopic approach. The operative technique should be planned based on the size of the hernia, location, contents, etiology, chances of recurrence and the availability of facilities and expertise in the hospital.

*Funding: No funding sources*

*Conflict of interest: None declared*

*Ethical approval: Not required*

## REFERENCES

1. Burt BM, Afifi HY, Wantz GE, Barie PS. Traumatic lumbar hernia: report of cases and comprehensive

- review of the literature. *J Trauma.* 2004;57(6):1361-70.
2. Bathla L, Davies E, Fitzgibbons RJ, Cemaj S. Timing of traumatic lumbar hernia repair: is delayed repair safe? Report of two cases and review of the literature. *Hernia.* 2011;15(2):205-9.
  3. Iannitti DA, Biffl WL. Laparoscopic repair of traumatic lumbar hernia. *Hernia.* 2007;11(6):537-40.
  4. Shanker B, Chernyavsky VC, Johnson K, Honeymana JN, Davidov T. Repair of a traumatic lumbar hernia with biosynthetic mesh: a novel approach and review of the literature. *J Curr Surg* 2012;2:105-9.
  5. Ipek T, Eyuboglu E, Aydingoz O. Laparoscopic management of inferior lumbar hernia (Petit triangle hernia). *Hernia.* 2005;9(2):184-7.
  6. Arca MJ, Heniford BT, Pokorny R, Wilson MA, Mayes J, Gagner M. Laparoscopic repair of lumbar hernias. *J Am Coll Surg.* 1998;187(2):147-52.
  7. Parihar S, Bali G, Sharma S, Koul N. Congenital lumbar hernia. *JK Sci.* 2008;10:144-5.
  8. Mingolla GP, Amelio G. Lumbar hernia misdiagnosed as a subcutaneous lipoma: a case report. *J Med Case Rep.* 2009;3:9322.
  9. Mismar A, Al-Ardah M, Albsoul N, Younes N. Underlay mesh repair for spontaneous lumbar hernia. *Int J Surg Case Rep.* 2013;4(6):534-6.
  10. Fei Y, Li L. Comparison of two repairing procedures for abdominal wall reconstruction in patients with flank hernia. *Zhongguo Xiu Fu Chong Jian Wai Ke Za Zhi.* 2010;24(12):1506-9.
  11. Egea A, Alcaraz AC, Cuervo MC. Surgical options in lumbar hernia: laparoscopic versus open repair. A long-term prospective study. *Surg Innov.* 2013;20(4):331-44.
  12. Lim MS, Lee HW, Yu CH, Yang DH. Laparoscopic total extraperitoneal repair of lumbar hernia. *J Korean Surg Soc.* 2011;81(4):287-90.
  13. Yavuz N, Ersoy YE, Demirkesen O, Tortum OB, Erguney S. Laparoscopic incisional lumbar hernia repair. *Hernia.* 2009;13(3):281-6.
  14. Suarez S, Hernandez JD. Laparoscopic repair of a lumbar hernia: report of a case and extensive review of the literature. *Surg Endosc.* 2013;27(9):3421-9.

**Cite this article as:** Sachar RK, Rao H, Yadav S, Apurva D. A case report of lumbar hernia. *Int Surg J* 2022;9:1643-6.