

## Case Report

# Initial experience in a novel robotic system: Hugo™ robotic assistant surgery system for robotic inguinal hernia repair

Premkumar Balachandran<sup>1</sup>, Subbiah Tirunelveli Sivagnanam<sup>1\*</sup>, Dakshay Chordia<sup>2</sup>

<sup>1</sup>Institutes of Hernia Surgery and Abdominal Wall Reconstruction, Apollo Hospitals, Chennai, Tamil Nadu, India

<sup>2</sup>Department of General Surgery, Apollo Hospitals, Greaves Road, Chennai, Tamil Nadu, India

**Received:** 17 May 2022

**Accepted:** 09 June 2022

### \*Correspondence:

Dr. Subbiah Tirunelveli Sivagnanam,  
E-mail: [tssismyname@gmail.com](mailto:tssismyname@gmail.com)

**Copyright:** © the author(s), publisher and licensee Medip Academy. This is an open-access article distributed under the terms of the Creative Commons Attribution Non-Commercial License, which permits unrestricted non-commercial use, distribution, and reproduction in any medium, provided the original work is properly cited.

## ABSTRACT

The Hugo Robotic Assistant Surgical (RAS)<sup>TM</sup> system is a modular portable robotic surgical assistant pioneered by Medtronic Limited currently being used as a research device. It was used in performing a trans-abdominal pre-peritoneal repair for bilateral inguinal hernia at Institutes of Hernia Surgery and Abdominal Wall Reconstruction, Apollo Hospitals, Chennai, India. This reports our initial experience in using a novel robotic surgical assistant system in performing robotic inguinal hernia repair.

**Keywords:** Robotic surgery, Robotic hernia surgery, Minimal access surgery, Hernia repair, Pre-peritoneal repair

## INTRODUCTION

The advent of widespread utilization of robotic surgical assistant systems is heralded by the announcements from various manufacturers about novel devices under research for human use. The robot's ability to eliminate surgeon tremor and fatigue in addition to providing improved vision, dexterity and stability has been demonstrated beyond doubt by contemporary systems in use at present. Multiple studies have proved that robotically assisted hernia surgery is a secure and implementable option with reduction in operative time on crossing the initial learning curve of the procedure.<sup>1</sup>

The aim of the study was to evaluate the Hugo Robotic Assistant Surgical (RAS)<sup>TM</sup> system currently being used as a research device at our institution to assess its propensity in performing robotic hernia surgery.

## CASE REPORT

56 year old male presented with bilateral inguinal hernia. After necessary pre-operative assessment and informed consent for robotic hernia repair using Hugo RAS<sup>TM</sup>,

patient was planned for bilateral robotic inguinal hernia repair (RIHR).

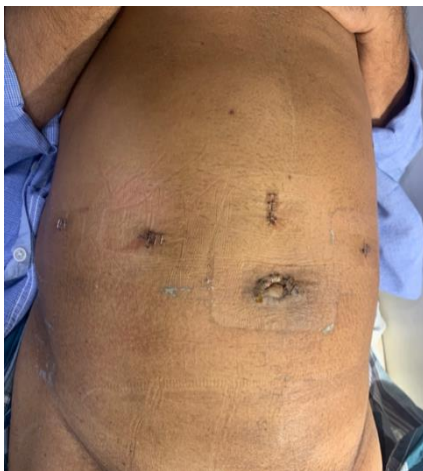Under general anesthesia with the patient in supine position, pneumoperitoneum was established using a Veress needle and supraumbilical optic 11 mm port was inserted and two lateral 8 mm working ports inserted under vision- 8 cm on either side of the optical port (Figure 1). An additional 10 mm assistant port was placed in the right flank to facilitate mesh deployment, suction, etc. The patient was placed in 30° trendelenberg position with the legs split apart (Figure 2).

The three arms of the Hugo<sup>TM</sup> RAS were placed with one between the legs and one on either side of the patient as illustrated in Figure 2 and docked. Exploration of the abdominal cavity confirmed bilateral inguinal hernia. The 4<sup>th</sup> arm was not utilised as we used a three-port technique for our bilateral rTAPP.

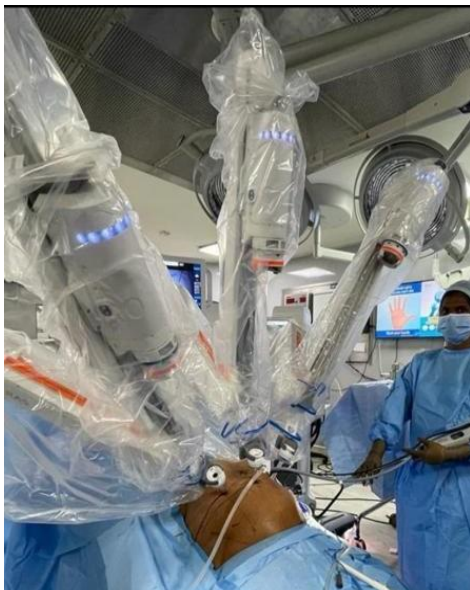The peritoneum was opened and the pre-peritoneal space entered from lateral to medial and flap was dissected out with a fenestrated grasper in the left hand and monopolar hook in the right hand.

Dissection was done from the ASIS to the medial umbilical fold bilaterally and pubic bone was visualized. The space of Bogros and Retzius were visualized and Coopers ligament was exposed. The sac was dissected from the cord structures and vas deferens was visualized (Figure 3). With reduction of the hernia and completion of dissection, a 3D XL BARD™ polypropylene mesh was placed and fixed to the cooper's ligament using a tackler (Figure 4).

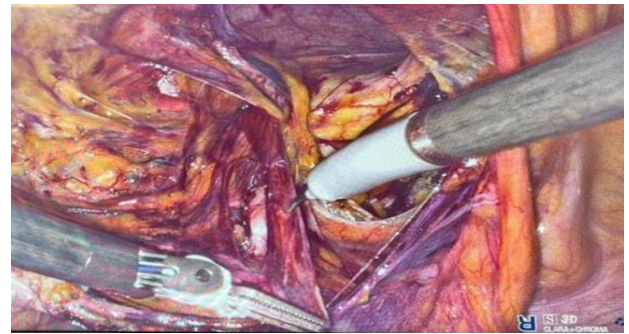The peritoneum was closed with a running of 2' 0 barbed suture from lateral to medial avoiding any contact of the mesh with the bowel loops. The trocars were removed under vision and patient was extubated. Post-operative period was uneventful and patient was discharged on the first post-operative day. Patient was followed up to a period of 3 months and reported no recurrence or any other adverse event.



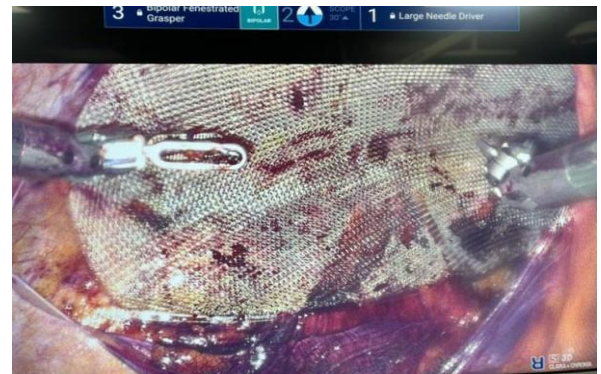
**Figure 1: Port positions for bilateral rTAPP.**



**Figure 2: Hugo™ RAS docking with patient in trendelenberg and positioned with legs split apart.**



**Figure 3: Dissection of cord structures using the wristed instruments.**



**Figure 4: Mesh placement and fixation of polypropylene mesh.**

## DISCUSSION

Since the conception of laparoscopic inguinal hernia repair by Ger et al and colleagues in 1990, many advancements have been made in the field of minimal access surgery over the last three decades.<sup>2</sup> Multiple studies have proved that minimal access repair of inguinal hernias provided better outcomes compared to open inguinal hernia repair.<sup>3</sup>

Over the decade, access to training, equipment and instrumentation has improved by bounds, but widespread adoption of laparoscopic inguinal hernia repair has yet to become mainstream by general surgeons worldwide despite swift adoption of laparoscopic approach for other procedures.<sup>4</sup>

With increasing adoption of robotic surgical assistants, data has emerged that robotic procedures might be easier to learn and hence the adoption of minimal access inguinal hernia repair might be easier to implement compared to conventional laparoscopy.<sup>5</sup>

On comparison with the Da vinci surgical system by intuitive surgical, the Hugo RAS™ has a few unique features which allow for easier maneuverability. The independent nature of the robotic arms allowed for usage individually in three or four arm configurations freeing up

additional space in the theatre (Figure 5), with the ability to fold and store the unused arm individually.

With 6 joints and 7 degrees of freedom and option of setting tilt angles of the arms, allows for difficult anatomical targets to be reached like in pelvis and inguinal regions making this a unique system highly suitable for robotic inguinal hernia repair.<sup>7</sup>

The Karl Storz™ 3D HD endoscope with 0° and 30° endoscopes, provided an unhindered view of the anatomy. The modular nature of the processing unit is designed to be compatible with conventional laparoscopic systems, allowing us with the freedom of converting to laparoscopy if the need arises, without removal of the endoscope. Multiple filters in the Karl Storz™ system such as the CLARA filter which automatically identifies and brightens dark areas of an image, and the CHROMA filter which enhances the video image's red color contrast in tissue to enable surgeons to better visualize blood vessels which can be utilized in real time.<sup>8</sup>

The wristed instruments with seven degrees of freedom and motion scaling allowed for the fine dissection adjacent to major vasculature, placement of mesh and closure of the peritoneum to be done in an exceedingly effortless manner.

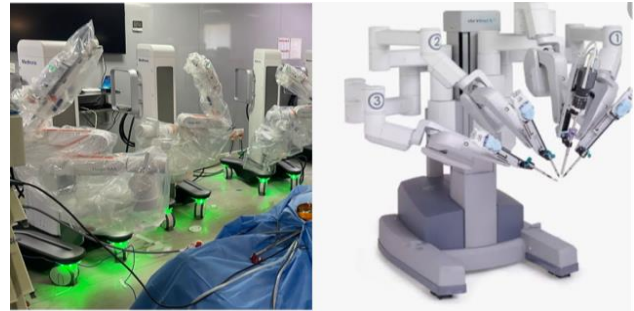These essential steps which have a steep learning curve in conventional laparoscopy can be overcome by usage of robotic surgical assistants, thereby allowing for widespread implementation of minimal access hernia repair.

The trigger like grip of the instrument console offered better ergonomics over the traditional pincer like grip (Figure 6). An inbuilt clutch in the handgrip allows for locking and unlocking individual arms.

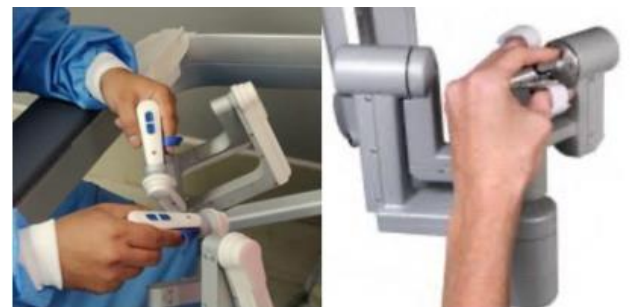Hemostasis was secured using the Valleylab F10 energy platform which has a comprehensive suite of electrosurgical tools, including advanced vessel sealing devices like LigaSure™ ensuring safe surgery.

The surgeon console is an open console design with an EIZO 3D display and head tracking system (Figure 7). This allowed for seamless intraoperative communication with the assisting operative team throughout the duration of surgery.

The operating surgeon using 3D eyewear, was able to maintain an ergonomic, erect posture without the need to bend into the console like in the closed console design which though immersive, at times can feel restrictive. The open console also allowed for observers to visualize the nuances of the procedure without the need for a separate surgeon console. The open console design also reduces adaptation time as the operating surgeon's vision is panoramic and unrestricted with increased situational awareness.



**Figure 5: Modular nature of the HUGO RAS™ with individual arm carts versus the Da Vinci surgical system with arms arising from a single platform.**



**Figure 6: The trigger like grip of the operating rig offers better ergonomics in compared to the traditional pincer like handles offered.**



**Figure 7: The Hugo™ RAS open design surgeon console versus the immersive console in the Da Vinci robotic assistant.**

## CONCLUSION

The Hugo™ RAS system proves to be adept in delivering safe and optimal surgical care to the community and will prove to be a useful aid in the armamentarium for performing hernia surgery using robotic surgical assistants. Further research with multi-center trials will aid in further defining the role of this technology for robotic hernia surgery.

*Funding: No funding sources*

*Conflict of interest: None declared*

*Ethical approval: Not required*



## REFERENCES

1. Dominguez JE, Ramos MG, Seetharamaiah R, Donkor C, Rabaza J, Gonzalez A. Feasibility of robotic inguinal hernia repair, a single-institution experience. *Surg Endosc.* 2016;30(9):4042-8.
2. Ger R, Monroe K, Duvivier R, Mishrick A. Management of indirect inguinal hernias by laparoscopic closure of the neck of the sac. *Am J Surg.* 1990;159(4):370-3.
3. Cavazzola LT, Rosen MJ. Laparoscopic versus open inguinal hernia repair. *Surg Clin North Am.* 2013;93(5):1269-79.
4. Trevisonno M, Kaneva P, Watanabe Y, Fried GM, Feldman LS, Lebedeva E, et al. A survey of general surgeons regarding laparoscopic inguinal hernia repair: practice patterns, barriers, and educational needs. *Hernia.* 2015;19(5):719-24.
5. Kudsi OY, McCarty JC, Paluvoi N, Mabardy AS. Transition from Laparoscopic Totally Extraperitoneal Inguinal Hernia Repair to Robotic Transabdominal Preperitoneal Inguinal Hernia Repair: A Retrospective Review of a Single Surgeon's Experience. *World J Surg.* 2017;41(9):2251-7.
6. Intuitive Surgical Company. Da Vinci Robot Patency, 2019. Available at: <https://www.intuitive.com/enus/aboutus/company/legal/patent-notice>. Accessed on 10 May 2022.
7. Ragavan N, Bharathkumar S, Chirravur P, Sankaran S, Mottrie A. Evaluation of Hugo RAS System in Major Urologic Surgery: Our Initial Experience. *J Endourol.* 2022.
8. Medtronic. Products and system, 2022. Available at: <https://www.medtronic.com/covidien/en-us/robotic-assisted-surgery/hugo-ras-system.html>. Accessed on 10 May 2022.

**Cite this article as:** Balachandran P, Sivagnanam ST, Chordia D. Initial experience in a novel robotic system: Hugo™ robotic assistant surgery system for robotic inguinal hernia repair. *Int Surg J* 2022;9:1358-61.