

Case Report

Transient regression and fluctuation of bilateral adrenal masses: a rare presentation of primary adrenal lymphoma

Aminnur H. Maliki^{1*}, Anita Baghawi²

¹Department of Surgery, Sarawak General Hospital, Jalan Hospital, 93586 Kuching, Sarawak, Malaysia

²Department of Breast And Endocrine Surgery, Hospital Putrajaya, Jalan P9, Presint 7, 62250 Putrajaya, Wilayah Persekutuan Putrajaya, Malaysia

Received: 05 May 2022

Accepted: 21 May 2022

*Correspondence:

Dr. Aminnur H. Maliki,

E-mail: aminnur.hm@gmail.com

Copyright: © the author(s), publisher and licensee Medip Academy. This is an open-access article distributed under the terms of the Creative Commons Attribution Non-Commercial License, which permits unrestricted non-commercial use, distribution, and reproduction in any medium, provided the original work is properly cited.

ABSTRACT

Primary adrenal lymphoma is a rare form of extra-nodal lymphoma which scarcely reported in the literature reviews. We describe such a case who presented with fluctuation in the sizes of bilateral adrenal masses. A 61-year-old lady who presented with a history of right flank discomfort with no other associated symptoms. Initial imaging showed bilateral adrenal masses. She was evaluated and excluded for possibilities of pheochromocytoma, cortical carcinoma and secondary tumour deposits. Interestingly, a consecutive of contrast-enhanced computed tomography images showed transient regression and fluctuation of bilateral adrenal masses, which making the diagnosis became more challenging. A confirmatory histological diagnosis was obtained via imaging-guided biopsy which revealed diffuse large B cell lymphoma. Unfortunately, the patient was reluctant to receive chemotherapy and eventually lost to follow-up. Diagnosing a primary adrenal lymphoma can be challenging due to its rarity and requires high index of suspicion for timely diagnosis and treatment.

Keywords: Primary adrenal lymphoma, Adrenal mass, Extra-nodal, DLBCL

INTRODUCTION

Although lymphoma can emerge anywhere in the body, the involvement of adrenal gland in the primary adrenal lymphoma (PAL) is very rare with less than 200 cases described in the literature reviews.¹ PAL tends to affect bilateral adrenal glands (70%) and the most encountered subtype is a diffuse large B-cell lymphoma which seen in up to 78% of the cases.² Furthermore, PAL is typically hormonally inactive with non-specific imaging characteristics, making the diagnosis more challenging. We had the opportunity to report an unusual case of PAL that demonstrated the dynamic fluctuation in the sizes of bilateral adrenal masses captured through serial abdominal contrast-enhanced computed tomography scans. The confirmatory histological diagnosis was established by imaging-guided biopsy.

CASE REPORT

Our patient was a 61-year-old Chinese lady who had history of right second to fourth metatarsal closed fractures due to slip and fall injury one week before presenting with a complaint of persistent right flank discomfort without any other associated symptoms.

She sought consultation at a private hospital and an abdominal contrast-enhanced computed tomography (CECT) scan revealed a large right adrenal mass with a small contralateral adrenal nodule. She was referred to our centre for further evaluation.

Upon review in our clinic, she was hemodynamically stable with no palpable abdominal mass or lymphadenopathy on physical examination.

The initial basic laboratory tests including complete blood counts, serum electrolytes, renal and liver function tests were within normal ranges, except for elevated serum lactate dehydrogenase, 558 U/L (normal value less than 247 U/L). Otherwise, the rest of infective screening, serum tumour markers and hormonal studies were unremarkable.

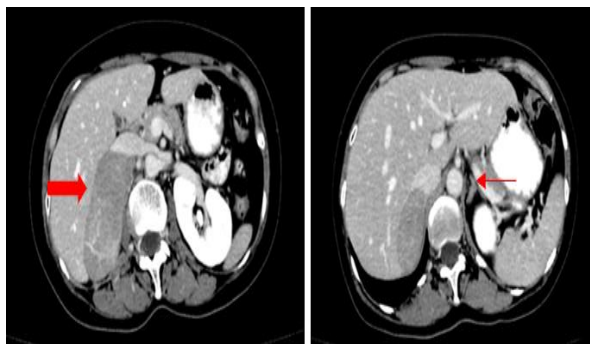


Figure 1: Large right adrenal mass (thick arrow) and small left adrenal nodule (thin arrow).

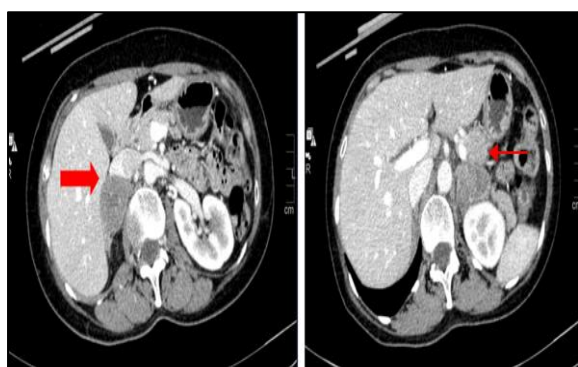


Figure 2: CECT abdomen after 2 months, showing regression of right adrenal mass (thick arrow) and enlarging left adrenal mass (thin arrow).

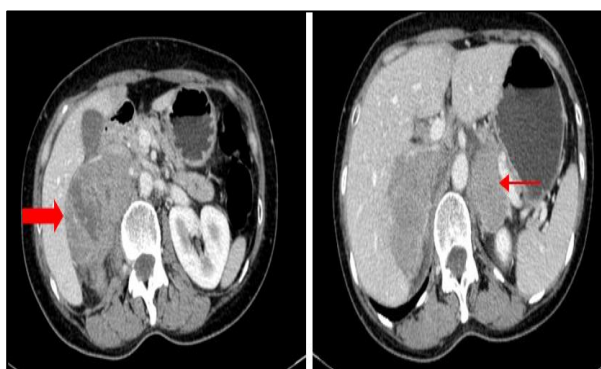


Figure 3: CECT abdomen after 5 months, showing progression of bilateral right adrenal mass (thick arrow) and left adrenal mass (thin arrow).

The abdominal CECT scan showed a large well-defined heterogenous isodense right adrenal mass measuring $8 \times 5.7 \times 7.3$ cm with poor enhancement post contrast

injection (Figure 1). There was another small enhancing nodule measuring 1.0×1.2 cm noted at the contralateral adrenal gland. In view of symptomatic large non-functioning well-defined right adrenal mass, the patient was planned for an elective open right adrenalectomy after her right metatarsal fractures healed and the foot cast has been removed.

Approximately 2 months later before the elective operation, out of curiosity, she went to her previous private hospital to perform an ultrasonography of abdomen and to her surprise, revealed that the right adrenal mass became significantly smaller. We confirmed the finding with a repeat of abdominal CECT scan and found that the right adrenal mass was smaller than previously, measuring $3.4 \times 3.2 \times 3.4$ cm (Figure 2). Paradoxically, the contralateral adrenal gland became larger measuring at $2.9 \times 3.7 \times 3.8$ cm. The patient denied taking any medications or supplements since the last review. Due to these new findings and no further discomfort, she opted for conservative management and follow-up.

Unfortunately, 3 months afterward, she developed recurrent severe right flank pain and a repeated abdominal CECT scan showed progression of both right and left adrenal masses, measuring $8.5 \times 5.9 \times 7.6$ cm and $5.0 \times 3.2 \times 3.8$ cm respectively (Figure 3). The patient accepted endoscopic ultrasonography-guided fine needle biopsy of left adrenal mass. The histopathological examination showed atypical lymphoid cells in diffuse pattern which are intermediate to large, exhibit round to cleaved nuclei with single to multiple visible nucleoli and moderate amount cytoplasm. These cells expressed positivity with LCA, CD20, BCL6, MUM1 and BCL2. They were negative with PanCK, synaptophysin, chromogranin, CD3 and CD10. Proliferative index of Ki67 was 80%. She was finally diagnosed with high grade B cell lymphoma, favour diffuse large B-cell lymphoma, activated B-cell subtype. The synacthen test was done and excluded adrenal insufficiency. She was then referred to Haematologist for definitive treatment, however she refused chemotherapy and defaulted the follow-up.

DISCUSSION

Large adrenal tumours (>5 cm) are increasingly reported with the development of imaging technology and widespread availability of abdominal contrast-enhanced computed tomography (CECT) scans. The most common reported large malignant adrenal tumours were metastases (17.13%), followed by cortical carcinoma (8.76%), whereas lymphoma only accounted for 1.20% of all large adrenal tumours.³

Lymphoma involving adrenal glands can be either primary or secondary. Primary adrenal lymphoma (PAL) is extremely rare, accounted for less than 0.2% of non-Hodgkin's lymphoma and about 3% of extranodal

lymphomas.⁴ Due to the rarity of this hormonally inactive entity and its inconsistent imaging characteristics, the diagnosis usually confirmed by imaging-guided biopsy, surgical excision or on autopsy of one or both adrenal glands. In addition to histological confirmation, there should not be any previous history of lymphoma elsewhere to ascertain the diagnosis of PAL and when the lymph nodes or other organs are affected, adrenal lesions must be unequivocally dominant.²

The most frequent histology for PAL was a diffuse large B cell lymphoma (DLBCL), followed by peripheral T cell lymphoma. DLBCL can be further divided into germinal center B cell (GCB) or non-germinal center B cell (non-GCB) subtype using three immunostainings, namely CD10, MUM1 and BCL6. Generally, the GCB subtype tends to have a better outcome than the non-GCB subtype.⁵

PAL tends to occur in elderly man with a mean age at diagnosis of 62 years and male-to-female ratio of 1.8:1.2. Bilaterality was commonly observed in more than 70% of reported cases.⁶ Typically, patients with PAL will come with discomfort or pain due to pressure effect exerted by the large tumor. Additionally, tumour-related symptoms such as B-symptoms (fever, night sweats, weight loss) and fatigue were also frequently reported at presentation. If more than 90% of bilateral adrenal glands destroyed by tumour infiltration, patients may manifest with clinical symptoms of adrenal insufficiency such as nausea, vomiting, postural hypotension and/or skin hyperpigmentation.⁷

In our series, the large right adrenal mass was discovered from abdominal CECT scan after the patient presented with a short history of right flank discomfort. Otherwise, there was no other significant associated clinical signs or symptoms to assist in narrowing the clinical diagnosis. As routine for any other adrenal lesions or masses, functional studies were performed to exclude pheochromocytoma, cortisol or aldosterone-secreting tumour, and even cortical carcinoma. In addition, lists of common tumour markers were tested to rule out secondary adrenal involvement. All these tests were unremarkable except for the elevated lactate dehydrogenase. At this point, the diagnosis of adrenal lymphoma was not entertained since it is extremely rare and there was no lymphadenopathy.

From the previous studies reviewing on the CECT images, there were no specific characteristics of adrenal lymphoma identified, which led to heterogeneity in the radiological diagnosis.

PAL can appear as either homogenous or heterogenous mass with variable density (isodense or slightly hypodense) and mild to moderate enhancement post injection of contrast media.⁸ All these characteristics were almost similarly observed in our series.

Interestingly, the peculiar remark in this case was the fluctuation of bilateral adrenal masses observed over period of times. The initial CT scan examination showed diffusely enlarged right adrenal mass with concomitant small contralateral adrenal nodule. However, 2 months later, the right adrenal mass shrunk into almost half of the initial size, whereas the left adrenal gland tripled its size, before the progressive enlargement of both adrenal masses noted on subsequent CECT scan. This triggered us to investigate for further possibility of fungal infections, as few published case series reported shrinkage of adrenal mass, however only occurred after antifungal treatment administered.⁹

The reason for these fluctuations were uncertain as majority of the cases either progressively enlarged due to diffuse tumor infiltration¹⁰ and overexpression of Ki-67 which reflects the tumour cells proliferation or regressed after responding to chemotherapy treatment.^{7,11} We postulated that the possibility of corticosteroid usage during the initial screening for cortisol-secreting tumour attributed to the transient regression of the right adrenal mass, as reported in one study by Zaman et al.¹² Ironically, we do not have the explanation for the progressive enlargement of the contralateral adrenal gland that occurred concurrently.

Due to the equivocality of the clinical diagnosis, imaging-guided biopsy was performed to establish the definitive histological diagnosis of DLBCL. Further immunostainings expressed BCL6+, MUM1+ and CD10- which was corresponded with non-GCB subtype, as revised by Choi et al.¹³ PAL is usually aggressive and has a poor survival rate as reported by Rashidi et al.² In his systemic review involving 149 cases of PAL, the survival rate for 3-, 6-, and 12-month were only 67%, 46% and 20% respectively. Adverse prognostic factors include older age, large tumour size, bilaterality, elevated LDH level, non-GCB subtype and adrenal insufficiency at presentation.² Our patient had almost all these unfavourable prognostics factors except for adrenal insufficiency.

The widely adopted and recognized treatment strategy for PAL is chemotherapy with R-CHOP (rituximab, cyclophosphamide, doxorubicin, vincristine and prednisone). R-CHOP regimen has a greater complete response (76% versus 56%, $p < 0.005$), better 2-year overall survival (57% vs 38%, $P < 0.001$) and higher progression-free survival (70% versus 57%, $p = 0.007$) compared to the traditional CHOP regimen.¹⁴ Adrenalectomy prior to chemotherapy was ineffective and added no survival benefit.¹⁵ Regrettably, although the patient in our series escaped from the surgery, she refused chemotherapy and defaulted the subsequent follow-up.

CONCLUSION

In summary, this study demonstrates that it can be a real challenge and puzzle to diagnose PAL due to its rarity

and non-specific imaging characteristics. A high index of suspicion requires for its timely diagnosis as the disease is usually progressive and aggressive with unfavourable outcome. It is important to note that the peculiarity of transient regression and fluctuation of adrenal mass in this series could provide a clue in making the timely diagnosis in the future.

ACKNOWLEDGEMENTS

We would like to extend our appreciation to all the staffs of Hospital Putrajaya who were directly or indirectly involved in managing this case. We also would like to thank the Director General of Health for his permission to publish this case report.

Funding: No funding sources

Conflict of interest: None declared

Ethical approval: Not required

REFERENCES

- Kerkhofs TM, Roumen RM, Demeyere TB. Adrenal tumors with unexpected outcome: a review of the literature. *Int J Endocrinol*. 2015;710514.
- Rashidi A, Fisher SI. Primary adrenal lymphoma: a systematic review. *Ann Hematol* 2013; 92:1583-93.
- Zhang Z, Wang L, Chen J, et al. Clinical analysis of adrenal lesions larger than 5 cm in diameter (an analysis of 251 cases). *World J Surg Onc*. 2019;17:220.
- Freeman C, Berg JW, Cutler SJ. Occurrence and prognosis of extranodal lymphomas. *Cancer*. 1972;29:252-60.
- Mozos A, Ye H, Chuang WY. Most primary adrenal lymphoma are diffuse large B-cell lymphomas with non-germinal center B-cell phenotype, BCL6 gene rearrangement and poor prognosis. *Mod Pathol*. 2009;22:1210-1270.
- Laurent C, Casasnovas O, Martin L. Adrenal lymphoma: presentation, management and prognosis. *QJM* 2017;110:103-9.
- Yang L, Zhang M, Zhao S. Correlations between MDCT features and clinicopathological findings of primary adrenal lymphoma. *Eur J Radiol*. 2019;113:110-5.
- Zhou L, Peng W, Wang C. Primary adrenal lymphoma: radiological; pathological, clinical correlation. *Eur J Radiol*. 2012;81:401-5.
- Muraoka Y, Iwama S, Arima H. Normalization of Bilateral Adrenal Gland Enlargement after Treatment for Cryptococcosis. *Case Rep Endocrinol*. 2017;2017:1543149.
- Bouchikhi AA, Tazi MF, Amiroune D. Primary Bilateral Non- Hodgkin's Lymphoma of the Adrenal Gland: a case report. *Case Rep Urol*. 2012;2012:325675.
- Singh A, Udupa K, Madhyastha SP. Bilateral primary adrenal lymphoma successfully treated with non-CHOP chemotherapy regimen. *BMJ Case Rep*. 2018;2018:bcr-2017-223078.
- Zaman S, Boharoon H, Khalid N, Marks S. The vanishing adrenal glands: A transient regression of adrenal lymphoma after a single dose of 1 mg dexamethasone. *AACE Clinical Case Reports*. 2020.
- Choi WW, Weisenburger DD, Greiner TC, Piris MA, Banham AH, Delabie J et al. A new immunostain algorithm classifies diffuse large B-cell lymphoma into molecular subtypes with high accuracy. *Clin Cancer Res*. 2009;15:5494-502.
- Coiffier B, Lepage E, Brière J. CHOP chemotherapy plus rituximab compared with chop alone in elderly patients with diffuse large-B-cell lymphoma. *N Engl J Med*. 2002;346:235-42.
- Kim YR, Kim JS, Min YH, Hyunyon D, Shin HJ, Mun YC et al. Prognostic factors in primary diffuse large B-cell lymphoma of adrenal gland treated with rituximab-CHOP chemotherapy from the Consortium for Improving Survival of Lymphoma (CISL). *J Hematol Oncol*. 2012;5:49.

Cite this article as: Maliki AH, Baghawi A. Transient regression and fluctuation of bilateral adrenal masses: a rare presentation of primary adrenal lymphoma. *Int Surg J* 2022;9:1246-9.