

Original Research Article

A comparative prospective study of laparoscopic guided needle assisted hernial sac ligation versus open herniotomy surgery in congenital inguinal hernia management

Dinesh Prasad, Yogesh Satani, Girish Bochiya*

Department of General Surgery, SMIMER, Surat, Gujarat, India

Received: 10 October 2021

Revised: 30 November 2021

Accepted: 01 December 2021

*Correspondence:

Dr. Girish Bochiya,

E-mail: girishbochiya1991@gmail.com

Copyright: © the author(s), publisher and licensee Medip Academy. This is an open-access article distributed under the terms of the Creative Commons Attribution Non-Commercial License, which permits unrestricted non-commercial use, distribution, and reproduction in any medium, provided the original work is properly cited.

ABSTRACT

Background: To evaluate if significant difference exists in surgical outcome following laparoscopic guided needle assisted congenital hernial sac ligation versus conventional open Herniotomy as later is treatment of congenital hernia and laparoscopy guided emerged as newer alternative. Objective was to know whether a significant difference exists in surgical outcomes following laparoscopic guided needle assisted congenital hernial sac ligation and conventional herniotomy in terms of mean operative time, post operative pain, recurrence, local complication, cosmetic results.

Methods: Patients were randomized on basis of odd and even registrations for surgery in our institute. Patients who undergone laparoscopic guided needle assisted congenital hernial sac ligation or who undergone conventional open herniotomy for congenital hernia between November 2018 to April 2020 (50 in each arm) were followed for 1, 3, 6 and 12 months to evaluate the outcomes.

Results: In our study, major complication in open herniotomy group was surgical site infection (22%), hematoma (10%), intra operative bleeding (16%), seroma formation (8%) with minimum operative duration was ~60 minutes, hospital stay of 2-3 days while no such complication reported in laparoscopic guided needle assisted hernia sac ligation group being operative time of ~20 minutes, hospital stay of 1 day with better cosmetic results.

Conclusions: We conclude that laparoscopic guided needle assisted hernial sac ligation is simple, safe, efficacious with its own advantage in comparison to conventional open herniotomy and should be acceptable alternative to traditional open herniotomy approach for congenital hernia.

Keywords: Laparoscopic guided needle assisted hernia repair, Open herniotomy, Congenital inguinal hernia

INTRODUCTION

Congenital inguinal hernia is one of the commonest surgical problems in paediatric age group.

Patent processes vaginalis is the common etiological factor for both of them. Inguinal hernias in children are found in 10-50 per 1000 live births.¹ It is higher in premature and low birth weight infants (17-30%). Inguinal hernia is common in boys (M:F=8:1).²

Conventional description of open inguinal hernia repair in children requires that, the external inguinal ring should be incised; the processes vaginalis or hernia sac be dissected, twisted and doubly ligated. Laparoscopic repair of inguinal hernias in paediatric patients was first described by El-Gohary. Initially this operation was performed only in female patients because the safety of the vas and vessels are of concern in males. Monteput and Esposito were the first to use laparoscopy in the repair of inguinal hernias in male children using an intracorporeal purse-string suture to close the inguinal ring, while Schier described

intracorporeal Z-suture closure first in girls only and then in boys.⁷ In groin hernia repair, recurrence is the most important aspect of the complications.¹⁴

Laparoscopic hernia repair is routinely performed in many centers, we devised a simple method of encircling the internal ring by using a conventional 18G Touhy needle, a unique technique of laparoscopic guided needle assisted congenital hernial sac ligation using a minimally invasive technique without the need of hydro dissection as done by Tatekawa.³ Previous study by Yoshijawa mentioned some of the complications which we have not encountered.⁴ Our objective is to compare the surgical outcome in terms of mean operative time, post operative pain, recurrence, local complication, cosmetic results in comparison with open congenital hernia repair.

METHODS

This prospective study was conducted on indoor patients of Surat municipal institute of medical educational and research hospital with the approval of hospital ethical committee between November 2018 to April 2020.

Study duration November 2018 to April 2020 (18 months).

Inclusion criteria included patients between age 1-16 years with reducible congenital inguinal hernia.

Exclusion criteria excluded patients below 1 year and above 16 years age, patients with irreducible inguinal hernia, patients with congenital hydrocele and patients with comorbid conditions.

Every month approximately 5-6 patients of congenital inguinal hernia being operated in our hospital, we have taken reference of previous record of surgeries for congenital inguinal hernia and we have documented the clinical and demographically data of those patients in (Microsoft excel) software and calculated average of each month and calculated the sample size accordingly by purposive sample techniques.

Data was analyzed by SPSS version 20 software.

The 100 patients of age between 1-16 years without any comorbidity were randomized in two groups who underwent either laparoscopic surgery (50)-group A OR open surgery (50)-group B for reducible congenital inguinal hernia.

Both procedures were done under general anesthesia. The operative mode was decided on the basis of randomization and patient were convinced and written and informed consent were taken. The operative time, length of hospital stays, intra and postoperative complications, cosmetic aspects and treatment of contralateral occult hernia between the two groups were compared.

Operative techniques

Group A: General anesthesia given in supine position and after that pneumoperitoneum created through Veress needle and 5 mm telescope is placed in umbilicus. groin region examined to confirm the diagnosis. Prolene loop formed inside 18 G Toughy needle after that small stab incision given in anterior abdominal wall just above and lateral to deep ring. Needle is inserted up to extra peritoneal space and then extra-peritoneal needle dissection done by swapping movement till vas deference and then peritoneum is punctured lateral to vas deference and loop is inserted inside peritoneal cavity and needle is removed keeping both free ends outside. Now needle is inserted through Same puncture side inside extra peritoneal side and advanced superomedial to deep ring and advanced till vas deference and punctured medially to vas with care to avoid injury to vas and inferior epigastric artery again thereafter needle is pushed into previously placed loop through loop. separate prolene thread passed through needle to come inside cavity through prolene loop now loop is pulled out to bring the single thread end outside abdomen and both end of the same thread tightens which encircle deep ring leaving peritoneum over vas to avoid injury. Threat tied at skin and cut with knife and then knot buried inside subcutaneous tissue. Hereby we achieve ligation of hernial sac and fixation with anterior abdominal wall. Care must be taken to avoid injury to vas and cord structure in male and to round ligament in female. All patient discharged on next day morning.

Group B: Conventional open herniotomy performed.

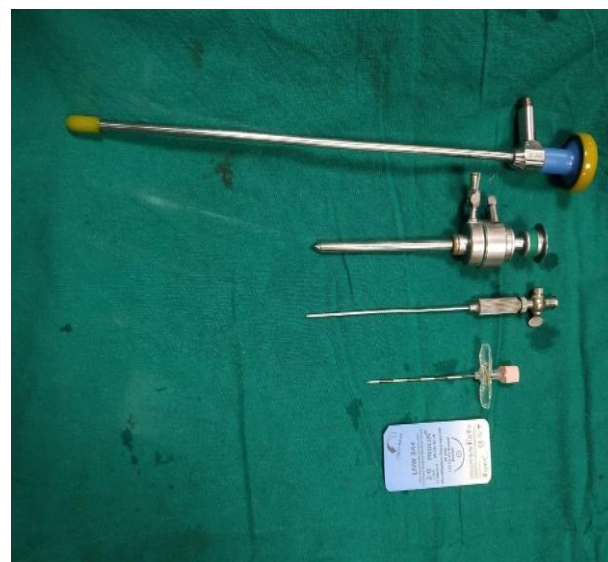

Figure 1: Instruments (Below to upwards). Proline 2-0, 18G-Touhy needle, Veress needle, 5 mm laparoscopic trocar and 5 mm laparoscopic camera.

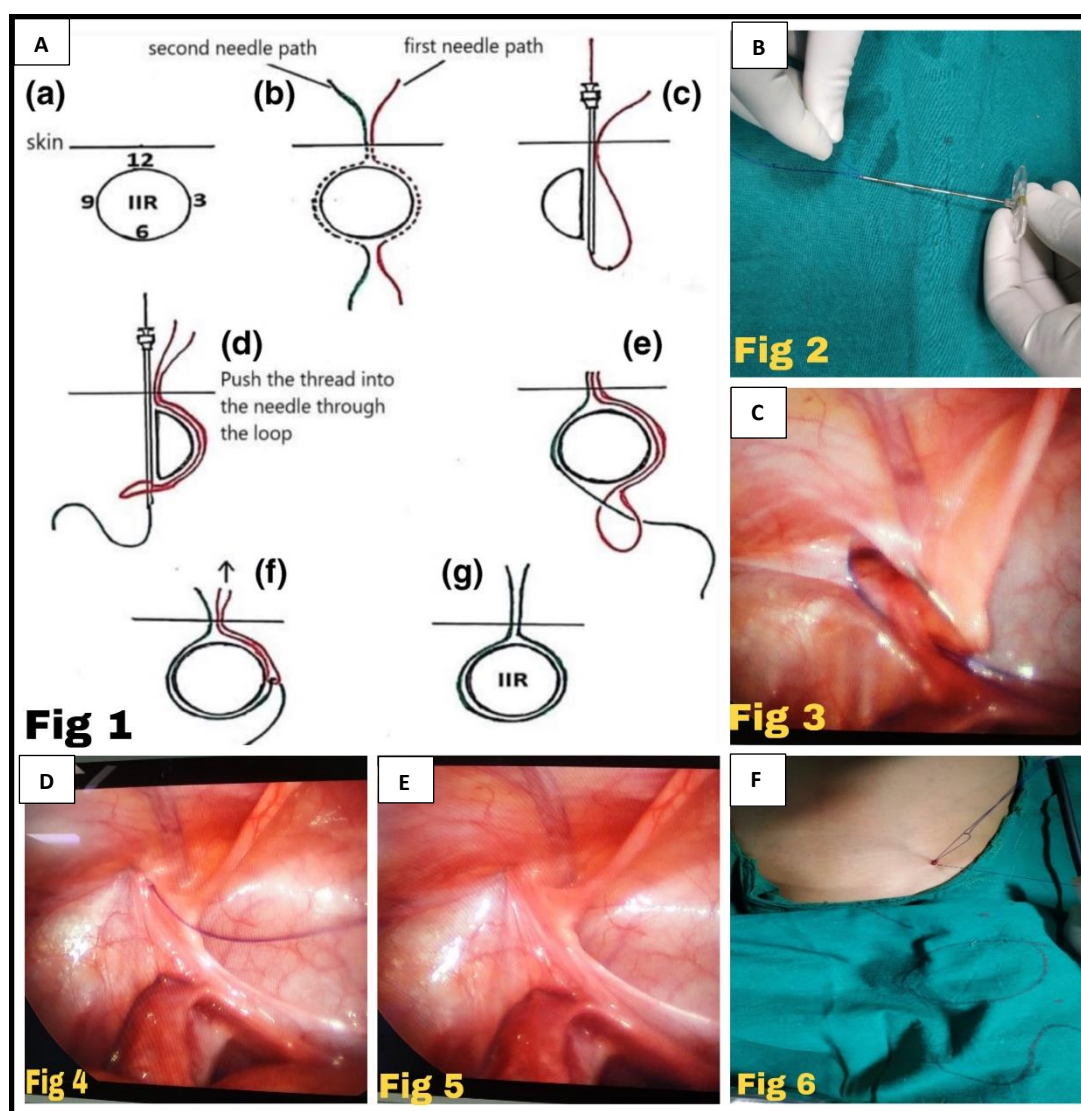


Figure 2 (A-F): Schematic diagram of operative procedure being performed in relation to the internal ring, formation of prolene loop, lateral to internal ring, 18G Touhy needle with folded 2-O prolene is inserted forming a loop, the loop is drawn out along with the medially inserted prolene the ring is encircled in an extra peritoneal plane for the placement of the purse sting suture, obliteration of internal ring with no hernial defect seen and the knot inside sub cutaneous tissue placed.

RESULT

In our study 50 patients were kept in control group who underwent conventional open herniotomy and 50 patients kept in study group who underwent laparoscopic needle assisted hernial sac ligation. Major complication in conventional herniotomy group was SSI (surgical site infection) (22%), hematoma (10%), intra operative bleeding (16%), seroma formation (8%). There was no such complication reported in laparoscopic guided needle assisted hernial sac ligation group. Recurrence noted in patients who underwent conventional herniotomy (6%) at the end of 6 months and scar mark at the end of 1 year in all patients who underwent conventional herniotomy. In laparoscopic guided needle assisted hernial sac ligation there was no recurrence reported at the end of 1 year and no scar marks seen.

The conventional herniotomy patients had total duration of hospital stay was between 1-3 days group with mean duration of hospital stay was 2 days. In laparoscopic guided needle assisted repair patients had total duration of hospital stay was 1 day.

Table 1: Age and sex wise distribution of all the subjects.

Age (years)	Sex (%)	
	Female	Male
1-4	4 (8)	20 (40)
5-8	7 (14)	23 (46)
9-12	9 (18)	23 (46)
13-16	3 (6)	11 (22)
Total patient	23 (23)	77 (77)

In our study there were 77% male patients with majority belongs to age group of 5-12 years followed by 1-4 years and 23% was female with majority belongs to age group of 9-12 years followed by 5-8 years. There was male preponderance with male to female ratio of 3.34:1.

Table 2: Duration of surgery.

Duration of surgery (min)	Conventional herniotomy, (%)	Laparoscopic guided needle assisted repair, (%)
15-30	0	49 (90)
31-45	0	1 (2)
46-60	42 (84)	0
61-75	3 (6)	0
76-90	0	0
91-105	0	0
106-120	4 (8)	0
121-135	1 (2)	0
Total	50 (100)	50 (100)

Table 3: Duration of hospital stay for the study subjects.

Day of hospitalization, (days)	Conventional herniotomy (%)	Laparoscopic guided needle assisted repair (%)
1	1 (2)	50 (100)
2	45 (90)	0
3	4 (8)	0
>3	0	0

Table 4: Details of complications in our study.

Type of complication	Conventional herniotomy (%)	Laparoscopic guided needle assisted repair, (%)
Bleeding	8 (16)	0
Hematoma	5 (10)	0
Seroma formation	4 (8)	0
SSI	11 (22)	0
Testicular ascent	0	0
Total no. of patients with complications (%)	28 (56)	0
Total no. of patients without complications (%)	22 (44)	50 (100)

In laparoscopic guided needle assisted repair duration of surgery was between 15-30 minutes in 98% patients while in conventional herniotomy it was 46-60 minutes in 84% of patients. In laparoscopic guided needle assisted repair

was having lesser duration of operation with $p < 0.0001$. So, that there is statistically significant difference in mean operation time in study.

Table 5: Details of cosmesis after 1 year.

Scar at the end of 12 months	Conventional herniotomy, (%)	Laparoscopic guided needle assisted repair, (%)
Present	50 (100)	0
Absent	0	50 (100)

Table 6: Details of recurrence after 6 months and 1 year follow up.

Recurrence	Conventional herniotomy, (%)	Laparoscopic guided needle assisted repair, (%)
Recurrence at the end of 6 months	2 (4)	0
Recurrence at 1 year	1 (2)	0
No recurrence	47 (94)	50 (100)

Table 7: Summary of result.

Parameters	Laparoscopic guided needle assisted congenital hernial sac ligation	Conventional open herniotomy
Mean operative time (Min)	15-30 (20.74 min. average)	46-120 (60.48 min average)
Post operative pain	Less pain in comparison	More pain in comparison
Intra/ post op complications	0	28
Contralateral occult hernia diagnosed	5	0
Cosmetic results (scar \pm)	Scar absent	Scar present
Recurrence	0 patient	3 patients
Length of stay at hospital	1 day	1-3 days

In laparoscopic guided needle assisted repair 100% patients discharged next post op day while in conventional herniotomy 90% of patients were discharged after 2 days.

In conventional herniotomy 56% of patients have one or other complications in which 22% developed SSI followed by bleeding (16%) and hematoma (10%) and seroma (8%) whereas no complications observed in laparoscopic guided needle assisted repair. Fisher's exact test was applied and $p < 0.0001$, so that there was statistically significant

difference in comparison of complication in these two groups.

Scar marks were absent in laparoscopic guided needle assisted hernia where as in conventional herniotomy scar marks was present.

In conventional herniotomy 4% of patients had recurrence at the end of 6 month and 2% patient had recurrence at 1 year while there was no recurrence observed in laparoscopic guided needle assisted repair. On applying chi-square test $p=0.0803$ so there is no significant difference in both these group in terms of recurrence at the end of 6 months.

DISCUSSION

In children, the standard surgical treatment of inguinal hernia is limited to ligation of the hernia sac.⁶ Internal ring is normally reached by dissecting the hernia sac from the cord structures, which bears potential risk of injuring the spermatic vessels and the vas deferens, hematoma formation, wound infection, iatrogenic testicular ascent, testicular atrophy, and recurrence of the hernia. It also carries potential risk of damaging the tubes and ovaries which may lead to infertility.⁶⁻⁸

Laparoscopic repair of hernia in children has emerged recently as an alternative method of treatment and is rapidly gaining popularity with more and more authors endorsing its feasibility, efficacy, and safety.⁶⁻⁹

Table 8: Comparison between different laparoscopic needle assisted hernia repair.⁵

Author	Year	Published study type	Patients/repair	Type of repair	Median op time (Uni/bil)	Grasper	Follow up	Recurrence rate, (%)
Tatekawa ³	2011	Prospective	13/18	LPEC	25/49	1	6.07 months (2-12 months)	0
Mc Clain et al	2014	Prospective	495/710	LNAR	20/26	1	10.7 months (0.3-38.4 months)	0.56
Liu et al ⁵	2018	Prospective	15/18	LNAR	22/27	0	12.07 months (7-17 months)	0
Our study	2020	Prospective	50/50	LNAR	20.74 min (uni)	0	Up to 1 year	0

LNAR- Laparoscopic needle assisted repair, LPEC-Laparoscopic percutaneous extracorporeal closure.

The Ferguson/open hernia repair is considered as a gold standard treatment for repair of inguinal hernia in children. Over the past two decades, Different laparoscopic techniques of inguinal hernia repair in children have been described. It started with the use of three ports which narrowed down to single port using of various devices. Schier used 2-mm instruments without a trocar for intra-abdominal suturing of the IIR in 25 girls by the placement of two Z-sutures with good result.⁷ Lee and Liang performed micro-laparoscopic high ligation of IIR in 450 patients with good results and low recurrence rate (0.88 %).⁴⁻⁶ Ozdegiz et al first reported repair of CIH using single port using Tuohy needle to accomplish the encircage.⁸

It started with the use of three ports which narrowed down to single port using of various devices.

In our study laparoscopic needle assisted hernia repair we have used single camera port with extra corporal knot tying and subcutaneous burying of knot.

Shalaby et al used Reverdin needle (Martin Medizin Technik, Tuttlingen, Germany) for extracorporeal ligation of the IIR in 187 groin hernias in 150 patients with superior results over intracorporeal techniques. Endo and Ukiyama introduced the endo-needle that is designed especially for extracorporeal closure of the patent processus vaginalis.

Tam et al had reported laparoscopic extracorporeal hernia repair by hook method in 433 cases with low recurrence rate (0.35 %).⁸

Shalaby et al had further compared the intracorporeal purse string suture with extracorporeal closure using Reverdin needle (RN). Laparoscopic hernia repair by RN resulted in a marked reduction of operative time and excellent cosmetic results with low recurrence rate. In our technique of laparoscopic needle assisted hernial sac ligation we have used Toughy needle of 18 G with extra-corporal knot tying and subcutaneous burying of knot with no recurrence rate at the end of 1 year with excellent cosmetic results and less operative time in compare to conventional open herniotomy.⁸

In our study we have operated in 77% of male patients and 23% of female patients with mean age in male is between 5-12 years while in female mean age is 8-12 years, it is due to the fact that the incidence of inguinal hernia from birth to 15 years is 6.62 and 0.74% in males and females, respectively and also due to geographical and population distribution differences.⁹

The mean operative time for unilateral hernia repair in our study was 20.74 minutes whereas in unilateral and bilateral repair in Shrestha et al study was 17 and 24 minutes respectively which is similar to that of Ferdous et al 21.2

and 30.3 minutes and Kumar et al 13 and 20 minutes for unilateral and bilateral repair respectively.^{10,11,19,20} Even though a keen attention is needed for vas in case of male while encircling the ring there was no significant difference in operative time between the genders.⁹

In open herniotomy mean operative time in our study is 60.48 min which is three times of laparoscopic hernia repair duration in the open hernia repair, initial time is spent in gaining access to the internal ring by localizing and dissecting the sac from the cord structures also at our centre open herniotomy was being performed by senior residents. Whereas, in laparoscopy internal ring is visualized directly from within the abdomen which makes the area of dissection bloodless, and magnification renders anatomy very clear, making surgery precise.^{7,12,13}

At our centre it is being performed by consultant. In our study, the total complication rate was different between the laparoscopic needle assisted hernia repair and open hernia group. These results are totally different from Yang et al who reported no significant differences in the incidence of hydrocele, wound infection, scrotal oedema, erythema, and testicular atrophy.¹³ However, the results of this study should be interpreted with caution: as reflected in the degree of heterogeneity, the complications that were analyzed largely varied among the included studies. Thereby, selective reporting bias could not be assessed. In 2014, Esposito et al reviewed 22 studies and concluded that there were less complications in the laparoscopic hernia repair group (0.9% vs. 2.7%; $p=0.001$).^{14,18} More recently, Feng et al also found less postoperative complications (15 vs. 31 complications) and less major complications (i.e., scrotal oedema, iatrogenic ascent of the testis, and testicular atrophy) in boys (4 vs. 14 complications) after laparoscopic hernia repair.^{15,20}

In our study no complications observed in laparoscopic needle assisted method, whereas puncture site bleeding in Shrestha et al study was 3.57% and in Ferdous et al study was 2.97%.^{3,19,20}

In our study 56% of patients of open herniotomy showed one or more complications like SSI (22%) followed by bleeding (16%) and hematoma (8%). In Dhakne study reactive hydrocele was noticed in 22 cases operated as open herniotomy and all of them resolved by second week. Hydrocele during postoperative period is a frequent occurrence and indicates the continuing fluid secretion from the left-over distal sac.²¹

The incidence of testicular atrophy is rare in laparoscopic hernia repair because of the multiple collaterals of the testis which are not disturbed.^{11,12}

In our study at 1 year of follow up we have not detected any case of testicular atrophy in either group.

Previous studies repeatedly found a trend towards higher recurrence rates following laparoscopic hernia repair.¹⁶⁻¹⁸ However, in our study recurrence rates in open herniotomy

is more and in laparoscopic guided needle assisted hernia is zero as at our centre open herniotomy performed by senior residents and intra-operative failure to identify hernial sac may be the probable reason, whereas the laparoscopic hernia performed by the consultant.

The recurrence rate in Shrestha et al study was 1.78% which is similar to Ferdous et al 1.98% and Patkowski et al 2.1%.^{4,19,21}

There was an inconsistent follow-up time that ranged from 1, 3, 6, 12 months, and again selective reporting bias could not be assessed. Additionally, as different laparoscopic techniques and advanced methods of minimally invasive closure of the inguinal hernia might affect the risk for recurrence, future analyses remain necessary.

One of the advantages of laparoscopic repair of congenital inguinal hernia (CIH) is easy detection of contra-lateral occult hernias thus preventing the future occurrence. Persistent processus vaginalis (PPV) is responsible for most of the occult hernias; the prevalence of which is 23-37%.⁹ In our study it was 10%. This low rate is probably because we conducted the study in children aged one year and above whereas the incidence of PPV is highest in the first year of life.

Limitation

Due to COVID-19 pandemic some patients have migrated 8% or expired 7% caused loss of follow up in the study.

CONCLUSION

We conclude that our technique is simple, safe, and efficacious for pediatric inguinal hernia repair. In comparison to open herniotomy it has definitive advantages with respect to operation duration, hospital stay, post operative complication, recurrence and cosmesis. It does not need any special equipment and the procedure can be performed by surgeons with basic laparoscopic skill.

ACKNOWLEDGMENTS

Author would like to thanks to Dr. Jitendra Darshan (HOD general surgery, SMIMER) for guidance and general support.

Funding: No funding sources

Conflict of interest: None declared

Ethical approval: The study was approved by the Institutional Ethics Committee

REFERENCES

1. Ferguson AH. Oblique inguinal hernia: typical operation for its radical cure. JAMA. 1899;XXXIII(1):6-14.
2. Boocock GR, Todd PJ. Inguinal hernias are common in pre term infants. Arch Dis Child. 1985;60:669-70.

3. Tatekawa Y. Laparoscopic extracorporeal ligation of hernia defects using an epidural needle and preperitoneal hydrodissection. *J Endourol.* 2012;26(5):474-7.
4. Patkowski D, Czernik J, Chrzan R, Jaworski W, Apoznan'ski W. Percutaneous internal ring suturing: a simple minimally invasive technique for inguinal hernia repair in children. *J Laparoendosc Adv Surg Tech A.* 2006;16(5):513-7.
5. Liu J, Wu X, Xiu W. A comparative study examining laparoscopic and open inguinal hernia repair in children: a retrospective study from a single center in China. *BMC Surg.* 2020;20:244.
6. Lee Y, Liang J. Experience with 450 cases of micro-laparoscopic herniotomy in infants and children. *Pediatr Endosurg Innov Tech.* 2002;6(1):25-8.
7. Schier F. Laparoscopic inguinal hernia repair-a prospective personal series of 542 children. *J Pediatr Surg.* 2006;41:1081-4.
8. Shalaby R, Ismail M, Durham A. Laparoscopic hernia repair in infancy and childhood: evaluation of 2 different techniques. *J Pediatr Surg.* 2010;45(11):2210-6.
9. Wulkan ML, Wiener ES, Van Balen N, Vescio P. Laparoscopy through the open ipsilateral sac to evaluate presence of contralateral hernia. *J pediatri surg.* 1996;31(8):1174-7.
10. Takehara H, Yakabe S, Kameoka K. Laparoscopic percutaneous extraperitoneal closure for inguinal hernia in children: clinical outcome of 972 repairs done in 3 pediatric surgical institutions. *J Pediatr Surg.* 2006;41(12):1999-2003.
11. Barqawi A, Furness P, III, Koyle M. Laparoscopic palomo varicoelectomy in the adolescent is safe after previous ipsilateral inguinal surgery. *BJU Int.* 2002;89(3):269-72.
12. Riccabona M, Oswald J, Koen M, Lusuardi L, Radmayr C, Bartsch G. Optimizing the operative treatment of boys with varicocele: sequential comparison of 4 techniques. *J Urol.* 2003;169(2):666-8.
13. Yang C, Zhang H, Pu J, Mei H, Zheng L, Tong Q. Laparoscopic vs open herniorrhaphy in the management of pediatric inguinal hernia: a systemic review and meta-analysis. *J Pediatr Surg.* 2011;46:1824-34.
14. Esposito C, St Peter SD, Escolino M, Juang D, Settimi A, Holcomb GW. Laparoscopic versus open inguinal hernia repair in pediatric patients: a systematic review. *J Laparoendosc Adv Surg Tech A.* 2014;24:811-8.
15. Feng S, Zhao L, Liao Z, Chen X. Open versus laparoscopic inguinal herniotomy in children: a systematic review and meta-analysis focusing on postoperative complications. *Surg Laparosc Endosc Percutan Tech.* 2015;25:275-80.
16. Alzahem A. Laparoscopic versus open inguinal herniotomy in infants and children: a meta-analysis. *Pediatr Surg Int.* 2011;27:605-12.
17. Gause CD, Casamassima MGS, Yang J, Hsiung G, Rhee D, Salazar JH et al. Laparoscopic versus open inguinal hernia repair in children ≤ 3 : a randomized controlled trial. *Pediatr Surg Int.* 2017;33:367-76.
18. Koivusalo AI, Korpela R, Wirtavuori K, Piiparinen S, Rintala RJ, Pakarinen MP. A single-blinded, randomized comparison of laparoscopic versus open hernia repair in children. *Pediatrics.* 2009;123:332-7.
19. Shrestha BB, Shrestha S. Laparoscopic Needle assisted Repair of Inguinal Hernia in Children in Manipal Teaching Hospital, Pokhara. *Nepal J Med Sci.* 2019;4(2):20-4.
20. Ferdous KM, Hasan MS, Hossain MD. Laparoscopic needle assisted extracorporeal repair of inguinal hernia in children: our experience. *J. Pediatr Neonatal Care.* 2018;8(2):90-2.
21. Dhakne BS, Beedkar AN, Dalvi MR, Bhalgat BS. Herniotomy and its outcome in congenital inguinal hernia at a tertiary care hospital: descriptive study. *Int Surg J.* 2017;4:157-61.
22. Chang SJ, Chen JC, Hsu CK, Chuang FC, Yang SD. The incidence of inguinal hernia and associated risk factors of incarceration in pediatric inguinal hernia: a nation-wide longitudinal population-based study. *Hernia.* 2016;20(4):559-63.

Cite this article as: Prasad D, Satani Y, Bochiya G. A comparative prospective study of laparoscopic guided needle assisted hernial sac ligation versus open herniotomy surgery in congenital inguinal hernia management. *Int Surg J* 2022;9:16-22.