

Original Research Article

Polypropylene suture as a seton in recurrent fistula-in-ano in lower socioeconomic class-a good option

Kiran Patel*

Department of General Surgery, NAMO Medical Education and Research Institute, Silvassa, Dadra and Nagar Haveli and Daman and Diu, UT, India

Received: 03 October 2021

Accepted: 18 October 2021

*Correspondence:

Dr. Kiran Patel,

E-mail: drkiran22@yahoo.com

Copyright: © the author(s), publisher and licensee Medip Academy. This is an open-access article distributed under the terms of the Creative Commons Attribution Non-Commercial License, which permits unrestricted non-commercial use, distribution, and reproduction in any medium, provided the original work is properly cited.

ABSTRACT

Background: Recurrent anal fistulas after previous fistula surgery are a unique problem that typically necessitates more anal surgical experience to address the cause of recurrence. The present study was planned with the objective to determine the outcomes of the polypropylene suture as a seton placement for the treatment of recurrent anal fistula.

Methods: Patients between the ages of 20-80 years with recurrent fistula-in-ano with single external opening and with history of previous surgery. Patients with preoperative incontinence, patients with difficult follow-up and who were not ready to participate in the study, patients with fistulas caused by inflammatory bowel disease, malignancy, tuberculosis, or trauma, patients with a horseshoe or multiple fistulas, patients with recurrent fistula-in-ano with multiple external opening, or recurrent fistula-in-ano with diseases like Crohn's disease, tuberculosis, actinomycosis, malignancy, or high level fistula-in-ano without internal opening, and patients with synchronous anorectal problems such as haemorrhoids were excluded.

Results: Post-operative pain was observed in all patients while discharge, bleeding and inflammation were observed in 27, 10 and 8 patients, respectively on day 0. Majority of post-operative symptoms were resolved in almost all patients except, pain and discharge were observed in 2 and 1 patients, respectively on day 7. At 6 months follow-up, incontinence of flatus was found out in 2 patients while no patient had incontinence of faeces.

Conclusions: Polypropylene suture as a seton in recurrent fistula-in-ano, in previously operated patient is safe and most acceptable treatment. Ksharsutra is not easily available but polypropylene suture is easily available.

Keywords: Polypropylene suture; Seton, Recurrent fistula-in-ano

INTRODUCTION

Fistula-in-ano is a frequent anorectal condition in which a continuous granulating track runs from the anal canal or rectum to the perianal skin or perineum, causing the patient significant discomfort and morbidity.^[1] For the first time in 500 B. C., Sushruta explained the importance of Ksharsutra in the care of anal fistula. In India, the Ksharsutra therapy is used to treat fistula-in-ano with a good success rate (recurrence of 3.33% only).² Ksharsutra treatment has the lowest rate of recurrence (5.88%).³

The most common symptoms of this illness are

intermittent discomfort, itching, and pus, faeces, or blood discharge. Parks et al divided the anal fistula into four basic categories based on the relationship of the primary fistula track to the external anal sphincter: intersphincteric, transsphincteric, suprasphincteric, and extrasphincteric. The surgical arrangement would not be complete without this classification.⁴⁻⁶

For the treatment of fistula-in-ano, various techniques are recommended, including open surgery in the form of fistulectomy or fistulotomy; Seton treatment (chemical or cutting); chemical elimination of the tract by corrosives; and application of fibrin glue or fistula plug.⁷ Anal fistula

surgery is based on the principles of removing the fistula, preventing recurrence, and preserving sphincter function. Identifying the primary opening and dividing the least amount of sphincteric muscle possible is usually the key to success. The majority of anal fistulae have traditionally been treated with fistulotomy or fistulectomy, both of which have proven to be effective. The technique, however, necessitates local, regional, or general anaesthetic. Post-operative wounds are frequently left open, and secondary intention takes a long time to heal fully.⁸

In addition, there is a significant risk of recurrence and incontinence, particularly in high-risk patients with complex or high fistulas, women with anterior fistulas, and the elderly. For hundreds of years, setons have been used to treat anal fistulas. To avoid faecal incontinence and recurrence, setons were usually described primarily for high or complex anal fistulas in the literature. This method was found to be inconvenient and slow to use.^{8,9} A seton can be used alone, in conjunction with a fistulotomy, or in stages. This technique is beneficial in patients with the following conditions: (i) Complex fistulas (i.e., high trans-sphincteric, supra-sphincteric, extra-sphincteric) or multiple fistulas; (ii) Recurrent fistulas after previous fistulotomy; (iii) Anterior fistulas in female patients; (iv) Poor preoperative sphincter pressures; and (v) Patients with Crohn disease or patients who are immunosuppressed. Setons serve to drain, promote fibrosis, and cut through the fistula, in addition to identifying the amount of sphincter muscle implicated visually.^{10,11}

Surgical treatment of anal fistula is associated with significant risk of recurrence (0.7-26.5%). It is associated with high risk of impaired continence (5-40%).¹² Complex anal fistulas are difficult to treat because they usually involve a large section of the anal sphincters, making complete eradication of the fistula tract associated with a significant risk of continence impairment. Failure to remove the original tract and its secondary extensions and to sufficiently drain sepsis, on the other hand, may result in the anal fistula persisting or recurring.¹³ Recurrent anal fistulas after previous fistula surgery are a unique problem that typically necessitates more anal surgical experience to address the cause of recurrence and navigate through the disrupted anatomy following earlier surgery.¹⁴

With this background, the present study was planned with the objective to determine the outcomes of the polypropylene suture as a seton placement for the treatment of recurrent anal fistula in a tertiary care teaching hospital.

METHODS

Between January 2019 and May 2020, a prospective, cross-sectional study was conducted at NAMO medical education and research institute, Silvassa, Dadra and

Nagar Haveli and Daman and Diu (UT), India. The institutional ethics committee granted it approval to the protocol. Informed written consent was obtained from all patients before inclusion in the study. This study included all patients (males and females) between the ages of 20 and 80 who had a recurrent fistula-in-ano with single external opening and with history of previous surgery and visiting the department of general surgery of the institute. Patients with preoperative incontinence, patients with difficult follow-up and who were not ready to participate in the study, patients with fistulas caused by inflammatory bowel disease, malignancy, tuberculosis, or trauma, patients with a horseshoe or multiple fistulas, patients with recurrent fistula-in-ano with multiple external opening, or recurrent fistula-in-ano with diseases like Crohn's disease, tuberculosis, actinomycosis, malignancy, or high level fistula-in-ano without internal opening, and patients with synchronous anorectal problems such as haemorrhoids were all excluded.

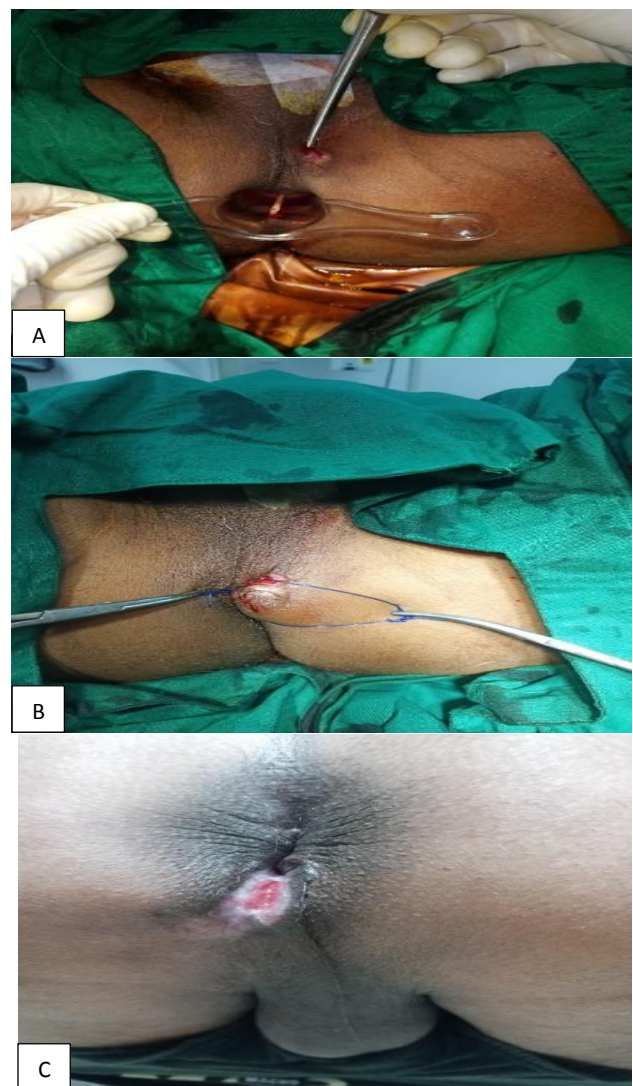


Figure 1 (A, B and C): Operative and post-operative images of recurrent fistula-in-ano: introduction of proctoscope in anal canal, suturing of fistula; and post-operative healing of fistula.

Patients were recruited in the study randomly and on pro-rata basis. All the patients participating in the study were explained clearly about the purpose and nature of the study in the language they can understand and written informed consent was taken before including them in the study. Demographic and clinical characteristics of the patients were assessed and recorded in case record form. The patient was given extended lithotomy position and spinal anesthesia was given. Proctoscope was introduced and internal opening was seen. Then normal saline was injected through external opening and checked for the jet of flow coming out through internal opening. Then malleable metallic probe was passed with eye at the tip through external opening in course of fistulous tract gently, which came out through internal opening under vision. From eye at tip of probe, polypropylene suture was passed and pulled the probe outside. There were two sutures in fistulous tract. One suture was tied firmly along the tract. Other suture kept loose as a guide for change of suture in follow up procedure. Follow up procedure was done under local anaesthesia as a day care surgery. We have done follow up till 6 months post operatively (Figure 1).

Using Microsoft office excel, the data was statistically analysed. Data was presented in the form of absolute numbers with or without percentages, means with standard deviations, or medians with ranges.

RESULTS

The present study has included 34 patients with recurrent fistula-in-ano, meeting the selection criteria. Out of total 34 patients, majority of the patients were belonged to age group of 30-39 years (14, 41.18%) and 40-49 years (10, 29.41%) with mean age was 45.72 Years and age range was 31 years-69 years. There were 15 males and 19 females with a male: female ratio of 1:1.27. According to locality of patients, a majority (24, 70.59%) of the patients were belong to rural areas (Table 1).

The most common clinical presentation of patients with recurrent fistula-in-ano was perianal pain (34, 100%). The other common presentations were: constipation or passage of hard stools (18, 52.94%); blood in stools (12, 35.29%); pruritus (11, 32.35%); and fever (8, 23.53%) (Table 2).

According to table 3, post-operative pain was observed in all patients while discharge, bleeding and inflammation were observed in 27 (79.41%), 10 (29.41%) and 8 (23.53%) patients, respectively on day 0. Majority of post-operative symptoms were resolves in almost all patients except, pain and discharge were observed in 2 (5.88%) and 1 (2.94%) patient, respectively on day 7.

In the present study, patients were followed-up till 6 months post-operatively. Out of total 34 patients, 2 patients were lost in follow-up. At 6 months follow-up, incontinence of flatus was found out in 2 (6.25%) patients

while no patient had incontinence of faeces.

Wound infection has been found out in only one patient (Table 4).

Table 1: Demographic characteristics of the patients, (n=34).

Characteristics	Frequency	Percentage (%)
Gender	Males	15
	Females	19
Age groups (Years)	30-39	14
	40-49	10
	50-59	8
	≥60	6
Residence	Urban	10
	Rural	24

Table 2: Clinical presentation of the patients, (n=34).

Presentations	Frequency	Percentage (%)
Perianal pain	34	100
Constipation or passage of hard stools	18	52.94
Blood in stools	12	35.29
Pruritus	11	32.35
Fever	8	23.53

Table 3: Post-operative observation, (n=34).

Observations	Day 0		Day 3		Day 7	
	N	%	N	%	N	%
Pain	34	100	13	38.24	2	5.88
Discharge	27	79.41	16	47.06	1	2.94
Bleeding	10	29.41	4	11.76	0	0.00
Inflammation	8	23.53	2	5.88	0	0.00

Table 4: Post-operative follow-up at 6 months, (n=32).

Observations	Frequency	Percentage (%)
Incontinence of flatus	2	6.25
Incontinence of feces	0	0.00
Soiling	10	31.25
Fully continent	10	31.25
Wound infection	1	3.13

DISCUSSION

The most difficult aspect of treating anal fistulas for surgeons is adjusting the cure and continence outcomes. During fistulotomy, there is a risk of sphincter muscle injury, which can result in a high risk of anal incontinence.¹⁵ Anal fistula treatment's goal is to close the track while maintaining continence.¹⁶ Setons allowed the majority of internal and external muscular sphincter fibres involved in anal fistula to be preserved. Setons are helpful in the treatment of trans-sphincteric anal fistulas because they allow acute inflammation to drain and anal

sphincters to remain open.¹⁷

Worldwide conventional treatment for fistula-in-ano is complete excision of fistulous tract. But in India since 500 B. C. as per reference of Sushruta Samhita, an ancient Indian surgical text, Ksharsutra treatment for fistula-in-ano is being practiced.³ In Ksharsutra treatment, the chance of having anal incontinence is almost nil as compared to conventional surgery.¹² The rate of recurrence of disease in Ksharsutra therapy is 3.33% as compared to conventional surgery where it is reported to be up to 26.5%.¹⁸ Because of this beauty ICMR and CCIM are taking lots of efforts to propagate this Ksharsutra technique, but the main hurdle is its global acceptability. The Ksharsutra practice is limited in India because Ksharsutra a medicated thread is not available in every part of India. So, polypropylene suture was used in the present study. It is easily available in operation theatre of any surgical hospital. No systemic side effects are encountered with this method, only pain and induration are observed. In previously operated case, sometimes it is difficult to negotiate through internal opening. But with patience and experience it can be passed under vision and so spinal anaesthesia is preferred.

Setons are commonly used as either a loose or tight cutting seton. In order to prevent obstruction of the fistula tract due to chronic inflammatory diseases in the anal region and inflammatory bowel diseases, loose seton placement is usually done for drainage. The majority of patients have perianal fistulas caused by other factors, which are treated with cutting seton. The proper selection of seton materials is critical for ensuring patients' long-term quality of life and healing with the fewest number of operations possible.¹⁹

Seton materials reported in the literature include silk and nylon sutures, metal wire, elastic band, penrose drain, pieces of surgical gloves, and plastic clamps, but the majority prefer surgical sutures.²⁰ Parks and Stitz published their findings on the use of nylon surgical sutures to place setons in 1976.^{21,22} In 2002, a case series of 47 patients who had polypropylene PP setons reported that the average seton duration was 9 weeks, with a 2% recurrence rate. Another study of 30 patients found that 80 percent of those who had cutting seton placement healed within 5-10 weeks.²³

Durgun et al reported no recurrence in 10 patients in a 2002 study, with a mean waiting time of 40 days.²⁴ In a retrospective study of 24 patients who had tight seton placement, the waiting period was reported to be 14 months.²⁵ In 68 patients who had silk cutting seton placement, the average wound healing time was 8 weeks.²⁶ The seton fall-out time was not presented as it was in any of the other studies, but 75% of the patients stated that wound healing was completed in 8 weeks.²⁷ The long duration of this study was attributed to the fact that 25% of the participants had Crohn's disease. Subhas

et al. conducted a meta-analysis of the literature results to compare the outcomes of each material; however, due to the differences in surgical techniques, no definitive conclusion could be reached.²⁷

Akici et al have found out that patients healed in a single session was similar in both groups using silk and PP sutures, but the number of patients requiring multiple sessions was higher in the silk suture group. Furthermore, it was discovered that most patients undergoing silk seton placement required fistulotomy because the seton failed to transect after a certain level. Despite the fact that the PP material provided a better cut, pain and discomfort were significantly higher in group-2 patients than in group-1. The findings revealed that PP seton caused significantly more pain than silk seton, particularly during daily activities, and that this pain persisted even during defecation and rest.¹⁹

In summary, polypropylene suture as a seton in recurrent fistula-in-ano can be very cost-effective choice for clinical settings with limited resources. But the present study comprised of small sample size with comparatively short duration (6 months) of follow-up, which are the limitation of the study. So, study with larger sample size and longer follow-up required to strengthen the findings of the present study.

CONCLUSION

Polypropylene suture as a seton in recurrent fistula-in-ano, in previously operated patient is safe and most acceptable treatment. Ksharsutra is not easily available but polypropylene suture is easily available.

Funding: No funding sources

Conflict of interest: None declared

Ethical approval: The study was approved by the Institutional Ethics Committee

REFERENCES

1. Jimenez M, Mandava N. Anorectal Fistula. In: StatPearls. Treasure Island (FL): StatPearls Publishing; 2021 January 20. Available at: <https://www.ncbi.nlm.nih.gov/books/NBK560657/>. Accessed on 28 Jul, 2021
2. Kumar A, Kumar M, Jha AK, Kumar B, Kumari R. The Easiest Way to Insert Ksharsutra with the Help of an Infant Feeding Tube Instead of a Metallic Probe. Indian J Surg. 2017;79(4):371-3.
3. Panigrahi HK, Rani R, Padhi MM, Lavekar GS. Clinical Evaluation of Kshara sutra Therapy in the management of Bhagandara (Fistula-in-Ano)-A prospective study. Anc Sci Life. 2009;28(3):29-35.
4. Malik AI, Nelson RL. Surgical management of anal fistulae: A systematic review. Colorectal Dis. 2008;10:420-30.
5. Tozer P, Sala S, Cianci V, Kalmar K, Atkin GK, Rahbour G. Fistulotomy in the tertiary setting can

- achieve high rates of fistula cure with an acceptable risk of deterioration in continence. *J Gastrointest Surg.* 2013;17:1960-65.
6. Parks AG, Gordon PH, Hardcastle JD. A classification of fistula-in-ano. *Br J Surg.* 1976;63:1-12.
 7. Dutta G, Bain J, Ray AK, Dey S, Das N, Das B. Comparing Ksharasutra (Ayurvedic Seton) and open fistulotomy in the management of fistula-in-ano. *J Nat Sci Biol Med.* 2015;6(2):406-10.
 8. Seow-Choen F, Nicholls RJ. Anal fistula. *Br J Surg.* 1992; 79:197-205.
 9. Pearl RK, Andrews JR, Orsay CP, Weisman RI, Prasad ML, Nelson RL et al. Role of the seton in the management of anorectal fistulas. *Dis Colon Rectum.* 1993;36(6):573-7.
 10. McCourtney JS, Finlay IG. Setons in the surgical management of fistula in ano. *Br J Surg.* 1995;82(4):448-52.
 11. Memon AA, Murtaza G, Azami R, Zafar H, Chawla T, Laghari AA. Treatment of complex fistula in ano with cable-tie seton: a prospective case series. *ISRN Surg.* 2011;2011:636952.
 12. Bhat RP. Anal fistula with foot extension-treated by Ksharasutra (medicated seton) therapy-a rare case report. *Int J Surg Case Rep.* 2013;4(7):573-6.
 13. Bubbers EJ, Cologne KG. Management of Complex Anal Fistulas. *Clin Colon Rectal Surg.* 2016;29:43-9.
 14. Emile SH. Recurrent anal fistulas: When, why, and how to manage? *World J Clin Cases.* 2020;8(9):1586-91.
 15. Mennigen R, Laukötter M, Senninger N, Rijcken E. The OTSC® proctology clip system for the closure of refractory anal fistulas. *Tech Coloproctol.* 2015;19(4):241-6.
 16. Dudukgian H, Abcarian H. Why do we have so much trouble treating anal fistula. *World J Gastroenterol.* 2011;17:3292-6.
 17. Gurer A, Ozlem N, Gokakin AK, Ozdogan M, Kulacoglu H, Aydin R. A novel material in seton treatment of fistula-in-ano. *Am J Surg.* 2007;193:794-6.
 18. Pankaj S, Manoranjan S. Efficacy of Ksharsutra (medicated seton), therapy in the management of fistula-in-ano. *World J Colorectal Surg.* 2010;2(2):1-10.
 19. Akici M, Ersen O. The effect of suture selection in complex anal fistulas on the success of cutting seton placement and patient comfort. *Pak J Med Sci.* 2020;36(4):816-20.
 20. Williams JG, MacLeod CA, Rothenberger DA, Goldberg SM. Seton treatment of high anal fistulae. *Br J Surg.* 1991;78:1159-61.
 21. Parks AG, Stitz RW. The treatment of high fistulain-ano. *Dis Colon Rectum.* 1976;19:487-99.
 22. Theerapol A, So BY, Ngoi SS. Routine use of setons for the treatment of anal fistulae. *Singapore Med J.* 2002;43:305-7.
 23. El Mohamady MS. Cutting seton in management of complex perianal fistula—is it a safe procedure? *Menoufia Med J.* 2018;31(3):867.
 24. Durgun V, Perek A, Kapan M, Kapan S, Perek S. Partial fistulotomy and modified cutting seton procedure in the treatment of high extrasphincteric perianal fistulae. *Dig Surg.* 2002;19:56-8.
 25. Subhas G. Non-cutting setons for progressive migration of complex fistula tracts:a new spin on an old technique. *J Colorectal Dis.* 2011;26:793-8.
 26. Al-Marzooq TJ, Hassan QA, Alnaser MK, Al-Edani MS. Treatment of Fistula-In-Ano with Tight (Cutting) Seton:Analysis of Outcomes and Efficacy Assessment. *J Clin Diag Res.* 2017;11(11):30017.
 27. Subhas G, Bhullar JS, Al-Omari A, Unawane A, Mittal VK, Pearlman R. Setons in the treatment of anal fistula:review of variations in materials and techniques. *Digest Surg.* 2012;29(4):292-300.

Cite this article as: Patel K. Polypropylene suture as a seton in recurrent fistula-in-ano in lower socioeconomic class-a good option. *Int Surg J* 2021;8:3397-401.