

## Case Report

# Merkel cell carcinoma: a case report and literature review

Soulé-Martínez Christian Enrique<sup>1\*</sup>, Monroy-Ramírez Miguel Ángel<sup>2</sup>,  
Jaimes-Durán Edwing Michel<sup>1</sup>, Castellanos-Aguilar Leonel<sup>1</sup>,  
Ricarte-Almeida Eros Rafael<sup>1</sup>, Lupián-Angulo Arianne I.<sup>1</sup>

<sup>1</sup>Department of General Surgery, North Central Hospital of PEMEX, Mexico City, Mexico

<sup>2</sup>Department of Surgical Oncology, North Central Hospital of PEMEX, Mexico City, Mexico

**Received:** 05 July 2021

**Accepted:** 27 July 2021

### \*Correspondence:

Dr. Soulé-Martínez Christian Enrique,  
E-mail: [christiansoule10@gmail.com](mailto:christiansoule10@gmail.com)

**Copyright:** © the author(s), publisher and licensee Medip Academy. This is an open-access article distributed under the terms of the Creative Commons Attribution Non-Commercial License, which permits unrestricted non-commercial use, distribution, and reproduction in any medium, provided the original work is properly cited.

### ABSTRACT

Merkel cell carcinoma (MCC) is a rare, but highly aggressive, malignant neuroendocrine tumor, with a higher prevalence in men, Caucasians, and the elderly. It is usually identified in photo-exposed areas such as the head, trunk, and extremities. It is related to locoregional recurrences and metastases, which conditions a high mortality rate. Currently, the pathogenesis is unclear, but it is related to ultraviolet radiation, immunosuppression, and polyomavirus infection. Prompt diagnosis and treatment are essential to improve the survival rate.

**Keywords:** Merkel cell carcinoma, Neuroendocrine carcinoma of the skin, Skin neoplasms, Polyomavirus

## INTRODUCTION

Merkel cell carcinoma (MCC) was first described in 1972 by Toker, who named it trabecular carcinoma of the skin.<sup>1</sup> In its beginnings, it was thought that this neoplasm developed from glandular tissue. Later, in 1978, the presence of specialized cells was identified, with the presence of intracytoplasmic granules, similar to those observed in Merkel cells, for which it was classified within neuroendocrine carcinomas.<sup>2</sup>

### Epidemiology

The most affected population is the male sex, mainly Caucasian and over 50 years of age.<sup>3</sup> An increase in the incidence of MCC has been reported in recent decades, probably due to the aging of the population or an improvement in early detection. In the United States, the estimated incidence is 1,500 cases per year.<sup>4</sup>

### Risk factors

The recognized risk factors for MCC are exposure to ultraviolet radiation or sunlight, advanced age, and

immunosuppression. It occurs more frequently in the white than in the non-white population (94.9% versus 4.1%). The mean age of diagnose is 73.6 for men and 76.2 years for women. In young patients, the most common risk factor is immunosuppression secondary to solid organ transplantation. Merkel cell polyomavirus infection appears to be related in 80% of cases.<sup>5</sup>

### Clinical features

It typically presents as a fast-growing, firm, painless, shiny, flesh-colored, or bluish-red intracutaneous nodule. Ulceration is rare. The lesions vary in size from less than 1 cm to more than 2 cm and are usually located in areas exposed to the sun.

Harms et al, reported in 2016 a series of cases with 9387 patients with merkel cell carcinoma. The most frequent anatomical locations of primary tumor were: head and neck (43%), upper extremities and shoulders (24%), lower extremities and hips (15%), trunk (11%), and other areas (9%).<sup>6</sup>

## Diagnosis

MCC is often clinically mistaken for a benign lesion. A high index of suspicion is needed to make a timely diagnosis. MCC should be suspected in older patients with fair skin and a painless, fast-growing, or purplish-red nodule.

Heath et al define the most significant clinical characteristics at the time of diagnosis in a series of 195 patients, summarized with the acronym “AEIOU”:<sup>7</sup>

Asymptomatic nodule with lack of tenderness (88%), expanding rapidly (68%), immune suppression (8%), older than age 50 years (90%), UV-exposed site on person with fair skin (81%).

The presence of 3 or more of these features increases the suspicion of merkel cell carcinoma. The diagnosis is confirmed by histopathology of the biopsy or surgical resection.

Histologically, we can find nests of blue, round, uniformly monotonous cells, with the presence of large basophilic nuclei with dispersed powder chromatin, discrete nucleoli, and minimal cytoplasm. Other features reported are unicellular necrosis, frequent mitosis, lymph vascular invasion, perineural invasion, and epidermal involvement due to pagetoid spread.<sup>8</sup>

There are 3 main histological patterns, although clinically insignificant, that must be recognized to avoid being confused with another entity:

*Intermediate type:* More common, characterized by basophilic nuclei with high mitotic activity.

*Small cell type:* Undifferentiated and may be identical to small cell carcinomas from other sites; it is associated with a worse prognosis.

*Trabecular type:* Rare, generally only seen in mixed tumors.

Immunohistochemistry is another fundamental tool in diagnosis. CCMs are positively labelled for low molecular weight cytokeratins (CK8, 18, 19, and 20), while high molecular weight cytokeratins (CK7) are not expressed. It has been reported that in up to 90% of CCM there is a positive expression of CK20 and a negative expression of CK7.

There are neuroendocrine markers such as specific neuronal enolase, which is very sensitive, but not very specific since it is present in other neoplasms (melanoma, other neuroendocrine tumors, and small cell lung carcinoma). Positivity of proteins such as chromogranin and synaptophysin help express typical cytoplasmic staining.<sup>9,10</sup>

## Staging

Currently, the American joint committee on cancer (AJCC) 8<sup>th</sup> edition staging system proposes a classification emphasizing the importance of tumor size, regional lymph nodes, and metastasis. Four clinical stages are described at the time of diagnosis.<sup>11</sup>

**Table 1: Merkel cell carcinoma TNM clinical staging AJCC UICC 8<sup>th</sup> edition.**

Stages	T*	N	M
<b>0</b>	Tis	N0	M0
<b>I</b>	T1	N0	M0
<b>IIA</b>	T2-T3	N0	M0
<b>IIB</b>	T4	N0	M0
<b>IIIA</b>	T1-T4	N1a (sn) o N1a	M0
<b>IIIA</b>	T0	N1b	M0
<b>IIB</b>	T1-T4	N1b-3	M0
<b>IV</b>	T0-4	Any N	M1

\*T1: primary tumor ≤2 cm; T2: primary tumor >2 cm but ≤5 cm; T3: tumor >5 cm; T4: tumor that invades muscle, fascia, cartilage, or bone.

## Treatment

The choice of treatment will depend on the characteristics such as the stage of presentation, location of the tumor, involvement of regional nodes, comorbidities, and functional status of the patient.

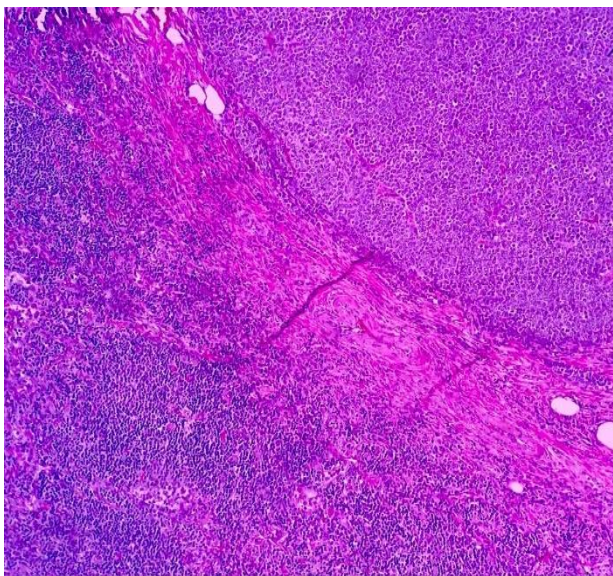
Surgery is the initial treatment for patients with locoregional primary tumors. Wide resection with clinically free margins between 1 and 2 cm is recommended. In case of presenting positive margins, it is necessary to carry out a new division. Mohs microsurgery is reserved for cases in which tissue preservation is necessary, although this technique is controversial, due to the increased risk of developing metastases in transit. In patients with positive nodes, complete lymph node dissection and radiotherapy (RT) should be performed.

RT is considered as adjunctive treatment to surgery or as palliative treatment in cases where surgery is not feasible. There is evidence that adjuvant then radiotherapy decreases the likelihood of recurrence, compared to surgery alone.

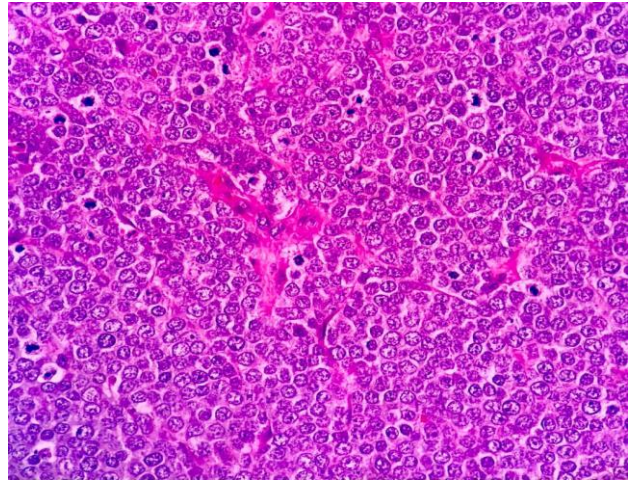
MCC is thought to be sensitive to chemotherapy, but the response is seldom long-lasting. Chemotherapy has been associated with increased morbidity, decreased quality of life, and immunosuppression, with no clear benefit. Mainly, it is reserved for the treatment of metastases (stage IV). The most commonly used regimens include cisplatin or carboplatin, with the etoposide and topotecan.<sup>4</sup>

## CASE REPORT

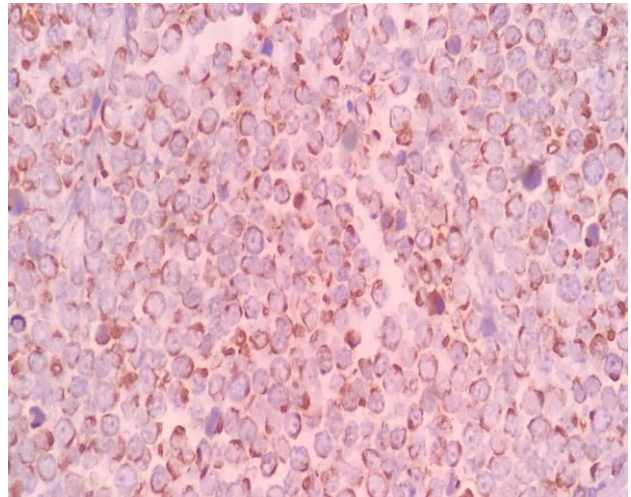
A 74-year-old Caucasian male patient with a personal history of systemic arterial hypertension and a family history of gastric cancer. It presents in the right thigh exophytic neof ormation of 2x1 cm, hemispherical, erythematous-purple color, firm and painful consistency on pressure; non-cancer resection was performed by dermatology with a histopathological report of Merkel cell carcinoma with positive borders (Figure 1-3). He is sent to the surgical oncology service, which performs oncological resection of the lesion and primary closure. The intraoperative histopathological study reports margin-free of tumor lesion. Subsequently, a definitive histopathology report is obtained with microscopic data of neoplastic cells on the surgical bed. Given the aggressiveness of Merkel tumors and the possibility of a microscopically positive bed, neoadjuvant radiotherapy is indicated. After 30 sessions of radiotherapy, the patient presents a progression of the disease, associated with new nodular lesions in the right leg as shown in the Figure 4. Radical treatment with right supracondylar amputation is offered, but the patient does not accept it. He is sent to medical oncology to initiate systemic treatment. After 6 cycles with pembrolizumab, 2 cycles of cisplatin and etoposide, and 2 cycles of doxorubicin and the cyclophosphamide, rapid progression is observed with an extension of generalized tumor lesions in the right pelvic limb as shown in the Figure 5. Local superinfection of the lesions is added (Figures 6 A and B), causing difficulty in walking; at this time the patient accepts radical treatment, and a high right supracondylar amputation is performed as shown in the Figure 7. The latest histopathological study reports tumor-free margins and Scarpa triangle lymph node biopsy with data of Merkel cell carcinoma metastasis.



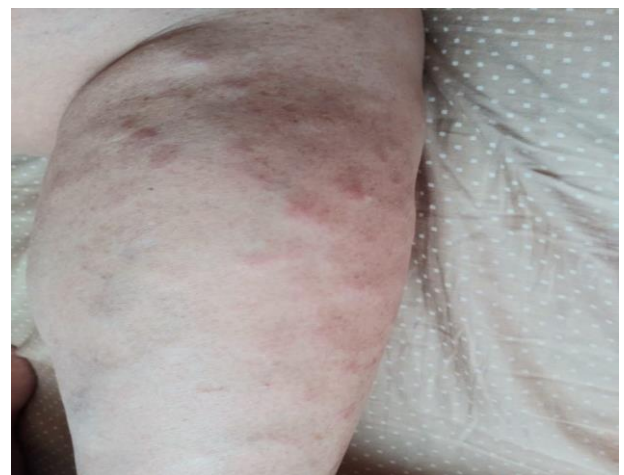**Figure 1: Section of skin stained with hematoxylin and eosin, a dense infiltrate of small rounded cells and hyperchromatic nuclei are observed in the dermis.**



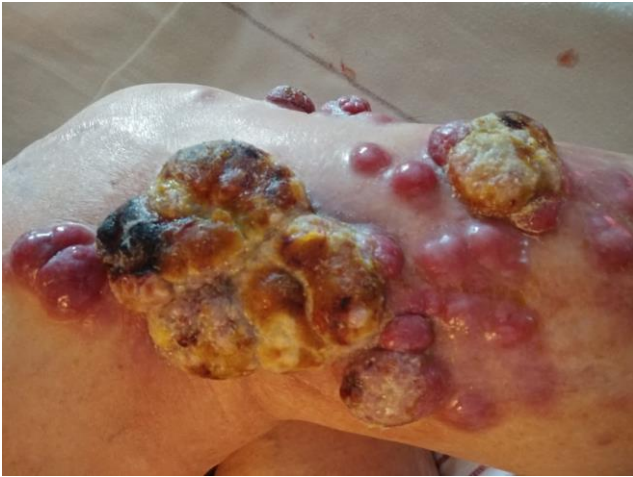**Figure 2: Closer section, with small, rounded, and oval cells of uniform size, hyperchromatic nuclei, with poorly defined cell borders and abundant cytoplasm with the presence of a slight mononuclear infiltrate.**



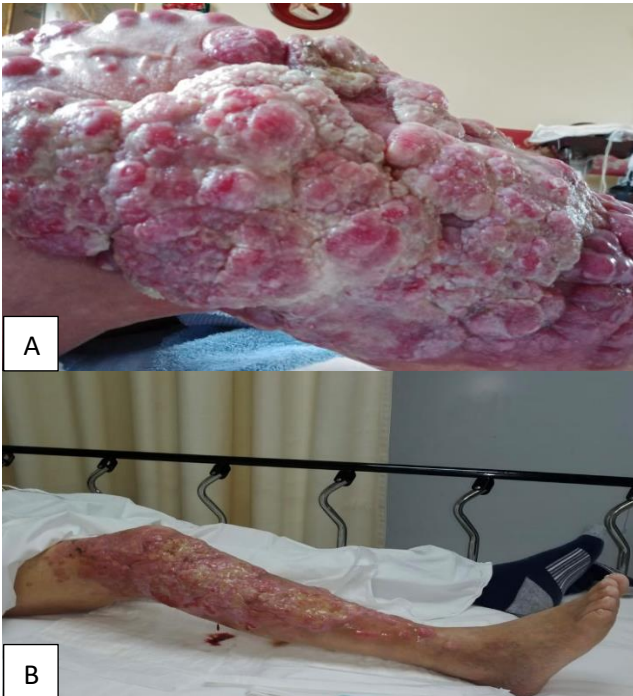
**Figure 3: Tumor cells staining positive for CK20 with a classic pattern of perinuclear dots.**



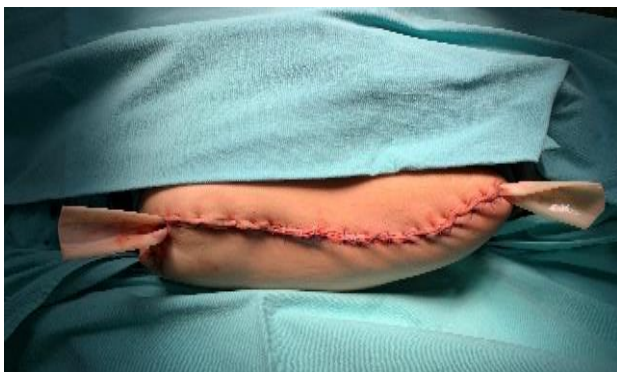**Figure 4: Dermatitis located on the right leg (April 2020).**



**Figure 5: Progression of the disease with neof ormation of nodular appearance (August 2020).**



**Figures 6 (A and B): Local infection and extent of lesions (November 2020).**



**Figure 7: High right supracondylar amputation.**

He is kept under outpatient follow-up, with adequate healing of the surgical site. At the moment, it is not considered benefit to restart radiotherapy/chemotherapy.

## DISCUSSION

We report the case of a patient with stage I Merkel cell carcinoma, without known risk factors, only with Fitzpatrick phototype I is reported. Despite presenting typical clinical and histopathological data of the disease, the anatomical site of the initial injury that the patient presented is rare, as the thigh is an area little exposed to solar radiation, being more frequent in regions such as the face, trunk, and thoracic extremities. About size, most of the cases reported in the literature show lesions of approximately 2 cm, but it is uncommon for an extension so severe that it covers the entire limb, as was reported in case, that even received radiotherapy and chemotherapy.

MCC is a radiosensitive malignancy. The use of radiotherapy as an adjunct or definitive treatment has been reported. Petrelli et al reported a meta-analysis with 17,179 patients, finding that adjuvant radiotherapy significantly improves overall survival (HR 0.81,  $p < 0.001$ ) and reduces the risk of local and regional recurrence by 80% and 70%, respectively. In the case of distant recurrences, no significant difference was found.<sup>12</sup>

Currently, chemotherapy does not have any role in the primary treatment of MCC. Adjuvant chemotherapy in patients with stage I-III does not improve survival and is reserved for palliative treatment in patients with metastases.<sup>13</sup>

## CONCLUSION

MCC is a rare but highly aggressive malignancy. Often the initial injury is inconspicuous, leading to a delay in the patient's seeking medical care and a delayed diagnosis by the primary care physician. A high diagnostic suspicion is required when evaluating an elderly patient with some asymptomatic dermal neof ormation.

The local, locoregional, and distant recurrence rate determines high mortality, reported up to 33-46%.<sup>14</sup> For this reason, early assessment by an oncology service is important to achieve timely and effective treatment, thus improving patient survival.

*Funding: No funding sources*

*Conflict of interest: None declared*

*Ethical approval: Not required*

## REFERENCES

1. Toker C. Trabecular carcinoma of the skin. Arch dermatol. 1972;105(1):107-10.
2. Tang CK, Toker C. Trabecular carcinoma of the skin: an ultrastructural study. Cancer. 1978;42(5):2311-21.

3. Bichakjian CK, Olencki T, Aasi SZ, Alam M, Andersen JS, Blitzblau R et al. Merkel Cell Carcinoma, Version 1.2018, NCCN Clinical Practice Guidelines in Oncology. *J National Comprehensive Cancer Network.* 2018;16(6):742-74.
4. Schadendorf D, Lebbé C, Zur Hausen A, Avril MF, Hariharan S, Bharmal M et al. Merkel cell carcinoma: Epidemiology, prognosis, therapy and unmet medical needs. *Eur J Cancer.* 2017;71:53-69.
5. Amaral T, Leiter U, Garbe C. Merkel cell carcinoma: Epidemiology, pathogenesis, diagnosis and therapy. *Reviews Endocrine Metabolic Disord.* 2017;18(4):517-32.
6. Harms KL, Healy MA, Nghiem P, Sober AJ, Johnson TM, Bichakjian CK et al. Analysis of Prognostic Factors from 9387 Merkel Cell Carcinoma Cases Forms the Basis for the New 8th Edition AJCC Staging System. *Ann Surgical Oncol.* 2016;23(11):3564-71.
7. Heath M, Jaimes N, Lemos B, Mostaghimi A, Wang LC, Peñas PF et al. Clinical characteristics of Merkel cell carcinoma at diagnosis in 195 patients: the AEIOU features. *J Am Academy Dermatol.* 2008;58(3):375-81.
8. Wong HH, Wang J. Merkel cell carcinoma. *Arch pathol lab med.* 2010;134(11):1711-6.
9. Calder KB, Coplowitz S, Schlauder S, Morgan MB. A case series and immunophenotypic analysis of CK20-/CK7+ primary neuroendocrine carcinoma of the skin. *J Cutaneous Pathol.* 2007;34(12):918-23.
10. Llombart B, Requena C, Cruz J. Actualización en el carcinoma de células de Merkel: Epidemiología, etiopatogenia, clínica, diagnóstico y estadificación. *Actas Dermo-Sifiliográficas.* 2017;108(2):108-19.
11. *AJCC Cancer Staging Manual*, 8<sup>th</sup> ed, Springer, New York. 2016;240.
12. Petrelli F, Ghidini A, Torchio M, Prinzi N, Trevisan F, Dallera P et al. Adjuvant radiotherapy for Merkel cell carcinoma: A systematic review and meta-analysis. *Radiotherapy and oncology. J Euro Society for Therapeutic Radiol Oncol.* 2007;134:211-9.
13. Zwijnenburg EM, Lubeek S, Werner J, Amir AL, Weijs W, Takes RP. Merkel Cell Carcinoma: New Trends. *Cancers.* 2021;13(7):1614.
14. Becker JC, Stang A, DeCaprio JA, Cerroni L, Lebbé C, Veness M et al. Merkel cell carcinoma. *Nature reviews. Disease primers.* 2017;3:17077.

**Cite this article as:** Soulé-Martínez CE, Monroy-Ramírez MA, Jaimes-Duran EM, Castellanos-Aguilar L, Ricarte-Almeida ER, Lupián-Angulo AI. Merkel cell carcinoma: a case report and literature review. *Int Surg J* 2021;8:2760-4.