

## Case Report

# Extensive gastric necrosis in an infant

Suraj R. Gandhi, Neha S. Shenoy, Vini Joseph, Apoorva P. Makan, Syamantak Basu,  
Akriti R. Tulsian, Hemanshi S. Shah\*

Department of Pediatric Surgery, TNMC and BYL Nair Hospital, Mumbai, Maharashtra, India

**Received:** 04 June 2021

**Revised:** 10 June 2021

**Accepted:** 30 July 2021

**\*Correspondence:**

Dr. Hemanshi S. Shah,

E-mail: [hemanshishah@gmail.com](mailto:hemanshishah@gmail.com)

**Copyright:** © the author(s), publisher and licensee Medip Academy. This is an open-access article distributed under the terms of the Creative Commons Attribution Non-Commercial License, which permits unrestricted non-commercial use, distribution, and reproduction in any medium, provided the original work is properly cited.

### ABSTRACT

Gastric necrosis is a rare condition, more so in children and can be potentially fatal. The sloughing of the necrosed wall results in perforations or large defects in the gastric wall. We report a rare case of extensive gastric necrosis in a 2 months old female infant, managed successfully. Child presented with non-bilious vomiting and excessive cry. There was history of recurrent upper abdominal distension. X-ray of abdomen showed massive pneumoperitoneum. Intra operatively, posterior gastric wall was sloughed off and lower end of feeding tube was lying in the peritoneal cavity. Necrotic wall was debrided and stomach tube was created from remaining anterior gastric wall. Gastrostomy and jejunostomy was done. Post-operative period was uneventful. Dye study at three months showed good gastric capacity. Stomach being a well vascularised organ, necrosis is rare. There is varied etiology of gastric necrosis, volvulus being one of them. Gastric volvulus might be associated with other congenital anomalies like eventration, asplenia, wandering spleen. The incidence of perforation in gastric volvulus with necrosis is 5-28% and a mortality of 50% is reported with such perforations. Vigilant clinical observation in pediatric patients with upper abdominal distension and pain can point the diagnosis and prevent fatal outcome.

**Keywords:** Gastric, Necrosis, Perforation, Volvulus, Paediatric, Infant

### INTRODUCTION

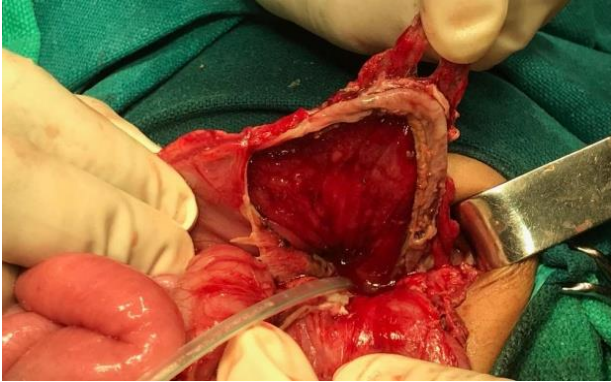
Gastric necrosis is a rare condition, more so in children and can be potentially fatal. Gastric volvulus is one of the major causes of gastric necrosis. The sloughing of the necrosed wall results in perforations or large defects in the gastric wall. Acute or recurrent abdominal pain, upper abdominal distension and chronic vomiting should raise the suspicion of gastric volvulus. Early diagnosis is crucial to prevent life-threatening complications of prolonged volvulus, such as gastric ischemia or infarction, strangulation, necrosis, and perforation. We reported a rare case of extensive gastric necrosis in a female infant, managed successfully.

### CASE REPORT

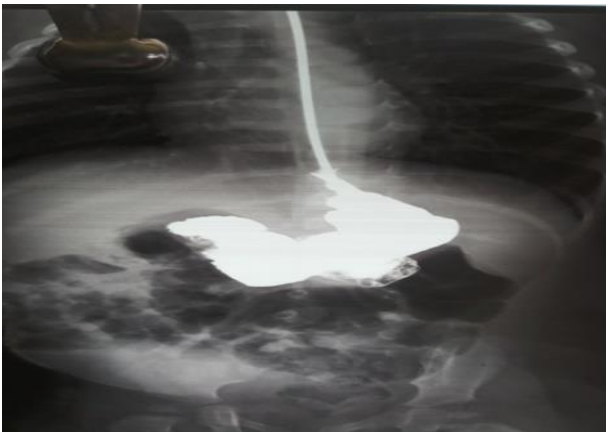A 2 months female presented with non-bilious vomiting,

excessive cry, and fever for 5 days and two episodes of hematemesis. There was history of recurrent upper abdominal distension since birth, which resolved spontaneously. At presentation, the child was in shock with fever and tachycardia. Abdomen was distended with tenderness and guarding in epigastric region. Child was resuscitated with intravenous fluids and antibiotics. Erect X-ray abdomen showed a massive pneumoperitoneum. On emergency exploratory laparotomy, lower end of infant feeding tube was lying freely in the peritoneal cavity. There was contamination in the lesser sac. Posterior gastric wall was sloughed off and a large defect involving 3/4<sup>th</sup> of posterior gastric wall from greater curvature to lesser curvature and from fundus to just proximal to pylorus was present (Figure 1). The necrotic wall was debrided, edges were freshened, gastrostomy was done and stomach tube was fashioned with the anterior wall by single layer interrupted absorbable suture. Feeding jejunostomy was

done. Diaphragm was normal with no other associated abnormalities. Jejunostomy feeds were started after 48 hrs. Contrast study on post-operative day 10 showed no leak. Patient was started on feeds orally and the gastrostomy and jejunostomy tubes were removed. The histopathology revealed gastric necrosis with acute inflammatory infiltration. Contrast study at 3 months depicted a good stomach capacity (Figure 2).



**Figure 1: Extensive gastric necrosis and sloughing.**



**Figure 2: Contrast study at 3 months follow up.**

## DISCUSSION

The stomach is a well-vascularised organ that receives blood supply from the left gastric artery (branch of celiac axis), right gastric artery (branch of the common hepatic artery), right gastroepiploic artery (branch of the gastroduodenal artery), left gastroepiploic artery (branch of the splenic artery) and the short gastric arteries which arise from the splenic artery. Gastric necrosis is uncommon in view of the extensive vascularity.

The reported causes of gastric infarction are diverse and include gastric volvulus, intrathoracic herniation, ingestion of caustic substances, complications after gastric surgery, arterial occlusion by embolus or thrombus, acute necrotizing gastritis and primary gastric mucormycosis.<sup>1-7</sup> Gastric volvulus is defined as rotation of the stomach by more than 180°. On the basis of the axis of rotation,

volvulus can be classified as organoaxial, mesentericoaxial or combined. The organoaxial volvulus is characterized by rotation of the stomach about an axis passing through the gastroesophageal junction and pylorus. Mesentericoaxial volvulus describes rotation about an axis passing perpendicular to the longitudinal axis of the stomach. Organoaxial is more common than mesentericoaxial and represents about two thirds of all gastric volvulus cases. Organoaxial volvulus results in vascular disturbance and gastric necrosis.<sup>1</sup>

Based on etiology, volvulus can be divided into primary (or idiopathic) and secondary. The first being associated with congenital defects such as absence or laxity of the supporting structures of the stomach (gastrocolic, gastrohepatic, gastrosplenic, gastrophrenic ligaments) or abnormal gastric distention; the second is associated with abnormalities of other organs namely eventration, diaphragmatic hernia, wandering spleen or congenital asplenia.<sup>8-11</sup> The double bubble sign, abnormal gastric distension despite the presence of a nasogastric tube, a distended stomach lying in the horizontal plane and a fluid level projecting into the epigastric region on plain radiography is suggestive of gastric volvulus. Upper gastrointestinal contrast study is helpful in diagnosis of chronic organoaxial gastric volvulus. Computed tomography scan can delineate the anatomy more clearly to avoid a delay in diagnosis that can lead to a life-threatening situation.<sup>1</sup>

Gastric perforations are reported in the neonatal age group, in preterm low birth weight babies, secondary to intensive resuscitation procedures.<sup>12</sup> Gastric perforations are rare in older children. The various causes of perforation are trauma, peptic ulceration, gastric volvulus with necrosis and spontaneous onset.<sup>13</sup> The majority of neonatal and paediatric gastric perforations are found on the greater curvature.<sup>14,15</sup> This can be explained by gastric receptive relaxation theory. The greater curvature is the most distensible area of the gastric wall and is prone to ischemic necrosis and resultant perforation. Akalonu et al reported that perforation can also occur at lesser curvature because lesser curvature has reduced elasticity coefficient and greater stretching.<sup>16</sup> The incidence of perforation in gastric volvulus with necrosis is 5-28% and a mortality of 50% is reported with such perforations.<sup>17</sup> In large perforations with extensive gastric necrosis, simple suturing is difficult to perform because of edematous and fragile status of the gastric wall. The fashioning of stomach tube should be accompanied by gastrostomy for effective gastric decompression in post-operative period. The gastrostomy should be from remnant gastric wall and not through the suture line of repair. The gastrostomy tube can also be used for dye study to ascertain calibre of stomach and see for any leak.

## CONCLUSION

In pediatric population, one of the surgical causes of recurrent upper abdominal distension and pain could be

gastric volvulus leading to gastric necrosis and perforation. Vigilant clinical observation can prevent fatal outcome.

*Funding: No funding sources*

*Conflict of interest: None declared*

*Ethical approval: Not required*

## REFERENCES

1. Trecroci I, Morabito G, Romano C, Salamone I. Gastric volvulus in children-a diagnostic problem: two case reports. *J Med Case Rep.* 2016;10:138.
2. Ito TE, Hasnie R, Crosby DL, Milbrandt JC, Ettema S, Duong M. Gastric volvulus complication in an infant with undiagnosed congenital diaphragmatic hernia presenting with acute respiratory distress. *Pediatr Emerg Care.* 2012;28(10):1078-80.
3. Contini S, Scarpignato C. Caustic injury of the upper gastrointestinal tract: a comprehensive review. *World J Gastroenterol.* 2013;19:3918-30.
4. Do PH, Kang YS, Cahill P. Gastric infarction following gastric bypass surgery. *J Radiol Case Rep.* 2016;10(4):16-22.
5. Davoodabadi A, Talari HR, Jahanbakhsh M. Isolated Common Hepatic Artery Branch Thrombosis: Results and Risk Factors. *Acta Med Iran.* 2016;54(9):610-3.
6. Mukhopadhyay M, Saha AK, Sarkar A, Tripathi SN, Biswas S, Mandal D, et al. Gastric gangrene due to necrotizing gastritis. *Indian J Surg.* 2011;73(1):65-7.
7. Kulkarni R, Thakur S. Invasive gastric mucormycosis- a Case Report. *Indian J Surg.* 2015;77:87-9.
8. Shukla RM, Mandal KC, Maitra S, Ray A, Sarkar R, Mukhopadhyay B, et al. Gastric volvulus with partial and complete gastric necrosis. *J Indian Assoc Pediatr Surg.* 2014;19(1):49-51.
9. Gupta V, Chandra A, Gupta P. Diaphragmatic eventration complicated by gastric volvulus with perforation. *S Afr J Surg.* 2012;50:90-1.
10. Krishnakumar G, Mallikarjun U, Reshma D. Massive gastric necrosis with delayed presentation of congenital diaphragmatic hernia- is salvage possible? *Annals Ped Surg.* 2020;16:31.
11. Aoyama K, Tateishi K. Gastric volvulus in three children with asplenic syndrome. *J Pediatr Surg.* 1986;21:307-10.
12. Chen TY, Liu HK, Yang MC, Yang YN, Ko PJ, Su YT, et al. Neonatal gastric perforation: a report of two cases and a systematic review. *Medicine.* 2018;97(17):369.
13. Adachi Y, Takamatsu H, Noguchi H, Tahara H, Mukai M, Akiyama H. Spontaneous rupture of the stomach in preschool age children: a report of two cases. *Surg Today.* 1998;28(1):79-82.
14. Wang K, Cai S, He L, Peng C, Pang W, Wang Z, et al. Pediatric gastric perforation beyond neonatal period: 8-year experience with 20 patients. *Pediatr Neonatol.* 2019;60(6):634-40.
15. Libeer F, Vanhamel N, Huyghe M, Verlinden E. Spontaneous gastric rupture in non-neonatal children: A case report. *Acta Chir Belg.* 2007; 107:560-3.
16. Akalonu A, Yasrebi M, Molle Rios Z. Spontaneous gastric perforation in two adolescents. *Am J Case Rep.* 2016;17:694-8.
17. Cribbs RK, Gow KW, Wulkan M. Gastric volvulus in infants and children. *Pediatrics.* 2008;122:752-62.

**Cite this article as:** Gandhi SR, Shenoy NS, Joseph V, Makan AP, Basu S, Tulsian AR, et al. Extensive gastric necrosis in an infant. *Int Surg J* 2021;8:2816-8.