

## Case Report

# A rare case scenario: spontaneous diaphragmatic rupture during labor

Shambhu Nath Agrawal<sup>1</sup>, Amit Verma<sup>1</sup>, Sunil Kedia<sup>1</sup>,  
Amol Padegaonkar<sup>1</sup>, Hari Shankar Mahobia<sup>2\*</sup>

<sup>1</sup>Department of General Surgery, Apollo Hospital, Bilaspur, Chhattisgarh, India

<sup>2</sup>Department of General Surgery, All India Institute of Medical Science, Raipur, Chhattisgarh, India

**Received:** 09 May 2021

**Accepted:** 05 June 2021

**\*Correspondence:**

Dr. Hari Shankar Mahobia,

E-mail: [harimahobia@gmail.com](mailto:harimahobia@gmail.com)

**Copyright:** © the author(s), publisher and licensee Medip Academy. This is an open-access article distributed under the terms of the Creative Commons Attribution Non-Commercial License, which permits unrestricted non-commercial use, distribution, and reproduction in any medium, provided the original work is properly cited.

### ABSTRACT

Diaphragmatic rupture during labor is not a very common presentation and usually occurs in patients with prior history of traumatic chest or abdominal injury or any congenital abnormality. We presented a case of a 29 year old woman who presented with sudden breathing difficulty two days after a full-term delivery by caesarean section. e-FAST scan suggested the presence of a massive pleural effusion over right side. CT scan of chest revealed large rent in right diaphragm with superior migration of liver and hepatic flexure. Patient was taken for emergent surgical intervention, inter costal drainage (ICD) tube was placed and surgical repair was performed, patient was further treated in critical care unit, the patient recovered well and was discharged. Though diaphragmatic hernia rupture during labor are not reported often it is life threatening complication that requires immediate surgical intervention to prevent major complications and mortality.

**Keywords:** Spontaneous diaphragm rupture, Complication post-labor, Management of diaphragmatic rupture

### INTRODUCTION

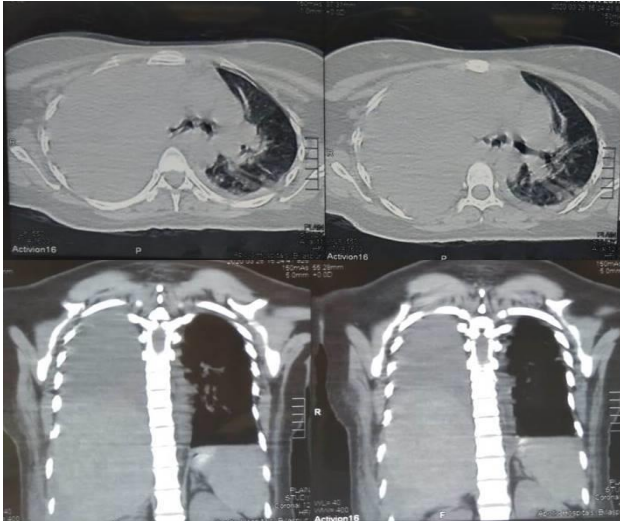
Diaphragmatic rupture may occur due to blunt or penetrating injuries and may present as an acute presentation or delayed as respiratory distress or obstruction.<sup>1</sup> The clinical course varies from person to person but respiratory complaints are commonly seen in most of the patients.<sup>2</sup> Spontaneous rupture of the diaphragm during pregnancy is extremely rare and is associated with high mortality.<sup>3</sup>

An increase in the intra-abdominal pressure caused by an enlarged uterus likely is an exacerbating factor of a pre-existent asymptomatic diaphragmatic hernia.<sup>4</sup> This in an acute condition and requires emergent surgical exploration and intervention.

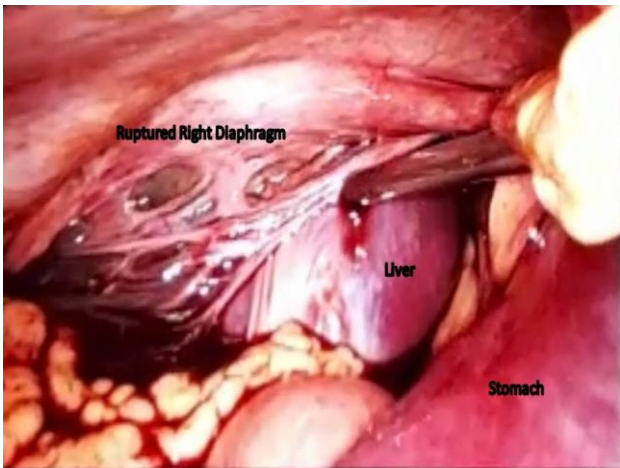
### CASE REPORT

We presented a case of delayed presentation of diaphragmatic rupture in a 29 year old woman who underwent caesarean section at a different healthcare facility 2 days ago. She started complaining of chest pain over right side along with breathing difficulty and coughs, was shifted to our emergency department (ED) due to progression of her symptoms. Upon arrival she was triaged and taken to bed where her vital signs showed a blood pressure of 130/80 mmHg, peripheral pulse of 136 beats per minute, respiratory rate of 40 per minute with oxygen saturation of 86% on air. She was pale, having shortness of breath even at rest. Patient was started on oxygen inhalation, IV lines were secured and all routine blood tests were sent, IV antibiotics and supportive treatment initiated. An e-FAST exam was

done in the ED which revealed massive pleural effusion on the right side and minimal free fluid in abdomen, thus the patient was admitted under respiratory physician. An USG guided pleural tap was attempted, 750 millilitres of haemorrhagic fluid was aspirated and send for routine evaluation. Patient was advised a CT scan of chest which revealed a large rent in the right mid hemi diaphragm with superior migration of liver and hepatic flexure, moderate haemothorax and haemoperitoneum (Figure 2).



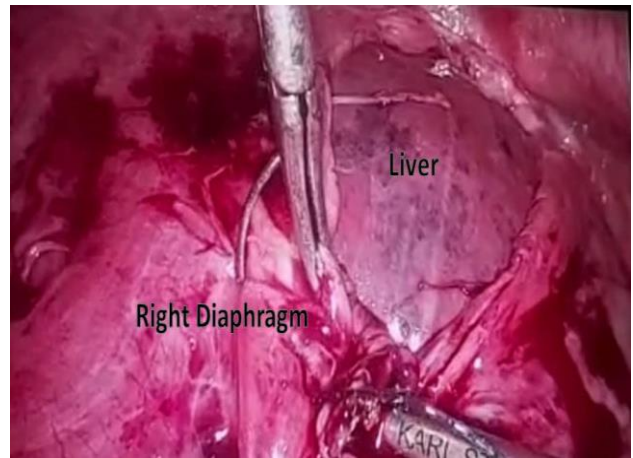
**Figure 1: HRCT thorax showing large rent in the right mid hemi diaphragm with superior migration of liver and hepatic flexure, moderate haemothorax and haemoperitoneum.**



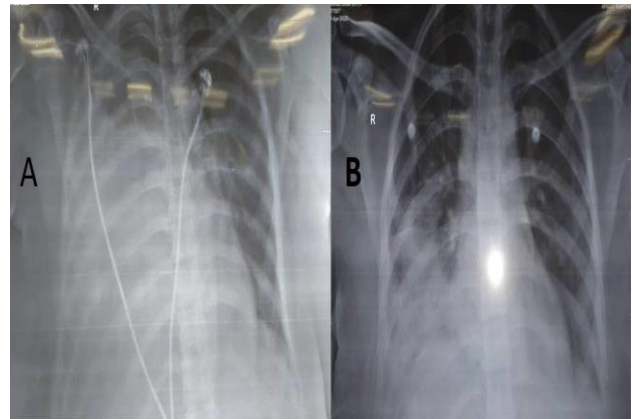
**Figure 2: Intraoperative laparoscopic picture showing ruptured right diaphragm with visible liver in right thoracic cavity.**

Upon discussion the relatives and the previous operating surgeon it was found that the patient had received fundal pressure for getting the fetus out from the uterine cavity during caesarean section, thus the diagnosis of traumatic diaphragmatic tear was made and patient was referred for surgical consultation.

The grave nature of the condition was discussed with the patient, her relatives and was taken immediately to operation theatre. She underwent diagnostic laparoscopy under general anaesthesia (GA). Intra operatively large diaphragmatic hernia over right side along with migration of abdominal contents was seen through the camera port (Figure 2). Other working ports were placed in abdomen and liver along with intestines, omentum was reduced back into the peritoneal cavity. Tear was involving right side of diaphragm, the defect was repaired using v-lock sutures using thoracoscopic ports (Figure 3). Diaphragmatic haemostasis was achieved and ports were closed, peritoneal drain was placed for haemoperitoneum and right inter costal drainage (ICD) tube was placed to drain the hemothorax.



**Figure 3: Thoracoscopic picture during repairing of right diaphragmatic rupture.**



**Figure 4: (A) Preoperative chest X-ray showing right side white out chest; (B) postoperative right sided expanded lung.**

Postoperatively she was shifted to ICU with ventilator support. She was weaned from ventilator support and extubated the next day, chest physiotherapy was started, oral liquids also initiated and tolerated well by the patient. X-ray chest was repeated next day which showed expanded lung (Figure 4). She was shifted to ward, peritoneal drain and ICD were subsequently removed.

Her sutures were removed on day 10 of her hospital stay and she was discharged from the hospital without any complications or disability and was healthy in her follow-up visits.

## DISCUSSION

The major cause of diaphragmatic injury is either by penetrating or blunt injuries to the abdomen. They are mostly diagnosed as part of multi-organ injury or later either with respiratory distress or as intestinal obstruction.<sup>5</sup> Incidence of traumatic diaphragmatic hernia during delivery due to fundal pressure is very rare and it results in a high mortality rate if early surgical intervention is not done. Differential diagnosis of diaphragmatic hernia is a must for both emergency room physicians and trauma surgeons to be ruled out in cases of blunt or penetrative chest and abdominal trauma. Silent diaphragmatic rupture due to previous injuries or congenital defects of the diaphragm have been known to become symptomatic during pregnancy or in the immediate postpartum period but spontaneous rupture of diaphragm during labor is very rare like in our case there was no history of previous injury or congenital defects. As Hamaudi et al described, we also think that spontaneous rupture of the diaphragm probably results from a sudden sharp rise in the intra-abdominal pressure, pushing the diaphragm up and tearing its fibers at the least supported part and increased intra-abdominal pressure during the second stage of labor and application of external pressure to the uterine fundus or the upper abdomen by a traditional birth attendant may have exacerbated a preexistent asymptomatic hernia or perhaps, caused a spontaneous rupture of the diaphragm.<sup>4</sup> Symptoms may vary and most common symptoms are dyspnoea and chest pain and most common sign is decrease auscultation sound in same side. Clinical diagnosis is usually difficult and confusing as in our case, patient was referred to our ED with diagnosis of postpartum sepsis with respiratory distress and suspicion of acute respiratory distress syndrome (ARDS). However correct diagnosis was made by radiography like chest X-ray and CT scan which confirmed the diagnosis of traumatic diaphragmatic hernia with migration of abdominal contents into the thoracic cavity. Immediate surgical intervention is the key factor in decreasing the complication like and cardio and pulmonary, any permanent disability or mortality. Surgical intervention may include open or laparoscopic and trans-abdominal or trans-thoracal approach or may combined. As per our

experience best approach should be a diagnostic laparoscopy need to be done followed by depending on finding. The trans-abdominal approach enables good access to herniated parenchymal organs such as liver and spleen. However, the trans-thoracal approach in longer lasting hernias to treat pleuroperitoneal adhesions.<sup>6</sup> A complete laparoscopic repair is also possible as we had done in our case. We used combine laparoscopic for reducing abdominal content and thoracoscopic for repair of rupture diaphragm.

## CONCLUSION

Though diaphragmatic hernia rupture during labor are not reported often it is life threatening complication that requires immediate diagnosis and prompt surgical intervention require to prevent major complications like cardio and pulmonary complications or any permanent disability or mortality.

*Funding: No funding sources*

*Conflict of interest: None declared*

*Ethical approval: Not required*

## REFERENCES

1. Cameron J, Cameron A. Diaphragmatic injury. Current Surgical Therapy. Philadelphia, PA: Mosby-Elsevier; 2008: 975-87.
2. Graivier L, Freeark RJ. Traumatic diaphragmatic hernia. Archiv Surg. 1963;86(3):363-73.
3. Osman I, McKernan M, Rae DW. Normal vaginal delivery following rupture of the maternal diaphragm in pregnancy. J Obstet Gynaecol. 2007;27(6):625-7.
4. Hamoudi D, Bouderk MA, Benissa N, Harti A. Diaphragmatic rupture during labor. Int J Obstet Anesth. 2004;13(4):284-6.
5. Shah R, Sabanathan S, Mearns AJ, Choudhury AK. Traumatic rupture of diaphragm. Ann Thoracic Surg. 1995;60(5):1444-9.
6. Myers BF, McCabe CJ. Traumatic diaphragmatic hernia: occult marker of serious injury. Ann Surg. 1993;218(6):783-90.

**Cite this article as:** Agrawal SN, Verma A, Kedia S, Padegaonkar A, Mahobia HS. A rare case scenario: spontaneous diaphragmatic rupture during labor. Int Surg J 2021;8:2241-3.