

Original Research Article

Total laparoscopic pancreaticoduodenectomy in 26 patients: single surgeon experience

Rajendra Bagree¹, Gaurav Jalendra^{1*}, Pradeep Panwar¹,
Veena Shukla², Hetish M. Reddy¹

¹Department of Surgery, ²Department of Anaesthesia, S.M.S. Medical College and attach group of Hospitals, Jaipur, Rajasthan, India

Received: 17 November 2020

Revised: 13 January 2021

Accepted: 15 January 2021

***Correspondence:**

Dr. Gaurav Jalendra,

E-mail: gauravjalendra004@gmail.com

Copyright: © the author(s), publisher and licensee Medip Academy. This is an open-access article distributed under the terms of the Creative Commons Attribution Non-Commercial License, which permits unrestricted non-commercial use, distribution, and reproduction in any medium, provided the original work is properly cited.

ABSTRACT

Background: Total laparoscopic pancreaticoduodenectomy (TLPD) has become more feasible and preferred surgery for periampullary tumour. With the innovation of latest equipment and continuous learning curve, this has become more sophisticated and rampant, along the advantages of minimal invasive surgery.

Methods: We analysed data of all the 26 patients who underwent TLPD from October 2015 to November 2019. Preoperative haematological, liver function test, tumour marker, MRCP, triphasic CT, scan with pancreatic protocol, endoscopic ultrasound guided fine needle aspiration or brush cytology done for confirmation of diagnosis, nodal status and operability. Meticulously selected patients with periampullary carcinoma of tumour size ≤ 2.5 cm included. Demographic data, operative time, length of hospital stay, post-operative complication and pathological analyses of resected specimen (en bloc) observed.

Results: TLPD for periampullary tumours attempted in twenty-six patients among them six converted to open surgery. Patients were of both genders and mean age was 45 (27-60, SD7.4) years. The mean operative time was 353 SD 28.77 (306-420) minutes. Postoperatively, there were few complications and mean length of hospital stay was 11 (9-13 days) days. The histopathology revealed maximum no. of cholangiocarcinoma with negative margins and positive nodes in all the patients.

Conclusions: TLPD is feasible, safe and promising alternative to the standard open surgery with expert hands. This has benefits of short hospital stay, less blood loss, cosmetic, early recovery with few complications. Short-term surgical outcomes are superior or comparable to open surgery.

Keywords: Total laparoscopic pancreaticoduodenectomy, Periampullary tumour, Adenocarcinoma, Pancreas, Learning curve, Minimal invasive surgery

INTRODUCTION

Periampullary carcinoma (PAC) accounts for 3-4% of gastrointestinal (GI) tract malignancies. It comprises of pancreatic head, ampulla of vater, distal common bile duct, and duodenal cancer. The incidence of PAC in India is low (0.5-2.4 per 100,000 in men and 0.2-1.8 per 100,000 in women).¹ There are varieties of neoadjuvant

and adjuvant treatment protocols but the potential curative choice for PAC is surgical resection. Gagner and Pomp in 1994 first introduced Total laparoscopic pancreaticoduodenectomy (TLPD/whipple procedure) since then with advancement in surgical instruments, innovation and surgeon's learning curve TLPD though very challenging and advanced surgery is now considered feasible and safe.²

The objective of this study was to share our experience with TLPD in 26 patients of PAC in terms of feasibility and short-term surgical outcomes, with the advantages of less blood loss and requirement of transfusion, minimal post-operative pain, shorter hospital stay and ICU care.

METHODS

Patient selection

This was a hospital based observational study conducted at Sawai Man Singh Medical College, Jaipur, Rajasthan. Inclusion criteria was (1) periampullary tumour of size <2.5 centimetres (2) patients with confirmed resectability of tumour based on endoscopic and radiological assessment, without vascular invasion. According to inclusion criteria we included 26 patients registered under GI clinic, from October 2015 to November 2019 by a single surgeon at Department of Surgery. Exclusion criteria was (1) carcinoma with vascular invasion (2) history of previous abdominal surgery (3) unfit for general anaesthesia (4) Not giving consent for laparoscopic surgery. For statistical work (i.e., mean, standard deviation, range and tabulation) Microsoft Excel and Med Calc Statistical Software version 14.8.1 (MedCalc Software bvba, Ostend, Belgium; <http://www.medcalc.org>; 2014) was used.

Mean age was 45 years (range 27-60 SD 7.4). More number of patients were in age group 50-54 years (n=8, 30.7%). Man:woman ratio was 18:8.

Preoperative work up-complete clinical evaluation with standard routine investigations (hemogram, coagulation profile, universal viral marker, LFT, RFT and urine examination), chest X-ray (PA view), electrocardiography and tumour marker CA 19-9 done. All patients underwent Triple phase computerized tomography (TPCT) scan, Magnetic resonance cholangiopancreatography (MRCP), endoscopic ultrasonography (EUS) guided FNAC or brush cytology were selectively performed based on tumour location and type.

For optimization of co morbidities, multi-disciplinary approach was taken. Preoperative liver function test except bilirubin level were within optimal range. Patients with bilirubin >10 mg/dl were subjected to ERCP and Stenting preoperatively. Fourteen patients underwent ERCP and Stenting. CA 19-9 was estimated preoperatively for all patients.

Procedure

After adequate preoperative optimization of all the patients, patients shifted to the advanced laparoscopic OT. Taking all aseptic precautions, patients positioned modified french position under general anesthesia.

Five/six access ports created. Operating surgeon stood in between the patient's legs. The camera assistant typically positioned himself behind the operating surgeon, like hugging him from behind. Further one assistant was positioned on either side of the table and the scrub nurse to the operating surgeon's left.

Using direct trocar insertion technique, a 10 mm port was placed midway between the xiphoid process and umbilicus. Pneumo-peritoneum was created. Resectability was confirmed by diagnostic laparoscopy. Additional ports were placed as in (Figure 1).

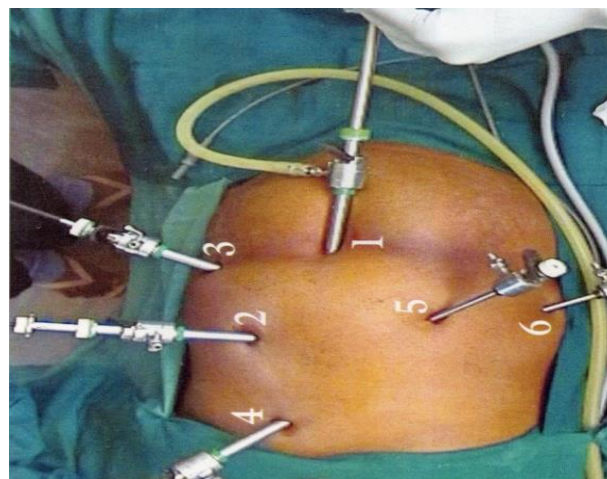


Figure 1: Port placement.

(1) camera-umbilicus 10 mm (2) right hand working port (specimen retrieval port) – left epigastrium 12 mm (3) working port– left midclavicular 10 mm (4) retracting port – subxiphoid 10 mm (5) left hand working port – right mid clavicular 5mm (6) retracting port (Rarely used) – right anterior axillary port 5 mm

The lesser sac was entered by taking the greater omentum off the transverse colon, and the loose attachments of the posterior gastric wall to the anterior surface of pancreas were also released. The hepatocolic ligament was then divided to lower the hepatic flexure of the colon using vessel sealer up to the hilum of the right kidney. A Kocher maneuver was then performed upto the level of the ligament of Treitz. The hepatoduodenal ligament was dissected and gastroduodenal artery was isolated from the hepatic artery and doubly ligated with 0 silk sutures and divided. The proximal duodenum was then divided at the pyloro-duodenal junction by an Endo GIA stapler.

After that gall bladder was dissected from liver surface with fundus first technique followed by Calot's triangle dissection and cystic artery ligation. Cystic duct was not divided so that later gall bladder can be removed en-bloc. Next, the common bile duct (CBD) was mobilized and divided at the level of common hepatic duct, after placing two stay sutures to the CHD. The following step was the most crucial and technically the most challenging part of this procedure. The pancreas was dissected from the portal vein posteriorly, and a tunnel between the pancreas

and portal vein was created in an inferior to superior direction by skillful blunt dissection. Umbilical tape was used as sling to lift the pancreas, anteriorly away from the underlying portal vein, and the pancreas was subsequently divided using ultrasonic shears at the level of pancreatic neck, fringe by fringe. Then the inferior pancreaticoduodenal artery was ligated. Then the uncinata process was dissected and released, clipping and sealing of the vessels as necessary using a harmonic scalpel, vessel sealer or hemostatic clips as required.

The main pancreatic duct (MPD) was then identified and cannulated with 8Fr or 6Fr infant feeding tube. The jejunum was divided approximately 15 cms distal to the ligament of Treitz using an Endo GIA stapling device and its mesentery was divided down to its origin in the duodenal fossa. Surgical specimen was placed in an endobag and parked behind the right lobe of liver. Resecting the specimen en-bloc with peri-portal, peri-pancreatic, peri-duodenal nodes was the key step. Achieving hemostasis was always of prime importance at every step before proceeding.

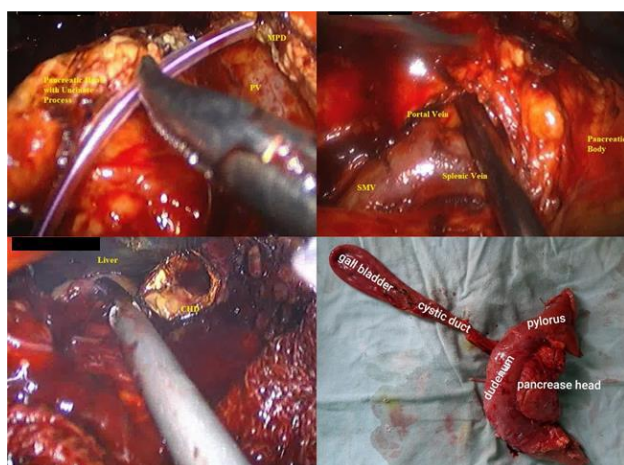


Figure 2: Intra-operative images and specimen.

After complete resection, the reconstruction was started. All the anastomoses except gastro-jejunosomy (GJ), were done by intracorporeal suturing. In this study we did either pancreaticogastrostomy (PG) or pancreato-jejunosomy (PJ) for the pancreatic anastomosis. For PJ, the transected end of jejunum was anastomosed with pancreatic duct in a double layered, interrupted, duct to mucosa, end to side technique with PDS 4-0 using infant feeding tube as a stent in pancreatic duct. Stent was retrieved after taking the last bite of suture. In cases where PG was done, an end to side anastomosis was done with posterior layer of stomach at the site of topographically vicinity, in a double layered, interrupted, duct to mucosa technique with PDS 4-0 using infant feeding tube as a stent in the pancreatic duct. Then approximately 15 cm distal to PJ/PG, single layered, interrupted duct to mucosa hepaticojejunosomy (HJ) was done by PDS 3-0. Then gastrojejunosomy (GJ) was done about 30cm distal to HJ using endo GIA stapler and

hemostasis was ensured. Finally, two drains were placed, one at the Morrison's pouch and one in the pelvic cavity. The specimen was extracted by enlarging right hand 12 mm working port with necessary incision. A feeding jejunostomy (FJ) was done, with 14F Ryle's tube extracorporeally after delivering a jejunal loop from the specimen delivery incision. A nasogastric tube was placed for decompression and drainage of the stomach. All the patients were shifted to intensive care unit for observation after surgery.

Post-operative information

All patients were observed in ICU postoperatively. Octreotide 200mcg loading dose followed by 100mcg subcutaneously twice daily for 7 days was administered to all patients starting from post-operative day 0. Priming of FJ in all cases with the normal saline was done on POD 2. We used broad spectrum combination of IV antibiotics for 10 days. Parenteral nutrition was started on the 2nd day of surgery and continued until oral feeds initiated. Hematological and biochemical parameters were assessed every day. We analyzed the drain fluid for amylase on day 5, 7 and 10. Three patients had shown minimal amount of bile (<100 ml) content in drain and managed conservatively.

Patients offered orally with liquid diet between day 5 and 9 followed by diet advancement. Average length of hospital stay was between 9 to 13 days (mean 11.1 days). There was anastomotic bleed (Haematemesis) in five cases, wound infection in 5 cases, intra-abdominal collection in 4 cases and pancreatic fistula in 5 cases, all managed conservatively.

One patient was re-admitted for bleeding while receiving anticoagulation therapy for history of pre-existing condition but did not require any additional procedural therapy, and the issue resolved. Another patient admitted for post-operative obstruction, which was treated conservatively. There were four mortalities in perioperative period.

The patients were referred to oncologist for further management as per the histopathology findings. Most of the patients were in follow up for periods up to 1 month.

Pathological diagnosis

On pathological evaluation, there was no lymph node involvement in all specimens. Pathologic findings included ductal adenocarcinoma in 8 patients (R0), an ampullary adenocarcinoma in 2 patients (R0), cholangiocarcinoma in 15 patient (R0) and chronic pancreatitis in 1 patient.

Average number of harvested lymph nodes in specimen were 21.9. After discharge from surgery side all patients sent for oncological interventions and further adjuvant therapy.

RESULTS

TLPD were performed in 26 patients during October 2015 to November 2019 with the suspicion of PAC by a single surgeon.

Patients were meticulously selected with tumour size ≤2.5cm (1.2-2.5cm). Mean age was 45 years (range 27-60 years) and commonest age was 50-54 years. There

was male preponderance of disease shown with Man to Woman ratio of 18:8 in our study.

Mostly patients had CA19-9 levels raised with a range of 60-295 U/ml. Liver function test were in optimal levels except bilirubin levels which were high (average 10.07 SD3.12 mg/dl). ERCP and stenting was done preoperatively in 14 patients who had TB>10 mg/ml. Patients presented with co morbidities also but mostly ASA grade 2 and 3 were selected.

Table 1: Preoperative clinical data.

Tests	Mean	SD	Range
Preoperative CA 19-9 (U/ml)	160.9231	66.29867	60-295
Preoperative TB (mg/dl)	10.07692	3.123115	2-15
Preoperative ERCP and stenting	14	53.8%	
Tumour size (cm)	1.61	0.27	1.2-2
Preoperative initial symptoms			
Jaundice with/without pruritus	18	69.2%	
Epigastric pain and distension	15	57.7%	
Fever	1	3.8%	
Without any symptom	1	3.8%	
Co morbidities			
Hypertension	4	15.4%	
Diabetes	3	11.5%	
Diabetic and hypertensive	3	11.5%	
Aortic Stenosis	1	3.8%	
ASA Grade			
2	15	57.7%	
3	11	42.3%	

*TB-total bilirubin, ** ERCP – Endoscopic retrograde cholangiopancreatography

TLPD approach was implied in all 26 patients but 6 patients (23%) were converted to OPD due to uncontrolled bleeding resulting from adhesion of tumour to portal vein (n=2), poor chest conditions (n=2) and tumour adhesion (n=2). Pancreaticogastrostomy (n=22) and pancreatojejunostomy (n=4) was done.

Mean operative time was observed to be 353.77 SD28.77 min (306-420 min). Two patients needed intraoperative blood transfusion and estimated average blood loss was 230 SD111.9 ml (118-550ml). Margin negative resection was done in all 26 patients (Table 2).

FJ priming was done in all cases usually began between day 4-5. patients were started orally with liquids between day 5-9 followed by diet advancements. Average length of hospital stay was 9-13 days (11.1 days).

We faced few post-operative complications like anastomosis bleed (Haematemesis) (n=5), surgical site infection (n=5) pancreatic fistula (n=5), intra-abdominal collection (n=4). These complications were also graded according to clavien-dindo classification.3 (Table 3) More complications were seen in PJ candidates. We lost 4 patients in perioperative period between 6-9 days due to septicaemia and cardio- respiratory collapse. One patient

with intestinal obstruction and another with bleeding with pre-existing anticoagulation therapy were re- admitted and managed conservatively.

The pathological findings with the harvested lymph nodes and specimen revealed ductal adenocarcinoma R0 (n=8), cholangiocarcinoma (n=15) R0, ampullary adenocarcinoma (n=2) R0 and chronic pancreatitis (n=1). Average numbers of harvested lymph nodes were 21.9.

Table 2: Intra- operative information and post-operative complications.

Pancreatojejunostomy (PJ)	4	
Pancreaticogastrostomy (PG)	22	
Conversion to OPD	6	
Operative time (minutes)	353.77 SD28.77	306-420
Transfusion required	N=2 (1 unit)	7.7%
EBL (millilitres)	230 SD111.98	118-550
Margin- negative resection	26	100%

*EBL–estimated blood loss; OPD–open pancreaticoduodenectomy

Table 3: Morbidity and mortality according to clavien-dindo classification.

Variables			%
Anastomotic bleeding (Haematemesis)	5	4, CD Grade-2	15.3
		1, CD Grade-5	3.8
Wound infection	5	2, CD Grade-2	7.7
		3, CD Grade-3a	11.5
Intra-abdominal collection	4	3, CD Grade-2	11.5
		1, CD Grade-3a	3.8
Pancreatic fistula	5	5, CD Grade-2	19.2
Re-admission	2		7.7
Re-operation	0		0.0
30-day mortality	4	4, CD Grade-5	15.4

*CD grade- clavien-dindo classification grade

DISCUSSION

TLPD is considered as most challenging and difficult procedure, demanding skilfulness and expertise in minimal invasive techniques for dissection around major blood vessels and complex anastomosis.

With the recent technical advancements and implementation of previous solid experience of the surgeon in this field, minimally invasive approach for pancreatic carcinoma resection has gained popularity due to benefits of less blood loss and transfusion, less pain, cosmesis, early recovery with less hospital stay facilitate for early start of adjuvant therapy.^{4,5}

Varies authors have compared oncologic advantages of TLPD over open approaches in pancreatic ductal adenocarcinoma. They have stated that this is a feasible and safe procedure with all the benefits of laparoscopic surgery with optimal oncologic outcomes. Patients showed longer progression free survival than those undergone open pancreaticoduodenectomy (OPD). Reason could be physiologic impact of laparoscopic approach with decreased immune suppression and stress response, which enhances timely received adjuvant therapy in TLPD patients.^{6,7}

This study also correlates with other studies in view of less blood loss, minimal hospital stays and early recovery. There was early initiation of oral diet too.

Many published studies showed mean operative time for TLPD range between 287 to 510 min. C Kendrick and Zureikat described the consistent trend of decreasing operative time with increasing experience with TLPD, the standardization of the operative procedures, and the better tuning among the surgical team.^{8,9} Our study data showed mean operative time of 360 min, which is less than the previously reported values. A study from the American college of surgeons national surgical quality improvement program (NSQIP) concluded that longer operative times were independently associated with worse perioperative outcomes after pancreatic

resections.¹⁰ Therefore, we believe long duration is a definite disadvantage of TLPD.

The real nightmare of the surgeon after pancreatic resection is postoperative pancreatic fistula (POPF) which is life threatening complication leads to prolong hospital stay with increased economic burden to the patient. The reported incidence after OPD ranges from 2.0 to 36.0 %, while the reported incidence after TLPD ranges from 0 to 35.0 %.¹¹⁻¹³

Various studies showed that pancreatic leak and fistula formation could be reduced by selective pancreatic duct ligation, two- layer end to side pancreatojejunostomy anastomosis rather than two- layer duct to mucosa anastomosis while Bassi et al. showed no significant differences between these two methods in regard to the incidence of POPF.^{11,14-16}

Our observations showed POPF after TLPD occurred in five out of 26 patients (19.2%) though all patients underwent two-layer duct-to-mucosa anastomosis, and the pancreatic stump was routinely over-sewn for the purpose of haemostasis. They were treated conservatively.

However, role of drain is controversial in other studies, we placed two drains in all cases. According to published articles they used drain only in case of soft pancreas and pancreatic duct < 3 mm.⁸

Delayed gastric emptying (DGE) also encounter prolongation of recovery time, usually managed conservatively by reinsertion of NGT and partial parenteral nutrition. Much debate over pylorus-preserving pancreaticoduodenectomy (PD) and classic PD as the cause of DGE, but not significant difference is found.¹⁷ In our study no delayed gastric emptying was observed as pylorus was not preserved. Delayed gastric emptying (DGE) is not frightening complication, but can impact significant aftermaths such as prolonged hospital stays, diminished nutritional status, and delays in initiation of adjuvant therapy.^{18,19}

Post pancreatectomy haemorrhage (PPH) may increase mortality following resection of pancreas. This may originate from leak anastomosis, vessels, pancreatic stump, stress ulcers etc. Incidences are shown in range of 11.0-38%. Haemorrhage are seen as frank blood in drains or NGTs, hematemesis or melena associated with hypotension or tachycardia, and a decreasing haemoglobin concentration. 20 Recent studies showed the incidence of PPH varies from 7.0 to 9.4 % after TLPD.^{6,21}

In the present study, five patients (19.2%) developed PPH due to active bleeding from the gastrojejunal anastomotic stoma. Among them four patients managed with blood transfusion and PPI. One patient underwent exploratory laparotomy and haemostatic sutures were taken on anastomotic site.

Sometimes TLPD cases need to be converted in OPD due to adherence of tumour, positive margins, intractable bleeding, restricted operative field and other unexpected events. Conversion rates are variable as a reflection of learning curve ranging from 0-43%, though it is naïve to infer.^{22,23}

Rather than to show over enthusiasm to do TLPD, preoperative assessment for selection of right candidate is must. Prior CT, MRI, EUS and octreotide receptor scintigraphy are essential tools to judge resectability of tumour through laparoscopic approach.

In our case series, six patients (23.0 %) required conversion because of uncontrolled bleeding resulting from adhesion of the tumour to the portal vein (n=2, 7.6 %), poor chest conditions cannot tolerate pneumoperitoneum (n=2, 7.6 %) and tumour adhesion (n=2, 7.6%).

Oncological outcomes of pancreaticoduodenectomy, R0 resection rates and harvesting of lymph nodes numbers done via open or laparoscopically are comparable.^{20,24,25}

In our study, all margins were negative of resected specimen and average lymph nodes harvested were.²¹ These nodes were more than sufficient to prove adequate sampling with TLPD. Oncological products can be harvested as efficiently with laparoscopic approach as by open by a competent surgeon.

TLPD, procedure from the practical lookout, laparoscopic experience, with ideal instruments and devices i.e. ultrasonic dissector and endoscopic endostapler, resection of duodenum or stomach, dissecting and transecting the pancreas and performing gastrojejunostomy is safe and could be accomplished rapidly. Several limitations of this study need not to be mentioned as done by a single surgeon with limited resources.

CONCLUSION

In summary, we observed that Total laparoscopic pancreaticoduodenectomy is reasonable and technically feasible for the treatment of periampullary tumours in highly selected patients. This provides superior benefits of minimal invasive surgeries with acceptable oncological outcomes with cautious patient assortment. Certainly, this study was restricted by its small sample size and the short follow-up time. Therefore, randomized, comparative studies with large sample sizes are mandatory to make standard suppositions regarding the role of total laparoscopic pancreaticoduodenectomy.

Funding: No funding sources

Conflict of interest: None declared

Ethical approval: The study was approved by the Institutional Ethics Committee

REFERENCES

1. Gupta, R., & Bansal, J. Pancreatic Cancer Research in India: A Scientometric Assessment of Publications during 2007-16. 2018;12.
2. Gagner M, Pomp A. Laparoscopic pylorus-preserving pancreatoduodenectomy. Surg Endosco. 1994;8(5):408-10.
3. Clavien PA, Barkun J, de Oliveira ML, Vauthey JN, de SE, Pekolj J, et al. The Clavien-Dindo classification of surgical complications: five-year experience. Ann Surg. 2009;250(2):187-96.
4. Jacobs MJ, Kamyab A. Total laparoscopic pancreaticoduodenectomy. J Soc Laparoendosco Surgeo. 2013;17(2):188.
5. Sharpe SM, Talamonti MS, Wang CE, Prinz RA, Roggin KK, Bentrem DJ, et al. Early national experience with laparoscopic pancreaticoduodenectomy for ductal adenocarcinoma: a comparison of laparoscopic pancreaticoduodenectomy and open pancreaticoduodenectomy from the National Cancer Data Base. J Am Col Surg. 2015;221(1):175-84.
6. Croome KP, Farnell MB, Que FG, Reid-Lombardo K, Truty MJ, Nagorney DM, et al. Total laparoscopic pancreaticoduodenectomy for pancreatic ductal adenocarcinoma: oncologic advantages over open approaches?. Ann Surg. 2014;260(4):633-40.
7. Burpee SE, Kurian M, Murakame Y, Benevides S, Gagner M. The metabolic and immune response to laparoscopic vs open liver resection. Surg Endosco Other Intervent Techni. 2002;16(6):899-904.
8. Kendrick ML, Cusati D. Total laparoscopic pancreaticoduodenectomy: feasibility and outcome in an early experience. Arch Surg. 2010;145(1):19-23.
9. Zureikat AH, Breaux JA, Steel JL, Hughes SJ. Can laparoscopic pancreaticoduodenectomy be safely

- implemented?. *J Gastrointest Surg.* 2011;15(7):1151-7.
10. Maggino L, Liu JB, Ecker BL, Pitt HA, Vollmer Jr CM. Impact of operative time on outcomes after pancreatic resection: a risk-adjusted analysis using the American College of Surgeons NSQIP Database. *J Am Col Surg.* 2018;226(5):844-57.
 11. Mabrut JY. Hepatobiliary and pancreatic section (HBPS) of the Royal Belgian Society of Surgery; Belgian Group for Endoscopic Surgery (BGES); Club Coelio. Laparoscopic pancreatic resection: results of a multicenter European study of 127 patients. *Surgery.* 2005;137:597-605.
 12. Gagner M, Pomp A. Laparoscopic pancreatic resection: is it worthwhile?. *J Gastrointest Surgery.* 1997;1(1):20-6.
 13. Bao PQ, Mazirka PO, Watkins KT. Retrospective comparison of robot-assisted minimally invasive versus open pancreaticoduodenectomy for periampullary neoplasms. *J Gastrointest Surg.* 2014;18(4):682-9.
 14. Bilimoria MM, Cormier JN, Mun Y, Lee JE, Evans DB, Pisters PW. Pancreatic leak after left pancreatectomy is reduced following main pancreatic duct ligation. *Brit J Surg.* 2003;90(2):190-6.
 15. Berger AC, Howard TJ, Kennedy EP, Sauter PK, Bower-Cherry M, Dutkevitch S, et al. Does type of pancreaticojejunostomy after pancreaticoduodenectomy decrease rate of pancreatic fistula? A randomized, prospective, dual-institution trial. *J Am Col Surgeo.* 2009;208(5):738-47.
 16. Bassi C, Falconi M, Molinari E, Mantovani W, Butturini G, Gumbs AA, et al. Duct-to-mucosa versus end-to-side pancreaticojejunostomy reconstruction after pancreaticoduodenectomy: results of a prospective randomized trial. *Surgery.* 2003;134(5):766-71.
 17. Horstmann O, Markus PM, Ghadimi MB, Becker H. Pylorus preservation has no impact on delayed gastric emptying after pancreatic head resection. *Pancreas.* 2004;28(1):69-74.
 18. Akizuki E, Kimura Y, Nobuoka T, Imamura M, Nagayama M, Sonoda T. Reconsideration of postoperative oral intake tolerance after pancreaticoduodenectomy: prospective consecutive analysis of delayed gastric emptying according to the ISGPS definition and the amount of dietary intake. *Ann Surg.* 2009;249(6):986-94.
 19. Marsh RD, Talamonti MS, Katz MH, Herman JM. Pancreatic cancer and FOLFIRINOX: a new era and new questions. *Canc Med.* 2015;4(6):853-63.
 20. Wente MN, Veit JA, Bassi C, Dervenis C, Fingerhut A, Gouma DJ, et al. Postpancreatectomy hemorrhage (PPH)—an international study group of pancreatic surgery (ISGPS) definition. *Surgery.* 2007;142(1):20-5.
 21. Asbun HJ, Stauffer JA. Laparoscopic vs open pancreaticoduodenectomy: overall outcomes and severity of complications using the Accordion Severity Grading System. *J Am Col Surgeo.* 2012;215(6):810-9.
 22. Boggi U, Amorese G, Vistoli F, Caniglia F, De Lio N, Perrone V, et al. Laparoscopic pancreaticoduodenectomy: a systematic literature review. *Surgic Endosc.* 2015;29(1):9-23.
 23. Staudacher C, Orsenigo E, Baccari P, Di Palo S, Crippa S. Laparoscopic assisted duodenopancreatectomy. *Surgic Endosc Intervent Techniq.* 2005;19(3):352-6.
 24. Wang M, Zhang H, Wu Z, Zhang Z, Peng B. Laparoscopic pancreaticoduodenectomy: single-surgeon experience. *Surgic Endosco.* 2015;29(12):3783-94.
 25. Menon KV, Hayden JD, Prasad KR, Verbeke CS. Total laparoscopic pancreaticoduodenectomy and reconstruction for a cholangiocarcinoma of the bile duct. *J Laparoendosc Advanc Surg Techniq.* 2007;17(6):775-80.

Cite this article as: Bagree R, Jalendra G, Panwar P, Shukla V, Reddy HM. Total laparoscopic pancreaticoduodenectomy in 26 patients: single surgeon experience. *Int Surg J* 2021;8:674-80.