

Case Report

Giant lipoma of breast-a diagnostic dilemma

D. J. Balsarkar, Sachin A. Suryawanshi*, Muna Shaikh, Sudhir Dhobale

Department of General Surgery, T. N. Medical College, Mumbai, Maharashtra, India

Received: 11 November 2020

Revised: 24 December 2020

Accepted: 04 January 2021

*Correspondence:

Dr. Sachin A. Suryawanshi,

E-mail: drsachinsurya@gmail.com

Copyright: © the author(s), publisher and licensee Medip Academy. This is an open-access article distributed under the terms of the Creative Commons Attribution Non-Commercial License, which permits unrestricted non-commercial use, distribution, and reproduction in any medium, provided the original work is properly cited.

ABSTRACT

Lipoma is the most common benign tumor of adipose tissue. Giant lipoma of breast is very rare. Majority of them are small in size, slow growing and asymptomatic until they reach large size. Most patients seek medical advice due to asymmetry in the breast and due to fear of malignancy. Breast lipomas pose a diagnostic challenge due to similarity of their texture to normal breast parenchyma and make it difficult to distinguish from other common breast lesions. The clinical and radiographic identification of breast lipoma remains challenging. Complete surgical excision with the capsule is essential to prevent recurrence. Breast reconstruction may require, to prevent asymmetry following surgical excision of giant breast lipoma. High degree of clinical suspicion and histopathological correlation will help in preoperative diagnosis of this clinical condition. Here, we report a case 50-year-old woman with left breast lump which clinically, radiologically and on fine needle aspiration cytology was diagnosed as phyllodes tumor, but after surgical excision it was reported as breast lipoma on final histopathology.

Keyword: Breast lipoma, Giant lipoma, Phyllodes tumor

INTRODUCTION

Lipoma is the most common mesenchymal tumor.¹ Majority of them are small in size, slow growing and termed as giant lipomas when they attain size of more than 10 cm in any diameter or more than 100 gm.² Lipoma of the breast are rare and usually benign.³ The clinical and radiographic identification of breast lipoma remains challenging. Complete surgical excision with the capsule is essential to prevent recurrence.

CASE REPORT

A 50-year-old woman presented to us with lump in her left breast for 5 years. Lump was initially small and gradually progressed to reach present size and was painless. There was no history of nipple discharge, trauma to breast, or weight loss. There was no family history of breast disease.

Examination revealed approximately 25x14x10 cm single, round shaped lump in her left breast which was nontender, mobile and variable in consistency involving all quadrants of breast without axillary lymphadenopathy. (Figure 1) Examination of contralateral breast and axilla was normal. She was evaluated for complete blood count, liver profile and renal profile which were normal. Mammography and fine needle aspiration cytology (FNAC) of left breast was suggestive of phyllodes tumor. In view of above findings, she was posted for elective left simple mastectomy after anesthesia fitness.

Intra-operatively a single, round solid lump was excised. This was measuring approximately 23x14x10 cm, replacing entire breast parenchyma with thinning of underlying pectoralis muscles (Figure 2). It weighed around 3500 gm. Frozen section was sent which was suggestive of phyllodes tumor.

Postoperative course of patient was uneventful and patient was discharged on fifth post-operative day. Final

histopathology was reported as benign lipoma of left breast. Patient was followed up after three months postoperatively without fresh complaints, having resumed her routine work.

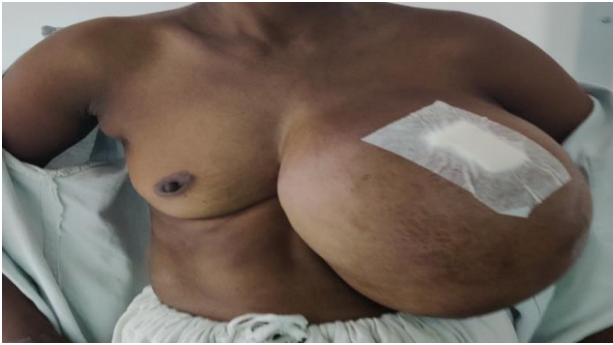

Figure 1: Preoperative image of left breast with lump.

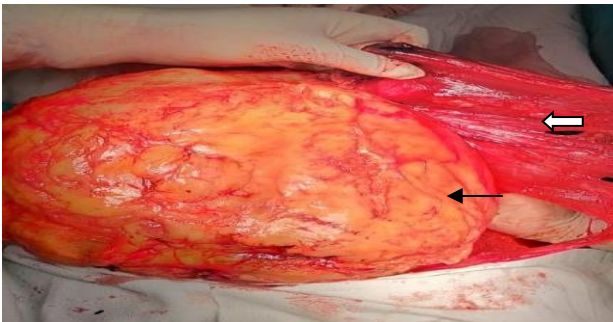


Figure 2: Intraoperative image of breast lump (black arrow) with thinned out pectoralis muscle (white arrow).

DISCUSSION

Lipoma is the most common mesenchymal tumor and thus also known as the universal tumor. They can arise in any part of body which has abundant adipose tissue. Various classifications exist depending on their etiology and location, with approximately 20% being located around the chest wall.⁴ Lipoma of breast is rare and usually benign. Their incidence is approximately 16% of all mesenchymal tumor.⁵ Most are small in size, solitary with thin capsule and slowly growing. Most patients seek medical advice due to asymmetry of the breast and more importantly due to fear of malignancy. Majority of the large breast tumors are detected on clinical and radiological examination. Due to similarity in texture with normal breast parenchyma, smaller lipomas are usually missed. Giant lipoma, presenting as a breast lump, may pose a diagnostic challenge and is clinically difficult to distinguish from other breast lesions. Deep nondominant masses and lipomas in large or post menopausal breast can easily be missed on ultrasound and mammography.⁶ Fine needle aspiration cytology is usually not helpful. However, core biopsy can provide

sufficient tissue for pathological evaluation. Complete excision of lump along with capsule is the definitive treatment for breast lipoma to prevent recurrence. Breast reconstruction may be required to prevent asymmetry in such cases, which is another challenge for aesthetic surgeons.⁷

Other common breast lesion which simulate breast lipoma are fibroadenoma, phyllodes tumor, duct papilloma, liposarcoma and carcinoma.⁸ In our patient almost complete left breast parenchyma was replaced by lipoma. Clinical, radiological and Fine needle aspiration cytology correlation was suggestive of phyllodes tumor, but it turned out to be lipoma of breast on final histopathology.

CONCLUSION

Giant lipoma of breast is very rare. Due to its similarity in texture with breast parenchyma, it is often difficult to differentiate it clinically and radiologically from other common breast lesions. High degree of clinical suspicion with good histopathological correlation is the key for proper diagnosis and management.

Funding: No funding sources

Conflict of interest: None declared

Ethical approval: Not required

REFERENCES

1. Vandeweyer E, Scagnol I. Axillary giant lipoma: a case report. *Acta Chir Belg.* 2005;105:656-7.
2. Sanchez MR, Golomb FM, Mayo JA, Potozkin JR. Giant lipoma: Case report and review of the literature. *J Am Acad Dermatol.* 1993;28:266-8.
3. Alper M, Nusret A. Angiomyolipoma in the breast and review of literature. *Turk J Med Sci.* 2000;30:615-8.
4. Hall FM, Connolly JL, Love SM. Lipomatous pseudomas of the breast: diagnosis suggested by discordant palpatory and mammographic findings. *Radiol.* 1987;164:463-4.
5. Lang C, Eriksen BO, Hoffmann J, lipoma of the breast: a diagnostic dilemma. *Breast.* 2004;13:408-11.
6. Guzzon A, Coopmans de Yoldi G, Bergozi S, Viganotti G, Nessi R, Bellomo AM. Radiodiagnostica dei lipomi della mammilla. *Radiol Med.* 1981;67:47-54.
7. Reemdonck D, De Mey A, Goldschmidt D. The treatment of giant lipomas. *Acta chir Belg.* 1992;92:213-6.
8. Gazioglu E. Surgical biopsies. In: Gazioglu E, editor. *Essentials in the Management of Breast Diseases.* Bucarest: Celcius Med Publications. 2005;51-60.

Cite this article as: Balsarkar DJ, Suryawanshi SA, Shaikh M, Dhobale S. Giant lipoma of breast-a diagnostic dilemma. *Int Surg J* 2021;8:752-3.