

Case Report

Case report: male breast carcinoma - mucinous adenocarcinoma a rare entity

Manik C. Gedam^{1*}, Sani Satish Jaiswal¹, Anil N. Pawar¹, Leena M. Ingle²

¹Department of Surgery, IGGMC, Nagpur, Maharashtra, India

²Department of Anesthesia, IGGMC, Nagpur, Maharashtra, India

Received: 16 June 2015

Revised: 02 July 2015

Accepted: 11 July 2015

***Correspondence:**

Dr. Manik C. Gedam,

E-mail: manik.gedam@gmail.com

Copyright: © the author(s), publisher and licensee Medip Academy. This is an open-access article distributed under the terms of the Creative Commons Attribution Non-Commercial License, which permits unrestricted non-commercial use, distribution, and reproduction in any medium, provided the original work is properly cited.

ABSTRACT

Male breast carcinoma is an uncommon neoplasm, accounting for 0.6% of all breast carcinomas and <0.5% of malignancies in men. Mucinous carcinoma is histopathologically characterized by the presence of clusters of neoplastic cell is suspended in extensive extracellular mucin. However, its occurrence in the male breast is extremely rare. A 54-year-old male presented with a subareolar firm to hard mass in the left breast, fixed to the overlying skin for 6 months duration. Physical examination revealed a well-circumscribed nodule, measuring 4x3 cm in diameter, in the left breast. Axillary lymph nodes were not palpable. The provisional diagnosis of carcinoma of breast was made and Fine-Needle Aspiration Cytology (FNAC) was advised. Smears showed abundant mucinous stroma in background with atypical cells lying in groups and also individually dispersed showing round to oval nuclei with regular nuclear margins and 1-2 prominent nucleoli. Modified Radical Mastectomy of left breast was done with ipsilateral axillary dissection. Grossly the mastectomy specimen was measuring 7x4x4 cm, nipple and areola was normal. Histopathology showed tumor cells arranged in nests and solid pattern floating in abundant extracellular mucin and thus confirmed the diagnosis of mucinous breast carcinoma. Male Breast Carcinoma (MBC) is an uncommon neoplasm and pure mucinous carcinoma of the male breast is an extremely rare neoplasm. The pure form is defined as a lesion with a mucinous carcinoma component in more than 90% of the tumor, and the mixed type has both mucinous and conventional invasive carcinoma components. Reported that the prognosis of pure mucinous carcinoma is more favorable than that of mixed type in females. Prognosis in male breast carcinoma is poor, maybe due to the smaller size of breast mass, which increases the probability of the involvement of surrounding structures. Prognosis depends on the stage at diagnosis as determined by tumor size and nodal metastasis. Estrogen receptor and progesterone receptor positivity has been noted in 90% of cases. Pure mucinous carcinoma is associated with a better prognosis and a low rate for axillary lymph node metastases.

Keywords: Male breast carcinoma, Mucinous adenocarcinoma

INTRODUCTION

Male breast carcinoma is an uncommon neoplasm, accounting for 0.6% of all breast carcinomas and <0.5% of malignancies in men.^{1,2} Mucinous carcinoma, also referred to as colloid carcinoma or gelatinous carcinoma, is histopathologically characterized by the presence of

clusters of neoplastic cell is suspended in extensive extracellular mucin, and accounts for ~2% of female breast carcinomas.³ However, its occurrence in the male breast is extremely rare.^{2,4,5} Pure mucinous carcinoma is associated with low rates of recurrence and excellent survival rates. In the present study, we report a case of pure mucinous carcinoma occurring in a male breast and

review the clinicopathological features of this extremely rare tumor.

CASE REPORT

A 54-year-old male presented with a subareolar firm to hard mass in the left breast, fixed to the overlying skin for 6 months duration. Physical examination revealed a well-circumscribed nodule, measuring 4x3 cm in diameter, in the left breast. Axillary lymph nodes were not palpable. The provisional diagnosis of carcinoma of breast was made and Fine-Needle Aspiration Cytology (FNAC) was advised. Smears showed abundant mucinous stroma in background with atypical cells lying in groups and also individually dispersed showing round to oval nuclei with regular nuclear margins and 1-2 prominent nucleoli (Figure 3). Modified Radical Mastectomy of left breast was done with ipsilateral axillary dissection (Figure 2).

Grossly the mastectomy specimen was measuring 7x4x4 cm, nipple and areola was normal. Cut section showed a well circumscribed tumour measuring 4x3x3 cm having gelatinous appearance (Figure 2). Histopathology showed tumor cells arranged in nests and solid pattern floating in abundant extracellular mucin and thus confirmed the diagnosis of mucinous breast carcinoma (Figure 3). The cell clusters are variable in size and shape sometimes with a tubular arrangement rarely, they assume a papillary configuration.

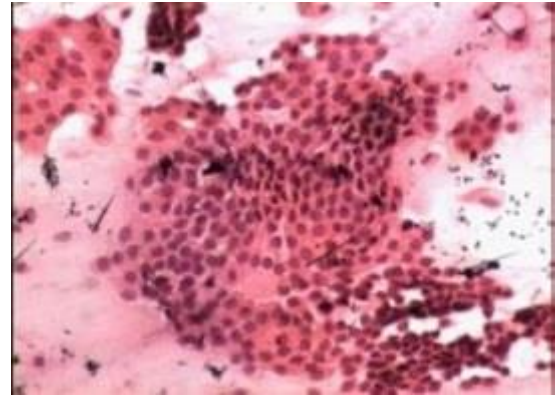


Figure 3: H/E Smear showing sheets of atypical cells with round to oval nuclei with regular nuclear margins against mucinous background (H&E 40x).

DISCUSSION

Male Breast Carcinoma (MBC) is an uncommon neoplasm, accounting for 0.6% of all breast carcinomas and <1% of malignancies in men.^{1,2} Men present at an older age than women (median age of 64.5 years) and MBC incidence increases with an advancing age. Pure mucinous carcinoma of the male breast is an extremely rare neoplasm.⁶ Carcinoma in male breast is hundred times less frequent than in female breast. Radiation exposure, genetic predisposition, chronic liver diseases, and schistosomiasis have been linked to increased incidence of carcinoma in male breast. An association with Klinefelter's syndrome has been noted with 20 times higher frequency.³⁻⁵ Very few cases of primary mucinous carcinoma have been reported in male breast.³ The pure form is defined as a lesion with a mucinous carcinoma component in more than 90% of the tumor, and the mixed type has both mucinous and conventional invasive carcinoma components.³ reported that the prognosis of pure mucinous carcinoma is more favorable than that of mixed type in females. Therefore, certain researchers have suggested that axillary lymph node dissection may be unnecessary for pure mucinous carcinoma, and they recommend sentinel lymph node dissection instead for patients with this form of tumor.⁷ However, certain cases of pure mucinous carcinoma with axillary lymph node metastasis in the male breast have been reported.^{5,9,10} Fine Needle Aspiration Cytology (FNAC) is an easy and useful procedure for the diagnosis of breast tumors. A few cases of mucinous carcinoma of the male breast successfully diagnosed by FNAC have been reported.⁹ In our case mucinous carcinoma has been diagnosed primarily on FNAC. Prognosis in male breast carcinoma is poor, maybe due to the smaller size of breast mass, which increases the probability of the involvement of surrounding structures. Prognosis depends on the stage at diagnosis as determined by tumor size and nodal metastasis.⁴ Estrogen receptor and progesterone receptor positivity has been noted in 90% of cases.^{5,6} Pure mucinous carcinoma is associated with a better prognosis and a low rate for axillary lymph node metastases.¹¹

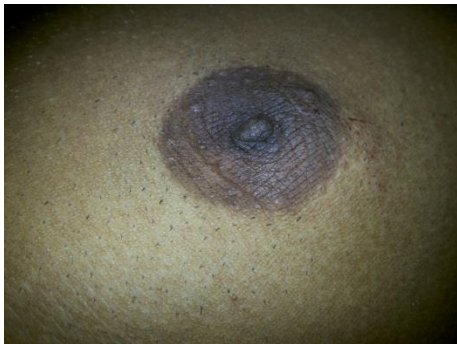


Figure 1: Pre op images of lump.

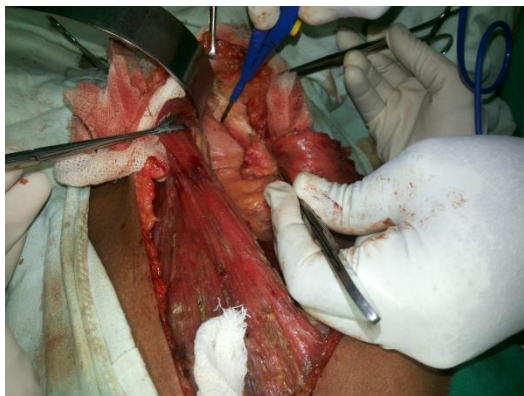


Figure 2: Intraoperative images of modified radical mastectomy.

Funding: No funding sources

Conflict of interest: None declared

Ethical approval: Not required

REFERENCES

1. Heller SK, Rosen PP, Schottenfield D, Ashikari Kinne DW. Male breast cancer: a clinicopathological study of 97 cases. *Ann Surg.* 1978;188:60-5.
2. Rosen PP. Carcinoma male breast. In: Rosen PP, eds. *Rosen's Breast Pathology.* 2nd ed. Philadelphia: Lippincott Williams and Wilkins Publisher; 2001: 713-725.
3. Bhagat P, Kline TS. The male breast and malignant neoplasm: Diagnosis by aspiration biopsy cytology. *Cancer.* 1990;65:2338-41.
4. Nayak SK, Naik R, Upadhyaya K, Raghuveer CV, Pai MR. FNAC diagnosis of mucinous carcinoma of male breast- case report. *Indian J Pathol Microbiol.* 2001;44:355-7.
5. Rosen PP, Hoda SA. Breast lesions in men and children. In: Rosen PP, Hoda SA, eds. *Breast Pathology Diagnosis by Needle Core Biopsy.* 2nd ed. Philadelphia: Lippincott Williams and Wilkins Publishers; 1999: 263-270.
6. Tirgari F, Rad AA, Mahjoub F, Mohammadi M, Tabarzan N. Male breast carcinoma: an immunohistochemical study of 50 cases. *Iran J Pathol.* 2008;3:94-9.
7. Aggarwal R, Rajni, Khanna G, Beg S. Mucinous carcinoma in a male breast case report. *J Cytol.* 2011;28:84-6.
8. Rasmussen BB, Rose C, Christensen IB. Prognostic factor in primary mucinous carcinoma. *Am J Clin Pathol.* 1987;87:155-60.
9. Dragoumis DM, Assimaki AS, Tsiftoglou AP. Pure mucinous breast carcinoma with axillary lymph nodes metastasis in a male breast: case report. *Breast Cancer.* 2012;19(4):365-8.
10. Visfelldt J, Scheike O. Male breast cancer: Histological typing and grading of 187 Danish cases. *Cancer.* 1973;32:985-90.
11. Sharma S, Bansal R, Khare A, Agrawal N. Mucinous carcinoma of breast: cytodiagnosis of a case. *J Cytol.* 2011;28:42-4.

Cite this article as: Gedam MC, Jaiswal SS, Pawar AN, Ingle LM. Case report: male breast carcinoma - mucinous adenocarcinoma a rare entity. *Int Surg J* 2015;2:434-6.