

## Case Report

# Bowel perforation presenting as necrotizing soft-tissue infection of thigh a rare presentation

Navdeep Garg, Kunal Singla\*, Maninder Singh,  
Mandeep Singh, Rajesh Kumar Bansiwal, Rajeev Sharma

Department of General Surgery, Government Medical College and Hospital, Chandigarh, India

**Received:** 06 August 2020

**Revised:** 03 September 2020

**Accepted:** 10 November 2020

### \*Correspondence:

Dr. Kunal Singla,

E-mail: [shinesingla47@gmail.com](mailto:shinesingla47@gmail.com)

**Copyright:** © the author(s), publisher and licensee Medip Academy. This is an open-access article distributed under the terms of the Creative Commons Attribution Non-Commercial License, which permits unrestricted non-commercial use, distribution, and reproduction in any medium, provided the original work is properly cited.

## ABSTRACT

Necrotizing soft-tissue infections (NSTI) are characterized by extensive and rapidly progressing soft tissue inflammation with necrosis. It typically involves a gas-forming bacterium such as group A b-hemolytic *Streptococcus* or a *Clostridium* species. This gas formation leads to the radiographic finding of subcutaneous emphysema. It is recognized as a surgical emergency. NSTI of the abdominal wall, flank, or thigh resulting from break-in bowel integrity is an atypical presentation that may cause delayed recognition and treatment, resulting in a mortality rate greater than that in Fournier gangrene. Early detection and aggressive surgical debridement are crucial to reduce patient mortality and morbidity. We present the case of a 30-year-old patient presenting with fasciitis of lower limb. Surgical exploration revealed the source of the emphysema to be an entero-cutaneous fistula. The patient had an unstable and prolonged hospitalization after debridement of the thigh and abdominal surgery and was discharged after one month. It suggested that clinical presentation can be highly variable and range from early sepsis with obvious skin involvement to minimal cutaneous manifestations of underlying disease.

**Keywords:** Necrotizing fasciitis, Bowel perforation, Soft tissue infection, Rare presentation, Peritonitis

## INTRODUCTION

NSTI are characterized by extensive and rapidly progressing soft tissue inflammation with necrosis. These infections comprise a spectrum of diseases ranging from necrosis of the skin to involving the fascia and muscle with systemic toxicity.<sup>1</sup>

Such infections of the male genitalia were first described by Fournier in 1883, and the pathophysiology was microbial invasion of the subcutaneous (SC) tissues occurs either through external trauma or direct spread from a perforated viscous (particularly colon, rectum, or anus) or urogenital organ.<sup>2</sup>

Necrotizing fasciitis is one of the few true emergencies in surgery. It typically involves a gas-forming bacterium such as group A b-hemolytic *Streptococcus* or a *Clostridium* species. This gas formation leads to the radiographic finding of subcutaneous emphysema.<sup>3</sup>

NSTI of the abdominal wall, flank, or thigh resulting from break-in bowel integrity is an atypical presentation that may cause delayed recognition and treatment, resulting in a mortality rate greater than that in Fournier gangrene.

We present the case where the patient presented with subcutaneous emphysema of left lower limb attributed to the bowel perforation.

## CASE REPORT

A 30-year old female patient presented in surgery emergency GMCH with complaint of pus discharge and swelling in the left thigh for 3 days. It was associated with pain in the left thigh which was acute in onset, moderate in intensity and progressive in nature with the history of fever for 2 weeks for which she took medications from local practitioners after which she developed pus discharge from which was yellow in color and foul-smelling.

There is a history of trauma by cricket ball 3 months back. There was no history of HTN/DM/TB. No history of similar episodes in the past. On physical examination the patient was afebrile with BP=108/74, pulse=104 BPM.

An abdominal examination revealed a scaphoid abdomen that was soft and non-tender. Normal abdominal bowel sounds were present.

Lower limb examination revealed a discharging sinus at the lateral aspect of proximal thigh having yellowish discharge with surrounding erythema. On palpation it had 2+ pitting oedema with crepitus starting from the iliac crest to knee joint present with and mild tenderness to palpation over the lateral side of the left thigh.

Laboratory tests revealed a peripheral total leukocyte count of 15,300, INR of 1.0, HB-9.0

Radiographs of the left hip and femur ordered owing to left thigh swelling and pain. Subcutaneous emphysema was seen on the radiographs leading to concern for necrotizing fasciitis.

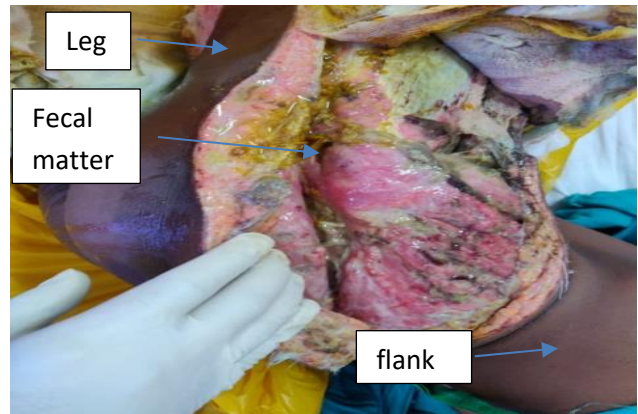
The Patient was taken to an emergency operating room for urgent fasciotomy and debridement under spinal anaesthesia. Longitudinal incision along the lateral aspect of the thigh was made, yielding air from the subcutaneous plane. The incision over the fascia yields 50 ml of pus frank pus with foul-smelling slough. However, the underlying muscles were healthy. The Wound was thoroughly debrided of the slough and washed.

Postoperatively patient managed with IV antibiotics, daily dressings with betadine. Peripheral total leukocyte count drops down to 8200, HB-6.9. Pus culture came out positive with *Escherichia coli* and *Enterococcus fecalis* as causative organisms. On postop day 5 patient had fecal discharge from fasciotomy wound. Plan for urgent laparotomy IV/O fecal fistula

The patient was taken to an OR during laparotomy there was a perforation in descending colon which was adherent to the lateral abdominal wall causing fecal fistula (entero-cutaneous) with subcutaneous fecal soiling leading to gas gangrene of left thigh.

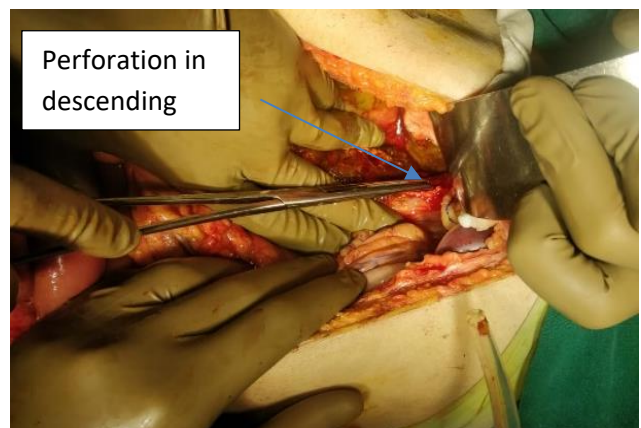
Resection of the perforated segment with end to end anastomosis of descending colon and sigmoid colon was done with a proximal loop ileostomy.

Postoperatively stoma became functional and the patient started accepting a normal diet with no spike of fever. Secondary closure of thigh wound was done on postop day 25 and discharged.



**Figure 1: Fasciotomy of the left leg with fecal contamination.**

At follow up after 3 months, all wounds were healed and she was walking with a walker. After 6 months the ileostomy was closed with restoration of bowel continuity.



**Figure 2: Laparotomy with perforation (adherent to the anterior abdominal wall).**

## DISCUSSION

The clinical presentation of NSTI is highly variable and can range from early sepsis with obvious skin involvement to minimal cutaneous manifestations of underlying necrotizing fasciitis. The usual clinical presentation begins with localized pain and benign appearance. Clinical “clues” which may assist in establishing an early diagnosis are edema beyond the area of erythema, small skin vesicles and crepitus. Additional

local signs suggesting deep infection may include cyanosis or bronzing of the skin, induration, dermal thrombosis, epidermolysis or dermal gangrene. Classic signs of large blisters, gangrene, diffuse crepitus, and shock indicates the infectious process is already at an advanced stage.<sup>1</sup>

There are several case reports of bowel perforation presenting as subcutaneous emphysema of the thigh, one reported by Saldua in clinical orthopedics and related research 2009.<sup>3</sup>

A 64-year-old patient with a history of post-surgical radiation for rectal carcinoma with subcutaneous emphysema of the thigh in the presence of urinary sepsis. Surgical exploration revealed the source of the emphysema to be an entero-cutaneous fistula.<sup>3</sup>

It usually involves gas-forming organisms such as group A *Streptococcus* species or a *Clostridium* species. This gas formation leads to the finding of subcutaneous emphysema on plain radiographs. Thus, despite an otherwise benign clinical appearance, the radiographic finding of subcutaneous emphysema in the absence of penetrating trauma must be considered a case of a necrotizing soft tissue infection until proven otherwise.<sup>3</sup> It is a rapidly progressing infection that has been associated with mortality rates of 26 to 34%. Early and aggressive surgical debridement provides the best chance for survival.<sup>4</sup>

There are other causes of subcutaneous emphysema for example any traumatic wound can lead to air in the subcutaneous tissues. Perforations of the trachea or the esophagus can present with upper extremity subcutaneous emphysema. When the location of subcutaneous emphysema is in the upper portion of the lower extremity, an intestinal source must be considered.<sup>5</sup>

In a study by Kumar et al in 2018 states that in cases of necrotizing soft tissue infection of the abdomen, flank and lower limbs resulting from bowel injury due to various causes including trauma (29%), perforated appendicitis (23%), perforated diverticulitis (16%), and perforation of a gastrointestinal tract cancer (16%) have the mortality rate >33%. This atypical presentation cause associated bowel perforation to be overlooked, leading to delayed surgical treatment.<sup>6</sup>

In our case the surgical debridement was done on the same day without any delay, as there was no bile or fecal discharge at the time of debridement, no bowel injury was suspected. Fecal matter became evident on POD 5 following which the patient was immediately taken for laparotomy. This delay in diagnosis of bowel injury can be decreased by doing a contrast-enhanced CT scan of the abdomen because of the emphysema of leg.

## CONCLUSION

NSTI of the abdominal wall and lower extremities may result from a break in bowel integrity attributable to trauma, perforation either tubercular or typhoid. The initial clinical presentation may be atypical and misleadingly. Radiological investigation such as CT can confirm the diagnosis, but, exploratory surgery may be justified on the basis of the clinical suspicion, even in the absence of CT confirmation. The management of patients is the same, repair of perforation, surgical debridement and broad-spectrum antibiotic coverage. Perforation presenting as NSTI leading to delayed diagnosis, delayed surgical intervention, and hence the poor outcome. An NSTI caused by bowel perforation typically is poly microbial with gram-negative, gram-positive, and anaerobic bacteria. all commonly isolated. Therefore, when NSTI is suspected, empiric antibiotic therapy should be broad and directed toward enteric facultative and anaerobic flora.

*Funding: No funding sources*

*Conflict of interest: None declared*

*Ethical approval: Not required*

## REFERENCES

1. Bosshardt TL, Henderson VJ, Claude H Organ J. Necrotizing soft-tissue infections. Surgical Treatment: Evidence-Based and Problem-Oriented. Holzheimer RG, Mannick JA, editors. Munich: Zuckschwerdt. 2001.
2. Sarani B, Strong M, Pascual J, Schwab CW. Necrotizing fasciitis: current concepts and review of the literature. J Am Coll Surg. 2009;208(2):279-88.
3. Saldua NS, Fellars TA, Covey DC. Case Report: Bowel Perforation Presenting as Subcutaneous Emphysema of the Thigh. Clin Orthop Relat Res. 2010;468(2):619-23.
4. McHenry CR, Piotrowski JJ, Petrinic D, Malangoni MA. Determinants of Mortality for Necrotizing Soft-Tissue Infections: Ann Surg. 1995;221(5):558-65.
5. Nijhof HW, Steenvoorde P, Bonsing BA, Hartgrink HH. Necrotizing soft tissue infection of the thigh: consider an abdominal cause. World J Surg. 2006;30(10):1836-42.
6. Kumar D, Cortés-Penfield NW, El-Haddad H, Musher DM. Bowel Perforation Resulting in Necrotizing Soft-Tissue Infection of the Abdomen, Flank, and Lower Extremities. Surg Infect. 2018;19(5):467-72.

**Cite this article as:** Garg N, Singla K, Singh M, Singh M, Bansiwala RK, Sharma R. Bowel perforation presenting as necrotizing soft-tissue infection of thigh a rare presentation. Int Surg J 2020;7:4206-8.