

Case Report

An interesting case of spindle cell sarcoma of elbow

Sana Aboosalih^{1*}, V. Shruthi Kamal¹, Surya Rao Venkata Mahipathy²,
Senthil Kumar Azhisoor Chandrasekhar³, Balu Krishnamurthy Mahendra³,
Anand Prasath Jayachandiran², Narayanamurthy Sundaramurthy²

¹Department of General Surgery, ²Department of Plastic and Reconstructive Surgery, ³Department of Surgical Oncology, Saveetha Medical College and Research Institute, Thandalam, Kanchipuram, Tamil Nadu, India

Received: 03 June 2020

Accepted: 09 July 2020

***Correspondence:**

Dr. Sana Aboosalih,

E-mail: dr.sanasali@gmail.com

Copyright: © the author(s), publisher and licensee Medip Academy. This is an open-access article distributed under the terms of the Creative Commons Attribution Non-Commercial License, which permits unrestricted non-commercial use, distribution, and reproduction in any medium, provided the original work is properly cited.

ABSTRACT

Spindle cell sarcomas are a group of aggressive malignant soft tissue tumors with a diverse clinical presentation. A 32 years old woman presented with a recurrent nerve sheath tumour, involving flexor carpi ulnaris and a portion of ulnar nerve. Wide local excision of the tumour was done creating a 4 cm gap defect in the ulnar nerve. Distal nerve transfer and Guyon's canal release was done and anterior transposition of ulnar nerve to distal motor branch of ulnar nerve end to side (ETS) supercharge was done preserving motor function to the little and ring finger. Achieving negative surgical margins in primary soft tissue sarcoma is a critical for local disease control. The anatomical and functional compromise that can occur while giving adequate clearance margin for the tumor can be overcome by microsurgical techniques and neuroanastomosis with positive outcomes like preservation of function and better prognosis.

Keywords: Spindle cell sarcoma, Ulnar nerve, Neuroanastomosis, End to side supercharge

INTRODUCTION

Spindle cells are cells of mesenchymal origin, forming a part of the body's connective tissue system. These cells can be part of neural, fibroblastic, myofibroblastic, myogenic, epithelial or vascular tissue.

Owing to their varied distribution Spindle cell sarcomas are a group of aggressive malignant soft tissue tumors with a diverse clinical presentation. The tumors of neural origin can arise from any part of the body.

They are bulky deep-seated tumour usually arising from major nerves in neck, forearm, lower leg, buttock and with local reoccurrence.¹ Soft tissue sarcomas of the upper extremity represent a severe threat for the patient due to the complex anatomy of the arm and most sarcomas involve valuable functional structures.

CASE REPORT

A 32 years old woman presented to the surgical OPD, at Saveetha Medical College, Chennai with complaints of swelling and pain of right forearm. The swelling was insidious in onset and progressively increasing in size to attain present size of approximately 3x2 cm within the past 7 months and is associated with radiating pain from the swelling to the medial aspect of forearm and hand involving the little and ring finger. She had no history of trauma, fever, ulceration, features suggestive of von Recklinghausen's neurofibromatosis or history of radiation exposure in the past. Her past history revealed a similar swelling in the same region was, 3 years back, for which patient underwent excision biopsy and histopathological examination was suggestive of a nerve sheath tumor. She did not undergo any further treatment after excision biopsy was done.

On further clinical evaluation, a swelling of size 3x2 cm, over the postero-medial aspect and in front of the right elbow joint was seen along with the previous surgical scar (Figure 1).

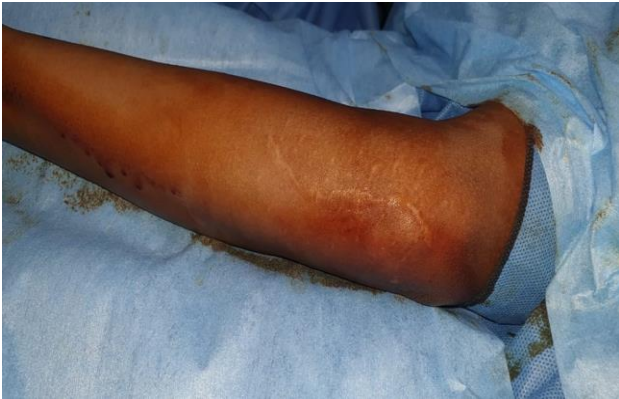

Figure 1: Clinical photograph showing previous surgical scar.

On palpation, the swelling had a smooth surface, firm in consistency, with all margins palpable. In addition to local tenderness she presented with a pain radiating to her little and ring finger. Routine blood investigations were found to be within normal limits. MRI of the right forearm showed extra-osseous, extra-articular, intramuscular, T1 - focal lobulated hypointense, T2 - mild hyperintense lesion seen in the flexor carpi ulnaris of size 9x13x34 mm (AP x TR x CC) with central homogenous peripheral lobulated irregular margins. The lesion extending to subcutaneous plane in the medial dorso-volar aspect suggestive of a recurrent or residual primary benign or malignant nerve sheath tumour from likely a branch of the ulnar nerve in the flexor carpi ulnaris (Figure 2).

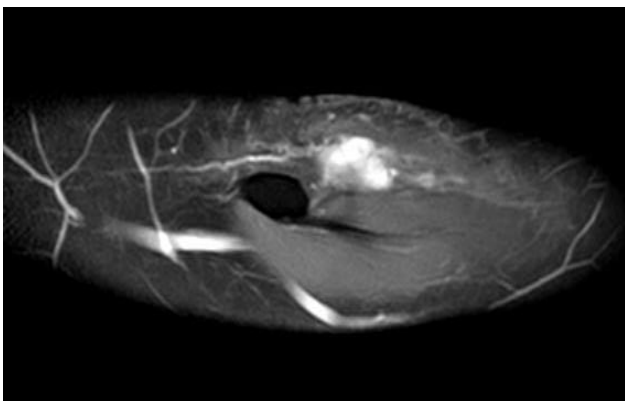


Figure 2: MRI picture of the lesion.

Patient was taken up for surgery and wide local excision of the tumor of size 4x3 cm was done along with the flexor carpi ulnaris and a portion of ulnar nerve measuring approximately 4 cm (Figure 3). Oriented specimen was handed over to the pathologist for frozen

section biopsy which revealed all the margins were free of tumour cells.

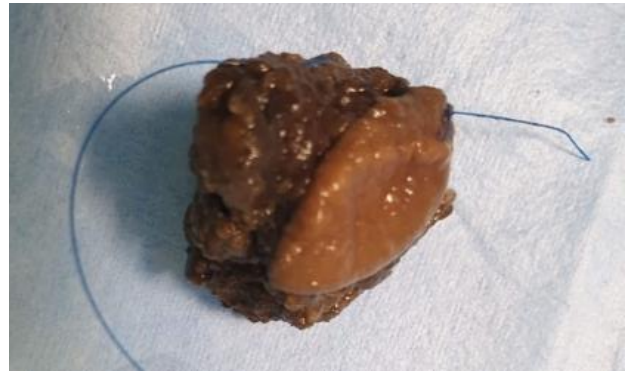

Figure 3: Photograph of the resected specimen.

Following resection of ulnar nerve, after anterior transposition, the nerve gap was 5.5 cm for which sural nerve cable graft was done (Figure 4 and 5).

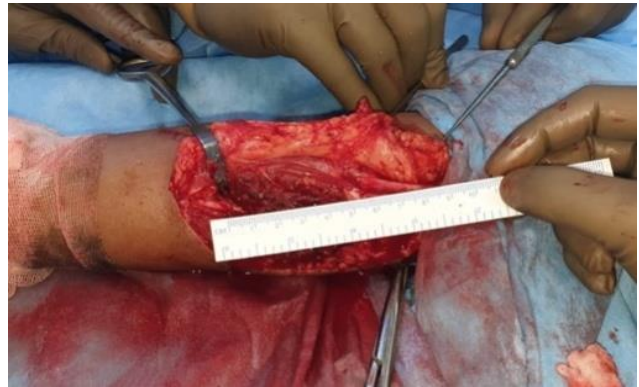

Figure 4: Defect of ulnar nerve.

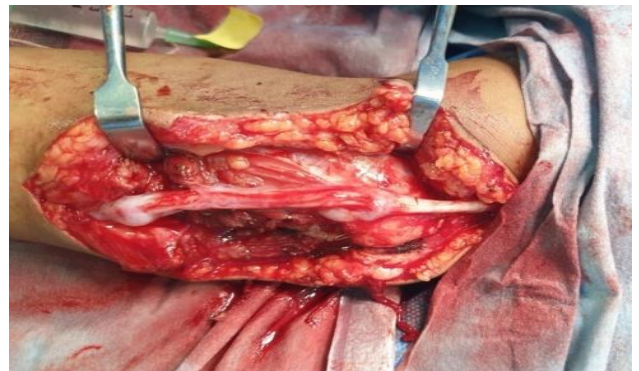


Figure 5: Ulnar nerve defect bridged with sural nerve cable graft.

Guyon's canal release was done to identify deep motor branch of ulnar nerve. Anterior interosseous was identified on the interosseous membrane and was supercharged to the deep branch of ulnar nerve in end to side (ETS) fashion (Figure 6).

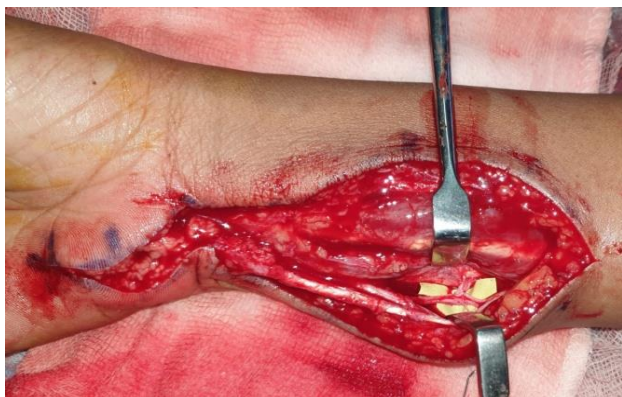


Figure 6: Supercharging of anterior interosseous nerve to deep motor branch of ulnar nerve.

On histopathological examination revealed a low-grade spindle cell sarcoma of neural origin with resected margins free of tumor was noted. The histologic grade according to French federation of cancer center sarcoma group (FNCLCC) was grade 1, with pathological stage classification being rpT1 (tumor less than 5 cm). Post-operative period was uneventful and no functional deficit was noted. Patient was discharged on 10th post-operative day. Adjuvant radiation therapy was administered and with routine physiotherapy care and patient was followed up for 3 months and had no further complaints, functional deficit and no local recurrence.

DISCUSSION

Spindle cells are cells of mesenchymal origin and they constitute a part of the body's connective tissue system and neoplasms arising from these cells can be benign or malignant. On microscopic examination, elongated spindle cells with fusiform or ovoid nucleus are seen and they present with a diverse clinical picture.^{2,3} These tumours generally begin in layers of connective tissue such as that of under the skin, between muscles, and surrounding organs, forming a lump which grows gradually. In the earlier stages, they are localised and usually do not spread beyond the encapsulated form, but they can also develop malignant potential which is detected through microscopic examination.⁴ Malignant peripheral nerve sheath tumours (MPNST) are a rare entity accounting for 5-10% of soft-tissue sarcomas they are an important differential diagnosis to benign tumours of the peripheral nervous system.⁵

Epithelial-Mesenchymal Transition (EMT) and lack of expression of cell adhesion molecules like cadherins is a primary process describing the pathogenetic mechanisms.⁶ Spindle cell sarcoma can develop due to other reasons like genetic predisposition or injury and inflammation in patients that are already thought to be predisposed to such tumours. Spindle cells are a naturally occurring part of the body's response to injury. In response to an injury, infection, or other immune response the connective tissues will begin dividing, to

heal the affected area, and if the tissue is predisposed to spindle cell cancer, the high cellular turnover may result in a few becoming cancerous and forming a tumour. The most frequent initial symptoms were local swelling and pain. The vast appearances and architectural patterns of the spindle cell tumours make the distinction from similar microscopic lesions quite difficult.⁷ Local recurrence of high-grade tumours have been described in various case reports. While 50% cases are associated with neurofibromatosis, our patient had no stigmata suggestive of neurofibromatosis.⁸

As the spindle cell sarcomas contain both benign and malignant counterparts, misclassification leads to therapeutic challenges which result in either under or over treatment of the patient. The tissue of origin can determine the biologic potential of the lesions. Thus, the use of techniques like immunohistochemistry, electron microscopy and molecular pathology can be quite beneficial. Malignant peripheral nerve sheath tumours are spindle cell sarcomas normally situated in the deep soft tissues. When it arises in the upper limb this tumour may pose a considerable diagnostic and therapeutic problem.⁹ Wide local excision of the tumour is the treatment of choice followed by thorough biopsy and additional excision if necessary.¹⁰ In high grade lesions, prognosis is grim and chemotherapy and radiation are the only methods of controlling the cancer.⁴ Functional compromise that can occur while giving adequate clearance margin for the tumor is common, however microsurgical techniques and neuroanastomosis provide the patient with better prognosis along with preserving function. Damaged nerves following benign tumour removal must be treated like traumatic injuries and thus need repair. Nerve transfers involve the concept of utilizing a functional nerve to a redundant muscle group in order to regain a lost critical function. In an ETS nerve transfer, the distal end of an injured nerve is transferred to the side of an intact donor nerve, which allows for partial neuronal regeneration at the expense of the expendable donor nerve fibers.¹¹

Anterior interosseous nerve to ulnar motor group ETS nerve transfer was designed for in-continuity injuries of the ulnar nerve, however, clinically it can be used for second-degree or third-degree axonotmesis type injuries of other motor nerves. Application of this technique can be used to augment partial recovery and/or preserve motor end plates until the native axons within that nerve regenerate to the motor end plate.¹²

A meta-analysis by Dunn et al. showed that ETS yielded a high return of intrinsic function in 91.9% patients at 3.7 months and 8% did not recover intrinsic strength.¹⁰ Our patient had no functional deficit on review at 3 months. The ETS anterior interosseous-to-ulnar nerve transfer may be a useful technique for augmenting intrinsic muscle function for severe, in continuity lesions of the ulnar nerve where limited surgical options exist.

CONCLUSION

Achieving negative surgical margins in primary STS is critical for local disease control. In case of local recurrence, obtaining negative surgical margin will require extensive surgery resulting in loss of extremity function. Despite the complex anatomy and functional compromise that can occur while giving adequate clearance margin for the tumor, microsurgical techniques and neuroanastomosis provide the patient with better prognosis along with preserving function.

Funding: No funding sources

Conflict of interest: None declared

Ethical approval: Not required

REFERENCES

1. Shankar V. Malignant peripheral nerve sheath tumor (MPNST). Pathology Outlines.com website. Available at <http://www.pathologyoutlines.com/topic/softtissuem pnst.html>. Accessed on 9 February 2020.
2. Wikivet. Spindle Cell Tumours. Available at https://en.wikivet.net/Spindle_Cell_Tumours.
3. Akerman M, Domanski HA. Monographs in Clinical Cytology: The Cytology of Soft Tissue Tumours. Basel Karger. 2003;16:103-6.
4. Shaikh, Sohail, Katke, Rajshree, Raut, Soham. Spindle Cell Sarcoma Arising from Nerve Sheath Presenting as Huge Abdominal Mass. J Case Reports. 2014;4:232-5.
5. Stark AM, Buhl R, Hugo HH, Mehdorn HM. Malignant Peripheral Nerve Sheath Tumours - Report of 8 Cases and Review of the Literature. Acta Neurochirurgica. 2001;143(4):357-64.
6. Prakash N, Kumar HMS, Sharada P, Pradeep GL. Spindle Cell Carcinoma of the Oral Cavity: A Case Report of a Rare Entity and Review of Literature. World J Dentistry. 2010;1(1):55-8.
7. Shamim T. The spindle cell neoplasms of the oral cavity. Iran J Pathol. 2015;10(3):175-84.
8. Arpornchayanon O. Malignant Peripheral Nerve Tumors: A Clinicopathological and Electron Microscopic Study. Japanese J Clin Oncology. 1984;14(1):57-74.
9. Coady MSE, Polaczar S. Cutaneous Malignant Peripheral Nerve Sheath Tumour (MPNST) of the Hand: A Review of Current Literature. J Hand Surg. 1993;18(4):478-81.
10. Dunn JC, Gonzalez GA, Fernandez I. Supercharge end-to-side nerve transfer: systematic review. Hand (NY). Accessed on 29 March 2019.
11. Hayashi A, Pannucci C, Moradzadeh A, Kawamura D, Magill C, Hunter D, et al. Axotomy or compression is required for axonal sprouting following end-to-side neuroorrhaphy. Exp Neurol. 2008;211:539-50.
12. Barbour, John, Yee, Andrew, Kahn, Lorna, et al. Supercharged End-to-Side Anterior Interosseous to Ulnar Motor Nerve Transfer for Intrinsic Musculature Reinnervation. J Hand Surg. 2012;37:2150-9.
13. Daigeler A, Zmarsly I, Hirsch T, Goertz O, Steinau HU, Lehnhardt M, et al. Long-term outcome after local recurrence of soft tissue sarcoma: a retrospective analysis of factors predictive of survival in 135 patients with locally recurrent soft tissue sarcoma. Br J Cancer. 2014;110(6):1456-64.

Cite this article as: Aboosalih S, Kamal VS, Mahipathy SRRV, Chandrasekhar SKA, Mahendra BK, Jayachandiran AP, et al. An interesting case of spindle cell sarcoma of elbow. Int Surg J 2020;7:2781-4.