

Case Report

Large posterior mediastinal goiter post total cervical thyroidectomy: a case report

Maria Fesatidou¹, Vasiliki Fesatidou², Georgios Tsoulfas³, Ioannis T. Fessatidis^{4*}

¹Medical University of Sofia, Sofia, Bulgaria

²Department of General Surgery, Papanikolaou General Hospital, Thessaloniki, Greece

³Department of General Surgery, Aristotle University of Thessaloniki, Thessaloniki, Greece

⁴Department of Cardiothoracic Surgery, Euromedica General Clinic Thessaloniki, Greece

Received: 27 May 2020

Accepted: 09 July 2020

*Correspondence:

Dr. Ioannis T. Fessatidis,

E-mail: fessatidis@genikikliniki.gr

Copyright: © the author(s), publisher and licensee Medip Academy. This is an open-access article distributed under the terms of the Creative Commons Attribution Non-Commercial License, which permits unrestricted non-commercial use, distribution, and reproduction in any medium, provided the original work is properly cited.

ABSTRACT

Thoracotomy approach is indicated for a complete and safe posterior mediastinal goitre removal. A 68 years old male was hospitalized due to a right mediastinal mass found in a chest X-ray and confirmed by computed tomography. The patient had undergone total cervical thyroidectomy thirty years ago. A computed tomography (CT) guided percutaneous needle biopsy of the mass revealed thyroid tissue. Subsequently, the mass was completely resected through a right posterolateral thoracotomy. The histopathology confirmed a large mediastinal goitre with no signs of malignancy. The patient had an uncomplicated recovery. We present a relatively rare case of a successful resection of a posterior mediastinal goitre, occurring thirty years post-total cervical thyroidectomy. We advocate lateral thoracotomy to achieve a broad operative field and enhance surgical safety.

Keywords: Intra-thoracic goitre, Posterior mediastinum, Thoracotomy, Thyroidectomy

INTRODUCTION

Posterior mediastinal goitres are relatively rare, comprising only about 10% of all intrathoracic goitres.¹ Recurrent, ectopic, retro-vascular mediastinal goitres are generally subjected to surgery because of high risk of tracheal and oesophageal compression.² We report a large right posterior mediastinal goitre identified 30 years post total cervical thyroidectomy, and which was completely excised via a posterolateral thoracotomy.

CASE REPORT

A 68 years old male presented with dyspnoea on exertion. Medical history included a total cervical thyroidectomy 30 years ago, with no signs of malignancy. Chest X-ray showed a mass occupying the right apical paratracheal space causing displacement of the trachea (Figure 1A).

The patient was clinically and biochemically euthyroid and on thyroid hormone T4 substitute treatment TSH was 1,293 (N=0, 35-5, 50 µIU/ml) and T4 was 1,25 (N=0,89-1,76 ng/dl).

Pre-operative investigations included a CT-guided percutaneous needle biopsy of the right posterior mediastinal mass which revealed thyroid tissue (Figure 1B).

Additionally, a selective angiography of the tumour was performed, which revealed that the blood supply was arising from an aberrant vessel from the right thyrocervical trunk (Figure 1C).

The surgery was performed via a right posterolateral thoracotomy, with a double-lumen endotracheal tube through the 4th intercostal space (Figure 2A). A large

encapsulated mass was found in the right posterior apex overlying the trachea in the mid-part, with the oesophagus on the back, inferiorly the margins of the azygos vein, anteriorly the superior vena cava and superiorly the anonymous artery (brachiocephalic trunk) and right subclavian artery.

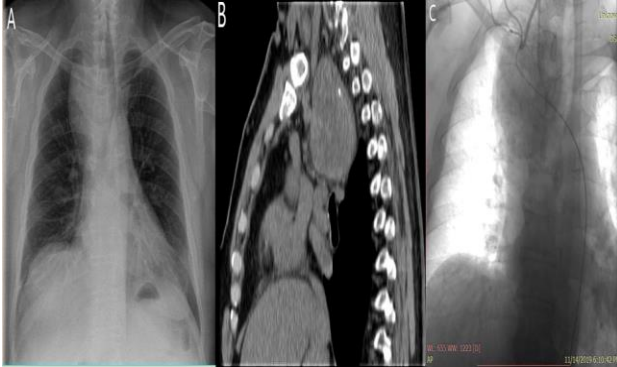

Figure 1: (A) C X-ray showing the right posterior mediastinal mass causing tracheal displacement, (B) CT scan confirming the extend and location of the mass and (C) selective catheterization of the brachiocephalic artery, showing aberrant artery arising from the thyrocervical trunk at the level of RIMA close to the origin of the vertebral artery.

The consistency of the mass was soft, with excessive venous vasculature (Figure 2B). A complete excision with electrocautery was performed. There was no damage to the surrounding tissues and vasculature. Histological examination revealed the absence of malignant cells (Figure 2C).

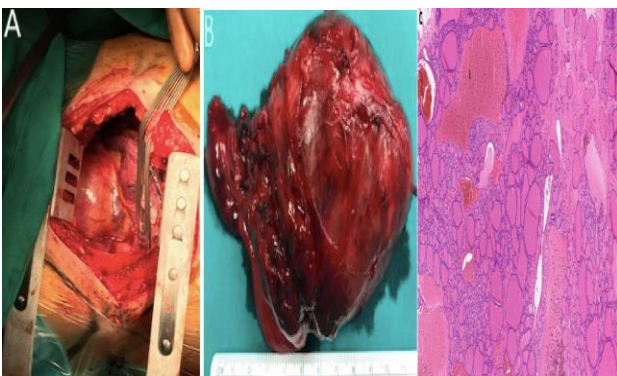


Figure 2: (A) Right posterolateral thoracotomy via the 4th interspace. Intra-operative view of the mass. (B) Gross inspection of the mass, with 12x7, 5x7 and 2 cm dimensions and (C) histopathological examination revealed thyroid tissue with no signs of malignancy.

Haemostasis was meticulous and the chest was closed with an apical posterior chest tube. The patient was discharged home on the 19th post-operative day, due to continuous pleural fluid discharge causing denudation of the lower part of trachea and the mid-oesophageal wall.

DISCUSSION

Posterior mediastinal goitre following total cervical thyroidectomy is a rare disease and infrequently reported. Mediastinal goitres can remain asymptomatic until there is compression of the structures located in the thoracic inlet. The most common symptom is dyspnoea because of the high risk of tracheal compression. Other symptoms may include stridor, wheezing, cough, dystonia, hoarseness, dysphagia, phrenic nerve paralysis, and Horner's syndrome.¹

Occasionally, patients suffer acute haemorrhage into the goitre, which may cause a sudden, potentially fatal, tracheal obstruction.³ Rarely, jugular vein thrombosis, cardiovascular steal syndrome, and even superior vena cava syndrome can occur.⁴ Imaging modalities include chest X-ray showing superior mediastinal widening, often unilateral, with or without tracheal deviation or narrowing.

Computed tomography of the neck and thorax is the gold standard technique for evaluation of the mediastinal masses. Needle biopsy is recommended only if there is local expertise available for establishing pre-op diagnosis. Selective angiography is also a useful tool confirming the origin and extent of aberrant vasculature of the mass.

Differential diagnosis of posterior mediastinal goitre can vary greatly and should be differentiated from neurogenic tumour, vertebral lesion, bronchogenic cyst, etc.

Surgical excision should be performed as early as possible once diagnosed, especially in symptomatic cases or when malignancy is suspected.⁵

CONCLUSION

In this relatively rare case a successful complete resection of a right posterior mediastinal goitre, following 30 years post-total cervical thyroidectomy was conducted. Adequate exposure and complete surgical excision are mandatory for asymptomatic goitres of the posterior mediastinum.

Overall, the recurrence of a thyroid ectopic mass following thirty years post-total cervical thyroidectomy is extremely rare and to our knowledge only two similar cases have been reported in the available literature.

Funding: No funding sources

Conflict of interest: None declared

Ethical approval: Not required

REFERENCES

1. Samokhvalov A, Loberant N, Makhoul N. Posterior mediastinal goitres: report of two cases and

- literature overview. *Respir Med Case Rep.* 2012;5:65-8.
2. Perrot MD, Fadel E, Mercier O, Furhamand P. Surgical Management of Mediastinal Goiters: when is a sternotomy required. *Thoracic Cardiovascular Surgeon.* 2007;55(1):33-43.
 3. Torres A, Arroyo J, Kastanos N. Acute respiratory failure and tracheal obstruction in patients with intrathoracic goiter. *Crit Care Med.* 1983;11:28:265-6.
 4. Ulreich S, Lowman RM, Stern H. Intra-thoracic goiter: a cause of superior vena cava syndrome. *Clin Radiol.* 1977;28:663-5.
 5. Zhao H, Liu RDY, Li X, Wu Y, Cheng G, Cheng J. Complete trans-thoracic resection of giant posterior mediastinal goitre: case report and review of surgical strategies. *Onco Targets Therapy.* 2016;9:2415-9.

Cite this article as: Fesatidou M, Fesatidou V, Tsoulfas G, Fessatidis IT. Large posterior mediastinal goiter post total cervical thyroidectomy: a case report. *Int Surg J* 2020;7:2722-4.