

Original Research Article

A clinicopathological study and management of abdominal tuberculosis

V. V. Harika Majji, Santosh Raja Erabati*, Swetha B. M.

Department of Surgery, NRI Institute of Medical Sciences, Visakhapatnam, Andhra Pradesh, India

Received: 22 May 2020

Revised: 10 July 2020

Accepted: 10 August 2020

***Correspondence:**

Dr. Santosh Raja Erabati,

E-mail: santosherabati@yahoo.co.in

Copyright: © the author(s), publisher and licensee Medip Academy. This is an open-access article distributed under the terms of the Creative Commons Attribution Non-Commercial License, which permits unrestricted non-commercial use, distribution, and reproduction in any medium, provided the original work is properly cited.

ABSTRACT

Background: Tuberculosis is a major health problem in developing countries. In spite of considerable advances, abdominal tuberculosis still continues to be of paramount health issue in India, owing to its vague and non-specific presentation challenging the therapeutic skills of present day surgeon. Surgical intervention was frequently used in the past for diagnosis is not necessary and is reserved for complications like obstruction, perforation, fistula, or a mass which does not resolve with medical therapy.

Methods: 30 patients admitted in Department of Surgery satisfying the inclusion criteria from November 2015 to October 2017. Patients were selected on a prospective basis.

Results: In this study out of 30 patients, 16 patients were treated conservatively with anti-tubercular therapy (ATT) alone and 14 patients underwent surgical treatment. Out of 14 patients, 5 patients were operated on emergency basis and 9 were operated electively. Of the 5 emergency cases, 2 patients underwent resection anastomosis of small bowel, 1 patient underwent adhesiolysis, and 3 patients with hollow viscus perforation underwent perforation closure with peritoneal drainage.

Conclusions: Tuberculosis has become a resurgent global problem with increasing numbers of extrapulmonary manifestations, non-specific features of abdominal tuberculosis result in difficulty in establishing a diagnosis, hence prompt initiation of treatment that can be either medical management or a surgical procedure is important to prevent morbidity and mortality associated with it.

Keywords: Abdominal tuberculosis, Gastrointestinal tract, Extra pulmonary

INTRODUCTION

Tuberculosis (TB) is a major health problem, in developing countries where overcrowding, poor sanitation and malnutrition are prevalent.¹

Abdominal tuberculosis is defined as infection of the peritoneum, hollow or solid abdominal organs with *Mycobacterium tuberculosis* which often results in granuloma formation, caseation, mucosal ulceration, fibrosis and scarring.² The peritoneum and the ileocecal region are the most frequent sites of involvement.

Major pathophysiological mechanisms proposed are hematogenous spread, swallowing of infected sputum, ingestion of contaminated milk or food and contiguous spread from adjacent organs.³

Abdominal tuberculosis can be classified into gastrointestinal TB (ulcerative, hyperplastic, fibrosis and diffuse colitis type), peritoneal TB (acute and chronic tubercular peritonitis), TB of mesentery (cyst, adenitis, abscess, bowel adhesions, rolled up omentum), TB of solid viscera (liver, biliary tract, gall bladder and pancreas) and retroperitoneal lymph node TB.⁴

Symptoms and signs are often quite vague laboratory investigations and radiological findings are sometimes inconclusive.

Management of abdominal TB is still controversial. Surgical intervention which was frequently used in the past for diagnosis is not necessary and is reserved for complications such as obstruction, perforation, fistula, or a mass.

This study is intended to study the etiology, clinico pathological manifestations, various sites of involvement and complications of abdominal TB and also to study the various surgical and medical modalities of treatment in the management of abdominal TB.

Aims and objectives of the research were to study: the age and gender incidence, etiological factors and various clinical manifestations of abdominal TB, various sites of involvement of abdominal TB and various surgical and medical modalities of treatment in the management of abdominal TB.

METHODS

This is a clinical study of 30 diagnosed cases of abdominal tuberculosis admitted in a tertiary care centre during the period of November 2015 to October 2017 were the source of data.

Study design

Prospective cross sectional study.

Procedure

The sample size was calculated by taking confidential level 95%, margin of error 5% and population proportion 50%.

Statistical analysis

All statistical analysis were performed by using Statistical Package for the Social Sciences (SPSS) trail version 20 and Microsoft Excel 2007.

Inclusion criteria

All patients admitted with investigations diagnosed with abdominal TB of peritoneum, mesentery, small and large intestine, solid viscera of the abdomen and retroperitoneal lymph nodes.

All patients presenting with various manifestations and complications of abdominal TB.

Exclusion criteria

Pregnant women with abdominal TB.

RESULTS

The observation is based on the analysis of the data pertaining to 30 cases abdominal TB and summarized in the tables below.

Table 1: Distribution of sample by age and gender.

Age (in years)	No. of cases	Gender	
		Male	Female
< 20	3	2	1
20 - 30	12	6	6
30 -40	6	5	1
40 - 50	2	1	1
50 - 60	3	2	1
> 60	4	2	2
Total	30	18	12

Table 2: Distribution of sample by symptoms.

Symptoms	No. of cases	%
Pain abdomen	29	96.7
Fever	10	33.3
Vomiting	15	50.0
Distension	6	20.0
Mass abdomen	5	16.7
Loss of weight	7	23.3
Loss of weight and appetite	10	33.3
Altered bowel habits	10	33.3
Cough	6	20.0

Patients were subjected to radiological investigations and majority were subjected to ultrasonography of abdomen and pelvis, 29 cases (96.7%) had abnormal findings such as ascites (15 cases), mesenteric lymphadenopathy (14 cases), sub-acute intestinal obstruction (8 cases), thickened bowel loops (7 cases), omento-peritoneal thickening (2 cases), small bowel stricture (1 case) and tubercles on bowel surface (1 case). Findings in chest x-ray were seen in 6 cases (20%) and had findings of opacity in 5 cases and 1 case with bilateral pleural effusion with pulmonary consolidation with fibrosis.

Erect x-ray abdomen was performed in all patients and 14 cases (46.7%) had abnormal findings such as dilated bowel loops (9 cases), multiple air fluid levels (2 cases), and gas under diaphragm (3 cases). The remaining 16 cases had a normal finding.

Computed tomography (CT) and contrast-enhanced computed tomography (CECT) of abdomen and pelvis were performed in 3 cases and all of them had positive findings such as small bowel stricture, mesenteric lymphadenopathy and ascites.

Patients in this study series were investigated with barium studies, 4 cases (13.3%) and laparoscopy, 4 cases (13.3%)

and colonoscopy, 1 case (3.3%) and biopsy of omentum or mesentric lymph nodes following laproscopy or endoscopy or laprotomy, 9 cases (30%) and all these cases subjected to the above mentioned investigations showed positivity of the results or in other words 100% of the patients showed findings suggestive of abdominal tuberculosis.

Out of 30 cases in this study series, 15 cases were investigated with adenosine deaminase levels in ascitic fluid or in blood all 15 cases (50%) showed increased levels.

Only 1 case (3.3%) in this study series was found to have human immunodeficiency virus (HIV) reactive status while the remaining 29 cases (96.7%) were HIV non-reactive.

Table 3: Distribution of sample by clinical diagnosis.

Diagnoses	No. of cases	%
Ileo-cecal TB	11	36.7
TB abdomen	9	30.0
TB ascites	6	20.0
TB abdomen + hollow viscus perforation	3	10.0
Cecal TB	1	3.3
Total	30	100.0

The patients in this study series were treated conservatively with anti-tubercular therapy (ATT) in 16 patients (53.3%) and 14 patients (46.7%) underwent surgery as the primary treatment under the cover of ATT.

Out of the 14 surgeries performed in this study series, 5 cases were performed on emergency basis as the patients had acute presentation and 9 cases were performed on selective basis.

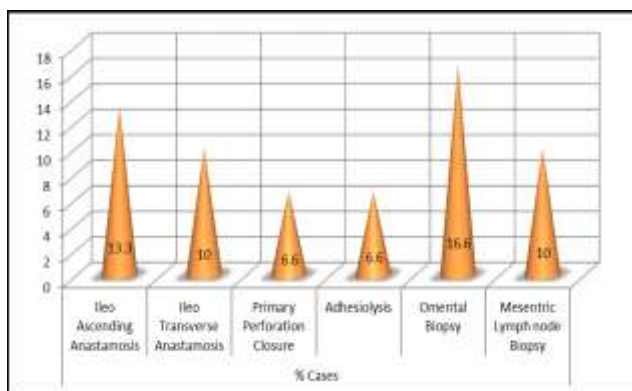


Figure 1: Distribution of sample by various surgeries performed.

All the cases included in this study series were followed up over the period of 2 years and all the patients were started on anti-tubercular therapy according to Revised National Tuberculosis Program (RNTCP).

In this study series 28 cases (93.3%) had completed ATT and are symptom free and 2 cases (6.7%) continue to be on ATT and are on regular follow up.

Table 4: Distribution of sample by intraoperative findings.

Operative findings	No. of cases	%
Ileo-cecal TB	5	16.7
Distal ileal perforation	2	6.7
Fecal peritonitis	3	10.0
Omental thickening	3	10.0
Omental adhesions	2	6.7
Tubercles on bowel surface	7	23.3
Mesentric lymph node	3	10.0
Small bowel adhesions	4	13.3
Terminal ileal stricture	3	10.0
Distal jejunal perforation	1	3.3

DISCUSSION

Global burden of TB is nearly 12 million. According to World Health Organization report 2013, there were an estimated 8.6 million annual incidence of TB globally and 1.3 million people died from disease in 2012.^{5,6}

Abdominal TB is more common in young adults. In the present study, 60% cases were in the age group 21-40 years.

In a study by Sircar et al age at presentation was variable with maximum cases in 21 to 40-year age group (58% of cases) with a mean age of 32.7 years.⁷ Sharma in 2003 reviewed literature and stated that two thirds are in age group 21-40.⁸

Maximum cases were seen in low socio economic status (SES) with 85% in below poverty line (BPL) strata. This correlates with findings of previous studies like Arunima et al 2016 who reported 92% occurrence in low SES respectively.⁹

Majority of the cases were female 60% in the present study.

Presenting symptoms in abdominal TB vary widely and are non-specific. It may mimic any intra-abdominal disease and can challenge the diagnostic skills. In present study pain abdomen was the most common symptom seen in 96.7% cases.

In study by Urabinahatti et al 2016. 75% cases had distension of abdomen. Bowel disturbance was observed in 33.3% cases, which is comparatively similar to previous studies.⁹

In present study 23.3% patients had pulmonary tuberculosis with active pulmonary tuberculosis in 6% and

past history of pulmonary tuberculosis in 17.3%. The present study is significantly comparable with that of Bhansali et al.¹⁰

In developed countries, there is low incidence of tuberculosis, but now as there is a rise in HIV infection, the incidence of tuberculosis has risen. In this present study 3.3% of patients had HIV positivity which was detected by enzyme-linked immunosorbent assay (ELISA) method. Extra-pulmonary TB especially abdominal TB is closely associated with HIV.

In this study, 6.7% of patients presented with acute intestinal obstruction had multiple air fluid level findings on plain x-ray abdomen and 10% patients presented with perforative peritonitis had free gas under the diaphragm findings on plain X ray abdomen. These patients underwent emergency surgical procedures.

The incidence of intestinal obstruction and perforative peritonitis in patients with intestinal tuberculosis has been reported as 12% to 60% and 1% to 10% respectively by Chuttani et al (1985).¹¹ Out of 30 patients in this study series 4 patients (13.3%) were subjected to barium studies and revealed findings of irregularity in the ileocecal region, distortion of the ileocecal angle, increased transit time of the barium, flocculations and segmentations in the ileal loops and terminal ileal stricture.

The patients in this study series were subjected to CECT of abdomen and pelvis and 10% of the patients had features of abdominal tuberculosis such as mesenteric lymphadenopathy with caseous necrosis appearing as low attenuating lesions with necrotic centres and inflammatory rim, ascites, terminal ileal stricture and thickened bowel loops.

In present study, peritoneal TB was most common, seen in 40% cases which include ascites (22.5%), adhesions (15%) and omental TB (2.5%), followed by ulcero sclerotic gastro intestinal TB in 32.5% cases, hyperplastic gastro intestinal TB in 27.5%.

Ileocecal region was the most common site of involvement with 57.5% occurrence. In a similar study by Shetty in 2006, hyperplastic TB was seen in 18.3% cases, sclerotic type in 36%, ascitic type in 44.7% and ulcerative in 8% cases.¹²

In this study out of 30 patients, 16 patients were treated conservatively with ATT alone. These include 6 with TB ascites, 4 with mesenteric lymphadenopathy and omental thickening, 5 with ileocecal TB and 1 with cecal TB alone.

In this study series 14 patients (46.7%) underwent surgical treatment. Out of these 14 patients, 5 patients were operated in emergency and 9 were operated electively.

Of the 5 emergency cases, 2 patients (6.6) underwent resection anastomosis of small bowel, 1 patient (3.3%)

underwent adhesiolysis, and 3 patients (10%) with hollow viscus perforation underwent perforation closure with peritoneal drainage. Initiating ATT if there is high index of suspicion for ileocecal TB based upon clinical, radiologic, and endoscopic findings, despite non diagnostic histological and/or bacteriological studies of biopsies.

Others suggest prompt diagnostic exploratory laparotomy in the absence of a definitive non operative diagnosis. In patients with compatible ileocecal lesions and a history of exposure to TB, strong positive purified protein derivative (PPD) skin test, evidence of TB on chest x-ray, or those originating from an endemic region, Wagner et al favoured initiation of antituberculous therapy. They exhibit rapid response to medical therapy if improvement is not seen within two weeks, laparotomy may be reconsidered.

Limitations

Limitations include: single-center, relatively small sample size excluding patients who were pregnant; TB polymerase chain reaction (PCR) and culture was not done in all patients owing to the financial constraints; and though the CRP is an ideal surrogate marker to assess the response to ATT, its serial measurement was not done.

CONCLUSION

The diagnosis of abdominal tuberculosis should be reached by a combination of clinical, laboratory, radiographic, pathological findings, and screened for HIV in view of frequent coexistence. Owing to its non-specific and vague presentations, a high index of suspicion should be raised and an attempt to intervene early should be made unless proven otherwise to decrease the morbidity and mortality associated with the late diagnosis and management. Surgeons may find themselves operating on a Pandora's box where peritonitis, unresolved bowel obstruction or suspected bowel ischemia are associated with signs of systemic sepsis that cannot be explained by the non-specific CT findings. Extreme vigilance and early management are the key in the management of abdominal TB.

Funding: No funding sources

Conflict of interest: None declared

Ethical approval: The study was approved by the Institutional Ethics Committee

REFERENCES

1. Butt T, Karamat KA, Ahmad RN, Mahmood A: Advances in diagnosis of tuberculosis. *Pak J Pathol.* 2001;12:1-3.
2. Sharma MP, Bhatia V. Abdominal tuberculosis. *Indian J Med Res.* 2004;20305-15.
3. Horvath KD, Whelan RL. Intestinal tuberculosis: Return of an old disease. *Am J Gastroenterol.* 1998;93(5):692-6.

4. Mann CV, Russel RCG, William NS, editors. Bailey and Love's short practice of surgery-London: English Language Book Society. 1995.
5. Debi U, Ravisankar V, Prasad KK, Sinha SK, Sharma AK. Abdominal tuberculosis of the gastrointestinal tract: Revisited. *World J Gastroenterol.* 2014;20(40):14831-40.
6. World Health Organization. Global tuberculosis report 2013. Geneva: WHO. 2013. Available at: http://apps.who.int/iris/bitstream/10665/91355/1/9789241564656_eng.pdf. Accessed on: 20 June 2020.
7. Sircar S, Taneja VA, Kansra U. Epidemiology and clinical presentation of abdominal tuberculosis-a retrospective study. *J Indian Med Assoc.* 1996;94:342-4.
8. Sharma MP, Bhatia V. Abdominal tuberculosis. *Indian J Med Res.* 2004;20305-15.
9. Urabinahatti KA, Singh AK, Nayak A, Gupta R, Jain M, Dubey C, et al. Abdominal tuberculosis: an epidemiological profile and management of 40 cases in a tertiary set up. *Int Surg J.* 2016;3:1502-84.
10. Bhansali SK. Abdominal tuberculosis. Experiences with 300 cases. *Am J Gastroenterol.* 1977;67:324-37.
11. Chuttani HK, Sarin SK. Intestinal tuberculosis. *Ind J Tube.* 1985;32:117.
12. Setty G. Clinico Pathological Study of Abdominal Tuberculosis. Bangalore: RGUHS; 2006.

Cite this article as: Majji VVH, Erabati SR, M SB. A clinicopathological study and management of abdominal tuberculosis. *Int Surg J* 2020;7:3262-6.