

Case Series

A case series of adult intussusception diagnosed by ultrasound in South India: an uncommon notion

D. Vinoth, S. Rajeshkumar*, Sheik Asik Abu Sali

Department of General Surgery, PSG Institute of Medical Sciences and Research, Coimbatore, Tamil Nadu, India

Received: 18 April 2020

Revised: 25 May 2020

Accepted: 28 May 2020

***Correspondence:**

Dr. S. Rajeshkumar,

E-mail: rajeshpollachi74@gmail.com

Copyright: © the author(s), publisher and licensee Medip Academy. This is an open-access article distributed under the terms of the Creative Commons Attribution Non-Commercial License, which permits unrestricted non-commercial use, distribution, and reproduction in any medium, provided the original work is properly cited.

ABSTRACT

Intussusception is the telescoping of one segment of the gastrointestinal tract into an adjacent one. Adult intussusception is less than 0.1% of all hospital admissions. Non-specific symptoms often delay the diagnosis with most cases diagnosed only after emergency laparotomy, hence the need for imaging as a screening investigation. The gold standard is computed tomography with the limitations of cost, radiation and contrast hazards. Our suggested initial screening tool is ultrasound. The aim of this study was to evaluate the sensitivity of ultrasound in diagnosing this rare entity. Thirteen patients (2013 to 2019) in a single tertiary care hospital diagnosed as “intussusception” were analysed. They were initially diagnosed by ultrasound and confirmed by CT or intra-op as needed. There were no exclusion criteria. The mean age was 50. There were 6 males and 7 females. Ultrasound sensitivity was 72%. Symptoms were variable. 100% had abdominal pain (1 day to 2 years duration). 69% had Intestinal obstruction. The most common type of adult intussusception observed was ileo-ileal (39%). The least common noted was gastro-jejunal (8%). The most common treatment was resection and anastomosis (77%). 3 cases were managed conservatively successfully. The biopsy was mostly benign (54%), 3 were malignant (23%) and 3 were unknown as they were not operated (23%). Our suggested initial screening is ultrasound with a fairly good sensitivity (72%). The upcoming improvement in technology can raise this sensitivity even further. The management protocols, biopsy findings, and clinical findings are however subjected to discretion.

Keywords: Adult, Intussusception, Ultrasound, Diagnosis

INTRODUCTION

Intussusception is the telescoping of one segment of the gastrointestinal tract into an adjacent one.¹ Any focus of an intraluminal irritant such as inflamed mucosa or a mass lesion may act as a lead point and the resulting hyperperistaltic activity causes a segment of bowel (intussusceptum) possibly along with its mesentery to telescope into the adjacent distal bowel lumen (intussusciens).² Adult intussusception is classified according to the location of the lead point as entero-enteric, ileocolic, ileocecal, and colo-colic.

Paediatric intussusception is more common and they are easily identified because they present typically with intermittent colicky pain, abdominal mass and passage of dark clots mixed with mucus.³ Intussusception, compared to the paediatric population, is an infrequent cause of bowel obstruction in adults, with only two to three cases occurring in a population of 1,000,000 per annum, accounting for less than 0.1% of all adult hospital admissions.⁴⁻⁶ There is thus a low suspicion of intussusception due to vague range of acute to longstanding or intermittent non-specific symptoms which delays the diagnosis.^{3,7} Most cases are diagnosed only after emergency laparotomy.⁸ In non-emergency

situations, the diagnosis can be even more challenging as very vague symptoms including intermittent abdominal pain that often settles comparatively quick along with the often-negative clinical examinations and investigation probably labelled these patients as having irritable bowel syndrome.

As their causes may be benign, physiological or even a transient phenomenon with no apparent underlying disease, diagnosis of such entities needs more sophisticated approach with compulsory screening imaging.⁹ There is a need for pre-op diagnosis because ninety percent of adult intussusception (AI) patients harbour a pathological process in contrast to the majority of paediatric patients where the cause is benign.⁴ Thus, a definitive management planning is needed preop because, unlike the paediatric population where in almost 80% of the patients, non-surgical therapies such as pneumatic or hydrostatic reductions is sufficient to treat this condition, surgical management however, remains the mainstay treatment modality for a majority of patients with AI as malignancy has to be ruled out.

The initial screening investigation ideally is a contrast enhanced computed tomography (CECT) abdomen. But considering the disadvantages of cost, radiation exposure and need for contrast where patients with renal failure are at risk are the limitations. Ultrasound on the other hand has a limited cost and no radiation or contrast hazards can be considered as the initial screening investigation so that the need for computerized tomography (CT) can be limited to equivocal cases. In a poor economic situation as observed in South India, people would welcome ultrasound rather than CT for as the first investigation for screening of this rare entity. Hence, the aim of this study was to evaluate the sensitivity of ultrasound in diagnosing this rare entity.

CASE SERIES

This is a case series of thirteen patients over the age of 20 with both outpatient and emergency department surgical consultation for “intussusception” at our single tertiary care hospital over a seven year period (2013-2019). These patients were initially diagnosed with ultrasound with or without being confirmed by an additional CT scan as needed. There were no exclusion criteria. We specifically aimed to correlate ultrasound sensitivity with intra-op findings. The clinical features, diagnostic studies, surgical findings, surgical management and final pathology were reviewed from the medical charts and are discussed. The findings were analysed.

Case 1

We present a case of small bowel intussusception due to an underlying submucosal polypoidal growth in an otherwise well 78 years old lady who presented to our outpatient department with diffuse abdominal pain for 8 days and constipation on and off for the past 5 years.

There was no history of nausea or vomiting. On examination, her vitals were stable. Per abdominal examination reveal mild diffuse tenderness over the abdomen. Initial ultrasound abdomen revealed cholelithiasis, bilateral small kidneys with a small 5mm stone in left kidney. She immediately improved with analgesics and was discharged on OPD basis.

Two days later she again presented to emergency department with increased intensity of abdominal pain, distention of abdomen and obstipation for the past two days. On general examination, she was conscious, oriented, with mild discomfort. Her heart rate was 88 bpm, BP was 143/77 mmHg and oxygen saturation was 97% in room air. Her abdomen was soft, distended, with diffuse tenderness present. There was no hepatosplenomegaly, no visible peristalsis, no guarding or rigidity and her bowel sounds were sluggish. Her haemoglobin was 12.9g/dl, total counts was 5.6 cells/cu mm, liver function test, serum amylase and serum lipase was normal.

X-ray abdomen revealed multiple air fluid levels. Repeat ultrasound was suggestive of obstruction secondary to a small bowel intussusception Figure 1 (a and b). She was taken up for laparotomy, and the radiological findings were confirmed. Reduction of the intussusception and a small bowel resection and end to end anastomosis was performed. Figure 1 (c and d) shows the resected specimen. She made an uneventful postoperative recovery. The histopathology revealed an inflammatory pseudo tumour of the small bowel as a lead point for a small bowel intussusception.

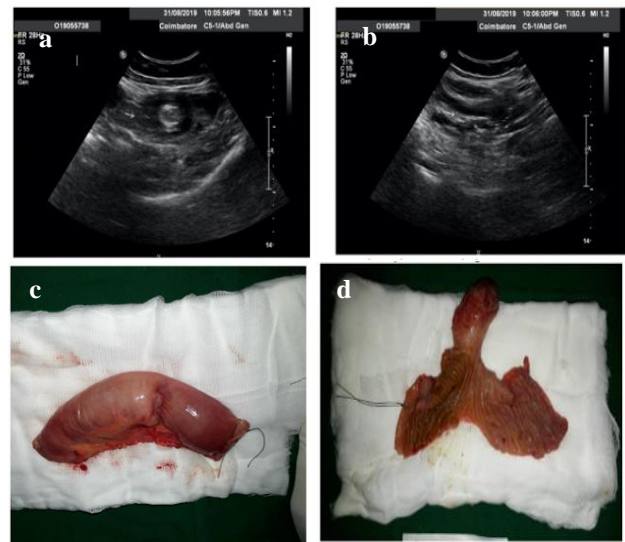


Figure 1: (a) Depicts ultrasound showing the target sign, (b) depicts ultrasound showing intussusception in long axis view, (c) depicts the reduced resected specimen of intussusception, and (d) shows the cut section of the specimen revealing the inflammatory pseudotumour.

Case 2

A 34 years old lady, with no known comorbidities, presented with complaints of abdominal pain for the past 3 days confined to upper abdomen which was sudden in onset, continuous and radiating to right hypochondrium, associated with melena for past 2 days. There was also history of multiple episodes of vomiting. On admission, her vitals were stable. Haemoglobin was 8.4 g/dl. Peripheral smear was suggestive of iron deficiency anaemia. Ultrasound abdomen revealed telescoping of bowel loops in right iliac fossa suggestive intussusception. CT abdomen done revealed Ileo-ileal intussusception in left mid abdomen in mid-ileal loops with haziness and stranding in adjacent mesenteric fat planes. On table she was found to have ileo-ileal intussusception 30 cm from ileo-caecal junction with Meckel's diverticulum being the lead point. Wedge resection with ileo-ileal anastomosis was done and the biopsy confirmed the same.

Case 3

A 55 years old lady, a known case of diabetes mellitus and seizure disorder, presented with abdominal discomfort following food intake for the past 2 months associated with occasional vomiting. Upper gastro intestinal scopy which was done 1-month back was normal. On admission, her vitals were stable. Abdomen had mild diffuse tenderness. Ultrasonography (USG) was suggestive of intussusception (Figure 2a), CT abdomen confirmed intussusception at jejunum level. She underwent exploratory laparotomy with jejunum resection and anastomosis (Figure 2b). Biopsy confirmed the lead point to be a jejunal lipoma.

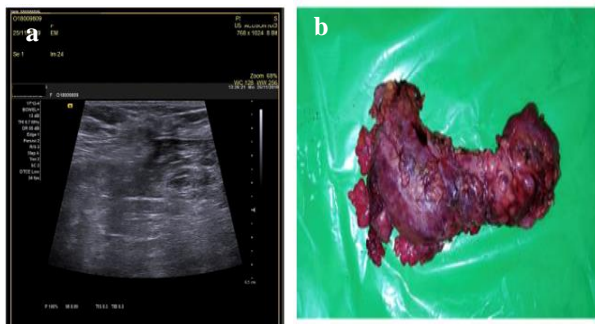


Figure 2: (a) Depicts ultrasound showing the Donought sign and (b) shows the resected specimen.

Case 4

A 54 years old lady presented with recurrent colicky abdominal pain with multiple episodes of bilious vomiting for the past 10 days. Her pulse rate was 110 bpm, abdomen was soft, mildly distended with increased bowel sounds. Routine blood investigations were within normal limits. Ultrasound abdomen was suggestive of focal dilatation of ileal loops with adjacent inflammatory

changes in right lower abdomen. To confirm, contrast enhanced CT was done which revealed short segment of bowel within bowel appearance with surrounding inflammatory changes in distal ileal loop and dilatation of proximal ileal loop likely intussusception. Initially laparoscopy was planned, but as she had distended jejunal loops with Intussusception of mid ileum into ileum causing obstruction, it was converted to open Figure 3 (a and b). She underwent segmental resection and side to side anastomosis. On cut specimen, 1.5 cm pedunculated benign polyp was found in lumen.

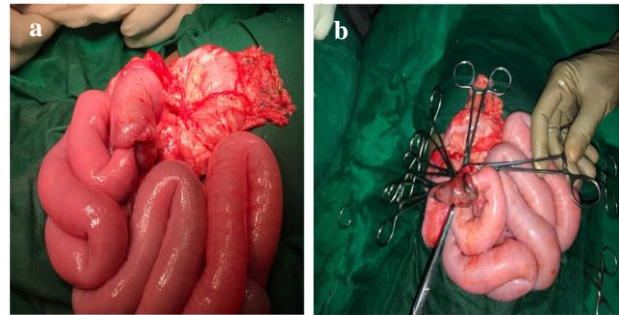


Figure 3: (a) Intra operative picture of ileo-ileal intussusception and (b) intra-operative picture of ileo-ileal intussusception partially reduced.

Case 5

A 36 years old gentleman, presented with history of jejuno-jejunal intussusception 3 weeks back for which he underwent resection with end to end anastomosis. Biopsy was suggestive of Peutz-Jegher's syndrome.

Post resection upper GI endoscopy was done, which revealed multiple gastric and duodenal polyps with healed ulcer and pseudodiverticulum at D1 level. Colonoscopy was also done post op which revealed multiple polyps and biopsy from the polyp confirmed Peutz-Jegher syndrome.

Case 6

A 56 years old lady, a known case of diabetes mellitus and hypothyroidism, presented with intermittent dull aching type of abdominal pain which was present on and off for past 4 months. She had loss of appetite. On admission, her vitals were stable. Routine investigations were within normal limits. Ultrasound abdomen revealed long segment ileo-colic intussusception with a hypoechoic mass a lead point in the epigastric region Figure 4 (a and b). Intra-operative, she was found to have intussusception from ileum up to the level of transverse colon with significant proximal bowel dilatation. On cut open the specimen, a polypoidal mass of size 6.5×4.5×3 cm was noted in ileal loop. She underwent right hemi colectomy (Figure 4c) with end to side ileocolic anastomosis. Histopathology was suggestive of myosarcoma.

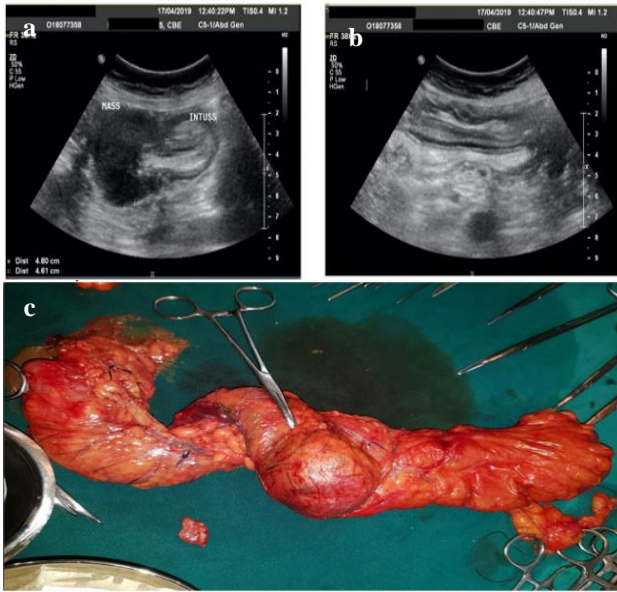


Figure 4: (a) Depicts the ultrasound showing the mass and intussusception, (b) depicts the ultrasound showing the intussusception in long axis view, and (c) depicts the resected specimen.

Case 7

A 32 years old gentleman, a known diabetic, presented with dull aching abdominal pain and loose stools for past 7 days. Pain was relieved after defecation. On admission, his vitals were stable. USG abdomen revealed focal small segment of bowel within bowel appearance in the left iliac region possibly transient small bowel intussusception. He was managed conservatively, and he responded well. His pain reduced and was tolerating the restarted oral feeds. Repeat USG abdomen was found to be normal and he was discharged.

Case 8

An 87 years old gentleman, presented with epigastric pain with belching and increased frequency of 7 to 8 bowel habits per day for one month. There was no history of significant weight loss or loss of appetite. On admission, his vitals were stable, per-abdomen was soft with mild epigastric tenderness. There was a vague mass in the right hypochondrium. His haemoglobin was 8.4 g/dl with peripheral smear suggestive of iron deficiency anaemia. USG abdomen suggested possible colo-colic intussusception in right hypochondrium Figure 5 (a and b). CT abdomen was done which revealed circumferential wall thickening in caecum, ascending colon up to hepatic flexure of colon with intussusception at that level with a polypoidal lesion as a lead point (Figure 5c).

He underwent colonoscopy which confirmed an ascending colon growth, transverse colon ulcers and left sided diverticulosis. Biopsies taken from the growth revealed adenomatous polyp with high grade dysplasia. CECT chest and USG abdomen done were negative for

metastasis. CEA was within normal limits. He underwent laparoscopic right hemi colectomy with side to side ileo-transverse colonic anastomosis as planned pre-op. Intra-operatively, a mass was found in caecum with intussusception of the terminal ileum. There was neovascularization from the para colic gutter in the region of mass with sub centimetre nodes along ileocolic pedicle. Histopathological report suggestive of T3N0Mx mucinous adenocarcinoma with perineural invasion and 33 nodes were negative for tumour deposits.

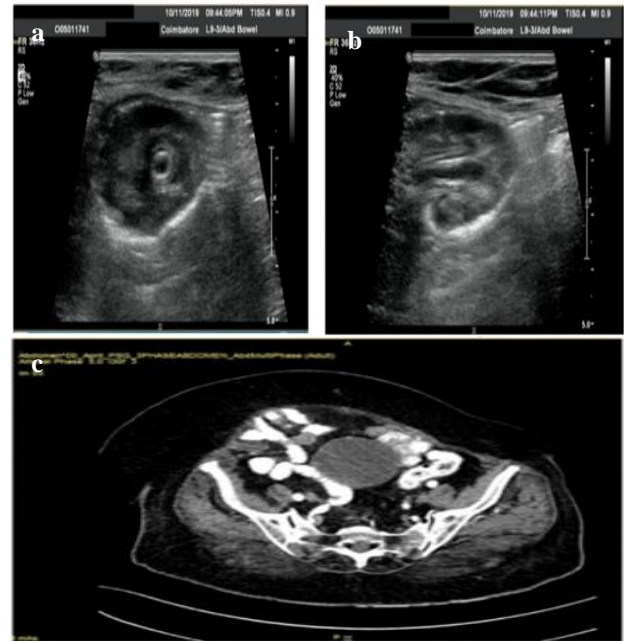


Figure 5: (a) Depicts ultrasound showing the target sign, (b) depicts ultrasound showing intussusception in long axis view, and (c) depicts CECT abdomen showing ileocolic intussusception.

Case 9

A 34 years old lady, presented with abdominal pain relieved with medication for past 2 months. For the past 5 days, the pain was increasing in intensity and was associated with vomiting and constipation for 4 days. On admission, her heart rate was 110bpm. Her abdomen was soft with tenderness in the umbilical and epigastric region. There was no mass palpable. Routine blood investigations were within normal limits. USG abdomen was suggestive small intestinal obstruction with thickening in lower abdomen. She underwent laparoscopic small bowel resection anastomosis (Figure 4) intraoperatively, she was found to have small bowel intussusception 2 feet from DJ flexure. Histopathology was suggestive of intestinal lipomatosis.

Case 10

A 20 years old gentleman, presented with right lower quadrant abdominal pain on and off for the past 4 days associated with 3 episodes of vomiting, 4 episodes of

loose stools and continuous low-grade fever for past 2 days suggestive of acute appendicitis. Blood investigation were within normal limits. USG abdomen was suggestive of ileo-colic intussusception with mesenteric lymphadenitis in right iliac fossa.

Patient refused surgery and left against medical advice. He came back after two days and repeat USG abdomen was done which was suggestive of mesenteric lymphadenitis with no evidence of ileocolic intussusception. He was thus managed conservatively; his persistent fever spikes were found to be due to dengue which was also managed conservatively. He responded well, was symptomatically better, started on orals and discharged.

Case 11

A 60 years old gentleman was diagnosed to have focal segmental ischemia of proximal jejunum with hyperplastic polyp of distal stomach 3 weeks back for which distal gastrectomy, segmental resection of jejunum and Roux-en-Y gastro jejunostomy with feeding jejunostomy was done with an uneventful post op period. Now he presented to us with bilious vomiting for past 2 days associated with mild left lower quadrant abdominal pain and obstipation. On admission, his vitals were stable, abdomen was mildly distended. X-ray abdomen erect revealed dilated stomach. Ryle tube was inserted and retained copious food residue was aspirated.

He was evaluated with gastro-graaffin study done with contrast given via oral route and via feeding jejunostomy tubes which suggested retention of oral contrast in the dilated stomach with no entry into jejunum. The flow in the feeding jejunostomy tube however, was uninterrupted till the descending colon. Stomal obstruction was suspected and OGD scopy after stomach wash was done, which revealed evidence of resolving gastro-jejunal intussusception and patent stoma. As it was resolving, He was managed conservatively with prokinetics and responded well. He was started on orals and progressed satisfactorily to normal diet over 4 days without recurrence of symptoms.

Case 12

A 44 years old lady, presented with sudden onset and progressive colicky abdominal pain more confined towards right iliac fossa since afternoon aggravated with food intake and associated with 2 episodes of vomiting. On arrival, her vitals were stable. screening investigation were inconclusive and emergency diagnostic laparoscopy was done, which revealed a dilated loop of small bowel. Midline laparotomy was done.

Intra-op there was an ileo-ileal intussusception about 15cm proximal to ileo-caecal junction. Manual reduction was tried but failed, so resection and anastomosis were done. Biopsy revealed lipoma as lead point

Case 13

A 59 years old gentleman, presented with intermittent abdominal pain for the past 2 years, worsened for the past one week, which was associated with post prandial vomiting and bloating. On arrival, his vitals were stable. Abdomen was mildly distended. His blood investigations were within normal limits. UGI scopy revealed H. pylori negative pan gastritis, active duodenitis and grade one GERD with deformed duodenum along with a small diverticulum. USG abdomen revealed intussusception of small bowel in lower abdomen with a large, well defined hypoechoic mass as a lead point. CECT abdomen confirmed a well-defined mass lesion within the loop of ileum in left lower abdomen causing luminal distention and ileo-ileal intussusception with in-drawing of small bowel mesentery proximal to the lesion. He was taken up for small bowel resection and anastomosis. Intra-operatively found to have jejuno-jejunal intussusception with mass measuring 7×5cm. Histopathology report suggestive of inflammatory myofibroblastic tumour (inflammatory pseudo tumour).

DISCUSSION

The first report of intussusception was made in 1674 by Barbette of Amsterdam.¹⁰ Intussusception or “introsusception” as it was called then, was in addition detailed in 1789 by John Hunter.¹¹ In 1871 Sir Jonathan Hutchinson was the first to successfully operate on a child with intussusception.¹² Diagnosis in all cases is however crucial.

Most studies commit computed tomography as the most reliable investigation in making a preoperative diagnosis, especially in those patients with non-specific abdominal pain in whom the diagnosis can be difficult.¹³ Other investigations like ultrasonography, barium enema, colonoscopy or flexible sigmoidoscopy, upper GI series, can be used according to the clinical situation.¹⁴ In a poor country, however a CT may not be welcomed as the first mode of investigation. Hence the importance of a cheaper alternative. Ultrasound is well established as the first-line imaging modality for diagnosing intussusception in children.⁴ In children, ultrasound may be 98-100% sensitive and 88-89% specific in diagnosing intussusception.⁴ Adults are more difficult to image with ultrasound, due to adverse features of overlying bowel gas and abdominal fat, as well as there being a relatively greater accessibility of CT imaging, which is often the modality of choice to investigate the wide range of potential causes for abdominal symptoms. However, studies have shown that for adult intussusception, the sensitivity of ultrasound was comparable. Though there are not many studies to directly compare, one study shows ultrasound has 98-100% sensitive and 88-89% specific in diagnosing adult intussusception.¹⁵ Our study showed ultrasound had a sensitivity of 72%. As there were no disease negative cases, specificity could not be calculated.

Table 1: Comparing all case reports.

Case number	Age/sex	Duration of abdominal pain	Suggestive of intestinal obstruction	Ultrasound findings confirm intussusception	Confirmed by CT	Site of intussusception	Management	HPE
1	78/F	8 days	Yes	Yes	CT not done	Ileo-ileal	Resection and anastomosis	Inflammatory pseudo tumour
2	34/F	3 days	Yes	Yes	Yes	Ileo-ileal	Resection and anastomosis	Meckels diverticulum
3	55/F	2 months	No	Yes	Yes	Jejuno-jejunal	Resection and anastomosis	Jejunal lipoma
4	54/F	Recurrent	Yes	No	Yes	Ileo-ileal	Resection and anastomosis	Pedunculated polyp
5	36/M	3 days	Yes	Not done	Yes	Jejuno-jejunal	Resection and anastomosis	Polyp due to Peutz-Jegher syndrome
6	56/F	4 months	No	Yes	CT not done	Ileo-colic	Right hemicolectomy with end to side anastomosis	Polyp due to myosarcoma
7	32/M	7 days	No	Yes	CT not done	Ileo-ileal	Conservatively managed	Nil
8	87/M	1 month	No	Yes	Yes	Ileo-colic	Laparoscopic right hemicolectomy	Mucinous adenocarcinoma
9	34/F	2 months	Yes	No	CT not done	Jejuno-jejunal	Resection and anastomosis	Intestinal lipomatosis
10	20/M	4 days	Yes	Yes	CT Not done	Ileo-colic	Conservatively managed	Nil
11	60/M	2 days	Yes	Not done	CT not done	Gastro-jejunal	Conservatively managed	Nil
12	44/F	1 day	Yes	No	CT not done	Ilio-ileal	Resection and anastomosis	Lipoma
13	59/M	2 years	Yes	Yes	Yes	Jejuno-jejunal	Resection and anastomosis	Inflammatory myofibroblastic tumour (inflammatory pseudo tumour)

Of the 8 cases positive by ultrasound, 6 cases were confirmed intra-op and the other 2 cases were confirmed clinically by their recovery. The ultrasound features are similar in all age groups as noted in our study. Features on ultrasound include a typical 'target lesion' or 'pseudo-kidney' appearance on longitudinal imaging.^{1,4}

The 'target lesion' demonstrates concentric layers of different echogenicities, which correspond to the oedematous bowel wall and central invaginated mesenteric fat.^{2,8} In our study, the ultrasound features for adult intussusception was similar to paediatric age group. So far, studies have given the efficacy of ultrasound in diagnosing, but most of them attribute CT as a better investigation.¹⁵ A study comparing CT and ultrasound revealed that appearances of intussusception were similar in both and moreover in CT, in addition identified complications such as perforation, obstruction or bowel wall ischemia. In our study, CT was done in 6 cases and all were confirmed intra-operatively thereby giving a sensitivity of 100%. Similarly, all the cases diagnosed in ultrasound was confirmed intra-operatively and clinically. Hence whether the use of the ultrasound alone is feasible for selecting patients for laparotomy in an emergency setting is an object of debate in itself. The benefits of a proper diagnosis by ultrasound was noted in case number 8, where the preop screening was confirmed and proper staging was done resulting in a satisfactory management. Case number 5 and 6 could have been managed differently had a proper preop investigation been done.

The mean age was 50. There were 6 males and 7 females. The presenting symptoms in adult patients with intussusceptions are non-specific (Table 1) and often long standing. Most series report pain as the commonest symptom, being present in 71% to 90% of patients, with vomiting.¹⁶ This also correlated with our findings (all 13 presented with abdominal pain). In the review article by Azar et al, the mean duration of symptoms between onset and presentation was 37.4 days (range 1-365 days). The duration of symptoms was longer in patients with benign and enteric lesions compared with those with malignant and colonic lesions.⁴ In our study, similarly the range was even wider (1 day to 2 years).

Intussusception in adults differs from those in children in various aspects. The single most common site is the small bowel. Coloanal intussusceptions are rare and usually occur in the setting of a benign or malignant tumour.¹⁷ Gastroduodenal intussusception, the least frequent of all, is usually caused by the prolapse of a benign gastric tumour into the duodenum, with subsequent invagination of a portion of the stomach wall.¹⁸ In our study also, the most common site is small bowel and the least common gastro-jejunal. The lead points for the intussusceptions are attributable to benign, malignant, or idiopathic causes. Idiopathic intussusception in the small bowel accounts for 8% to 20% of all cases.¹¹ Most of our patient had mass as a lead point which was benign (54%).

Adult intussusception warrants laparotomy rather than attempts at hydrostatic reduction in view of the high incidence of underlying abnormality.^{3,15} Controversy remains as to whether reduction of the intussuscepting lesion should be attempted at operation. Early reports advocated reducing the intussusception before resection. The perceived disadvantage of this is that malignant cells may be disseminated during the process despite the fact the no clear evidence is there on this issue. On the other hand, the advantages of reducing the intussusception especially when the small bowel is affected are that it may be possible to preserve considerable lengths of bowel and thereby prevent development of short bowel syndrome. Begos et al suggest resection without attempting reduction when the bowel is inflamed, ischemic, or friable and in obvious cases of colo-colic intussusception (given the high likelihood of malignancy).¹⁴ In all other cases reduction should always be attempted initially. However, Azar et al suggested that surgical resection without reduction is the preferred treatment in adults, as almost 50% of both colonic and enteric intussusceptions are associated with malignancy.⁴ Simple reduction is however acceptable in post-traumatic and idiopathic intussusceptions where no pathological cause is usually present in the bowel. In our study, 10 cases (77%) were managed with surgical resection and 3 (23%) were successfully managed conservatively.

CONCLUSION

Intussusception in adults is an infrequent problem. The diagnosis of this condition can be difficult as symptoms are often non-specific and episodic. It is important to have a high index of suspicion. The gold standard investigation is abdominal computed tomography with the limitations of cost, radiation and contrast hazards. Our suggested initial screening tool however is ultrasound with a fairly good sensitivity (72%). More studies comparing sensitivity of CT with ultrasound in adult intussusception are needed. The upcoming improvement in technology can raise the sensitivity even further. The management protocols, biopsy findings, and clinical findings are however subjected to discretion.

Funding: No funding sources

Conflict of interest: None declared

Ethical approval: Not required

REFERENCES

1. Gayer G. Intussusception in adults: CT diagnosis. *Clin Radiol.* 1998;53:53-7.
2. Gordon RS. Intussusception in adults: a rare disease. *J Emerg Med.* 1991;9:337-42.
3. Wang LT, Wu CC, Yu JC, Hsiao CW, Hsu CC, Jao SW. Clinical entity and treatment strategies for adult intussusceptions: 20 years' experience. *Dis Colon Rectum.* 2007;50:1941-9.
4. Azar T, Berger DL. Adult intussusception. *Ann Surg.* 1997;226:134-8.

5. Brayton D, Norris WJ. Intussusception in adults. *Am J Surg.* 1954;88:32-43.
6. Kim YH. Adult intestinal intussusception: CT appearances and identification of a causative lead point. *Radiographics.* 2006;26:733-44.
7. Suhaibani YA, Mohamed A, Bhat N, Abukhater M. Adult Intussusception, a Rare Cause of Intestinal Obstruction, Case Report and Literature Review. *Int J Surg.* 2009;24:2.
8. Donhauser DL, Kelly EC. Intussusception in the adult. *Am J Surg.* 1950;79:673-7.
9. Yakan S, Caliskan C, Makay O, Denecli AG, Korkut MA. Intussusception in adults: clinical characteristics, diagnosis and operative strategies. *World J Gastroenterol.* 2009;15:1985-9.
10. Barbette P. *Ouvrages Chirurgiques at Anatomiques.* Geneva: Francois Miegé; 1674.
11. Hutchinson J. A successful case of abdominal section for intussusception. *Proc R Med Chir Soc.* 1873;7:195-8.
12. Nesbakken A, Haffner J. Colo recto anal intussusception: case report. *Acta Chir Scand.* 1989;155:201-4.
13. Wiot JF, Spitz HB. Small bowel intussusception demonstrated by oral barium. *Radiology.* 1970;97:361-6.
14. Begos DG, Sandor A, Modlin IM. The diagnosis and management of adult intussusception. *Am J Surg.* 1997;73:88-94.
15. Rafailidis V. A case of adult intussusception with greyscale, contrast enhanced ultrasound and computerised tomography correlation. *Ultrasound.* 2017;25(2):120-5.
16. Stubenord WT, Thorblamarson B. Intussusception in adults. *Ann Surg.* 1970;172:306-10.
17. Lin F, Setya V, Signor W. Gastro duodenal intussusception secondary to a gastric lipoma: a case report and review of literature. *Am Surg.* 1992;58:772-4.
18. Weilbaeher D, Bolin JA, Hearn D. Intussusception in adults: review of 160 cases. *Am J Surg.* 1971;121:531-5.

Cite this article as: Vinoth D, Rajeshkumar S, Sali SAA. A case series of adult intussusception diagnosed by ultrasound in South India: an uncommon notion. *Int Surg J* 2020;7:2363-70.