

Case Report

You are not yourself when you are hungry: a rare case of malignant insulinoma

Maria Joao Amaral^{1,2*}, Henrique Alexandrino^{1,2,3}, Daniela Meireles⁴,
Rui Caetano Oliveira⁵, Marco Serodio^{1,2}, Jose Guilherme Tralhao^{1,2,3}

¹Department of General Surgery, Centro Hospitalar e Universitário de Coimbra, Coimbra, Portugal

²Faculty of Medicine, University of Coimbra, Coimbra, Portugal

³Coimbra Institute for Clinical and Biomedical Research (iCBR) area of Environment, Genetics and Oncobiology (CIMAGO), Faculty of Medicine, University of Coimbra, Coimbra, Portugal

⁴Department of Internal Medicine, Centro Hospitalar do Baixo Vouga, Aveiro, Portugal

⁵Department of Pathology, Centro Hospitalar e Universitário de Coimbra, Coimbra, Portugal

Received: 03 April 2020

Revised: 08 June 2020

Accepted: 09 June 2020

*Correspondence:

Dr. Maria Joao Amaral,

E-mail: mariajoaoamaral@hotmail.com

Copyright: © the author(s), publisher and licensee Medip Academy. This is an open-access article distributed under the terms of the Creative Commons Attribution Non-Commercial License, which permits unrestricted non-commercial use, distribution, and reproduction in any medium, provided the original work is properly cited.

ABSTRACT

We present a rare case of high-grade functional neuroendocrine carcinoma of the pancreas secreting insulin. Our patient, an 80 years old woman, presented with neuropsychiatric symptoms consistent with hypoglycaemia that regressed with food intake and dextrose administration. Abdominal imaging showed a pancreatic tumour with invasion of the spleen and lymph node metastasis, highly suggestive of an insulinoma as the cause of the hypoglycaemia. The patient underwent left pancreatectomy with splenectomy and atypical gastric resection. The postoperative course of our patient was uneventful, with complete remission of the hypoglycaemic episodes, and the definitive histological examination showed three poorly differentiated large cell neuroendocrine carcinomas of the pancreas.

Keywords: Hypoglycaemia, Neurobehavioral manifestations, Neuroendocrine carcinoma, Insulinoma

INTRODUCTION

Pancreatic neuroendocrine tumours (NETs) compromise less than 2% of all malignancies and are mostly non-functional 50-70%. Of those that are functional, they are predominantly insulinomas and gastrinomas.¹

Insulinoma is a pancreatic NET with an incidence of 4 cases per 1 million person-years and less than 10% of the cases are malignant.²⁻⁴ Four features of insulinoma are associated with four 90% parameters: 90% are benign, 90% are solitary, 90% occur in the pancreas and 90% are less than 2 cm in diameter.⁴ Diagnosis is based on symptoms of hypoglycaemia (endogenous hyperins-

ulinism), which are the main clinical manifestation and are responsible for the morbidity of this tumour.^{2,4,5} Benign and malignant tumours are difficult to distinguish clinically and, to the affected patients, the control of glycaemia before surgery can be very problematic.^{3,6} Malignancy is defined by the presence of metastases that, most commonly, are in the liver or lymph nodes.^{2,3} Surgery is the only curative treatment of malignant insulinomas.²

We present a rare case of a neuroendocrine carcinoma (NEC) with phenotypical behaviour of malignant insulinoma causing neuropsychiatric symptoms that relieved with food ingestion.

CASE REPORT

An 80 years old woman was admitted to the emergency department (ED) with a two-month history of morning episodes of aggressive behaviour, periods of temporospatial disorientation, asthenia, polyphagia and nocturnal diaphoresis. These symptoms occurred mostly in the fasting state and alleviated by the ingestion of food. She denied abdominal pain, nausea, vomiting, diarrhoea or flushing.

The patient had a history of atrial fibrillation, toxic multinodular goitre, arterial hypertension, dyslipidemia and degenerative osteoarticular disease, being medicated with rivaroxaban, carvedilol, thiamazole, bromazepam, atorvastatin and acemetacin. She denied any relevant family history.

Neurological examination was normal. At the ED, the head computed tomography (CT) was normal and she had a blood glucose level of 38 mg/dl. Hypertonic glucose 30% was administered to normalize glucose concentration and a perfusion of glucose at 5% was maintained afterwards. The patient was admitted for further investigation.

Investigations

Blood analysis showed a glucose level of 79 mg/dl with perfusion of glucose at 5% and, after stopping the glucose perfusion, the insulin level was 26.9mUI/l (r.v. 3-25) and C-peptide was 6.08 ng/ml (r.v. 0.9-7.1); FSH (follicle-stimulating hormone) and LH (luteinizing hormone) were within normal values for her age, and the values of oestradiol, cortisol, prolactin and ACTH (adrenocorticotrophic hormone) were also normal. She had normal hepatic function tests and normal amylase and lipase values. Blood tests were repeated and the insulin level was 44mUI/l, C-peptide was 8.8ng/mL normal glucose level with perfusion of glucose at 5% and chromogranin A was 225 ng/ml (r.v. 19.4-98.1).

Abdominal CT scan (Figure 1), revealed an enlarged body and tail of the pancreas with an 80mm oval formation with heterogeneous enhancement after intravenous contrast administration, involving the splenic artery in several of its segments, although it remained patent; the mass extended to the splenic hilum with involvement of the respective hilar vessels and to the splenic parenchyma, where a vascularized 56mm hypodense formation was present, suggesting direct extension of the neoplasm to the splenic parenchyma. Two enlarged lymph nodes, one at the emergence of the celiac artery and the other one immediately below the pancreatic tail, were also apparent.

Further diagnostic investigations included a Ga-DOTA-NOC positron-emission tomography CT (PET-CT), which was highly suggestive of a NET of the pancreas (Figure 2), with high expression of somatostatin

receptors; splenic and gastric involvement were also suspected, as well as of regional lymph nodes. Given the constant need for intravenous dextrose perfusion and the inability of the patient to endure a significant fasting period, a decision was made to forego the performance of a F-fluorodeoxyglucose-PET-CT scan.¹⁸

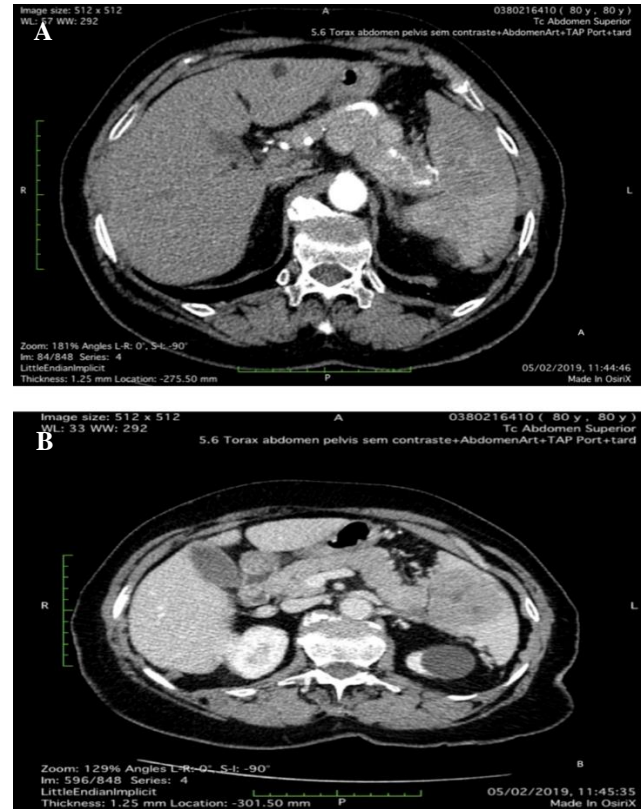


Figure 1: Computed tomography images of the patient (A) arterial phase, displaying a large hypovascular mass with hyper-vascular areas in the body and tail of the pancreas and (B) portal phase, demonstrating direct extension to the splenic parenchyma, as well as splenic vein obstruction.

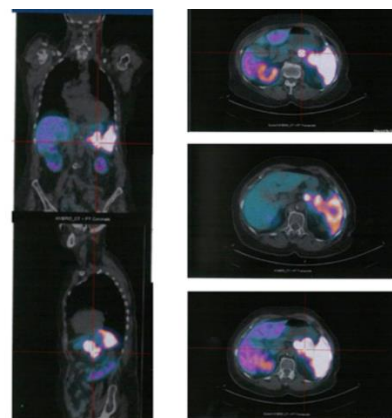


Figure 2: ⁶⁸Ga-DOTA-NOC positron-emission tomography CT (PET-CT) images tumour with a high expression of somatostatin receptors can be seen in the body and tail of the pancreas.

In this case, the imaging procedures were indicative of an insulinoma as the cause of the hypoglycaemic episodes. Insulinoma frequently presents with neuroglycopenia, which may cause confusion and abnormal behaviours, reversible with feeding, rather than the autonomic symptoms, typically associated with more common causes of hypoglycaemia.⁶

Treatment and outcome

After multidisciplinary meeting, the diagnosis of malignant pancreatic NET, with likely insulinoma-like secretory phenotype, was made based on clinical and imagological findings, and a decision for curative-intent surgery was proposed. Through a left transverse laparotomy with upper midline extension, abdominal exploration revealed a large mass in the body and tail of the pancreas, with direct extension to the splenic hilum and invasion of the gastric fundus, without signs of disseminated disease. Thus, a left pancreatectomy, splenectomy and a bloc atypical resection of the gastric fundus was performed.

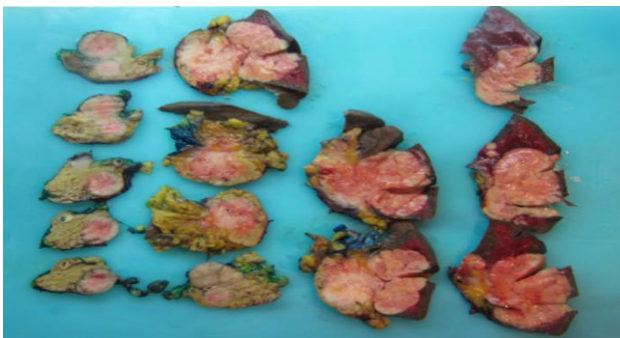


Figure 3: Serial sections reveal a pink and soft tissue mass, with invasion of the spleen.

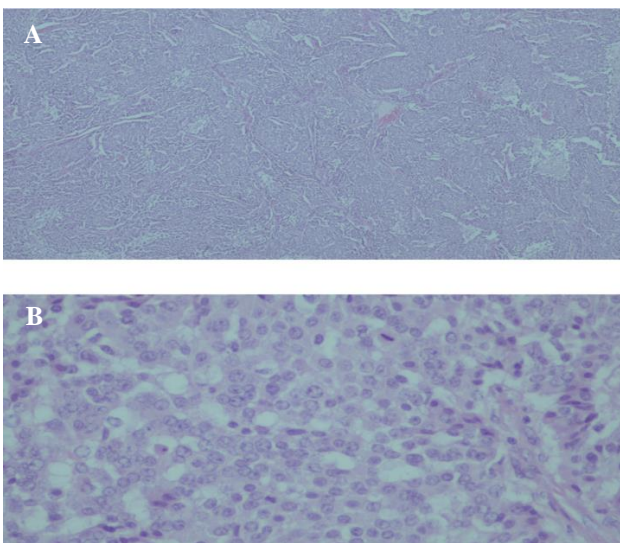


Figure 4: (A) Insular and trabecular neoplasm (40X magnification) and (B) the tumoral cells had eosinophilic cytoplasm, open coarse chromatin with mitosis (400X magnification).

On gross examination of the specimen there were three nodular lesions of the pancreas, one in the anterior part with 2.2 cm and other in the posterior pancreas with 2 cm; the larger lesion was located in the pancreatic body/tail and measured 6.5 cm. The latter tumour was composed by a pinkish tissue, of soft consistency and necrotic areas, and extended to the spleen and gastric fundus (Figure 3).

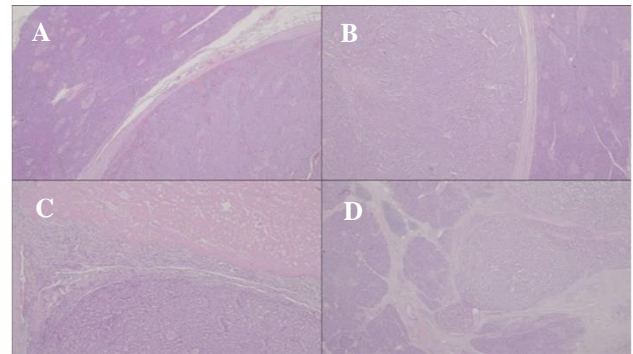


Figure 5: (A and B) expansive growth of the two smaller lesions, H and E (20X magnification), (C) necrotic areas in the large tumor, H and E (40X magnification), (D) infiltrative behaviour of the large tumour with invasion of the pancreatic adjacent tissue, and (E) H and E (20X magnification).

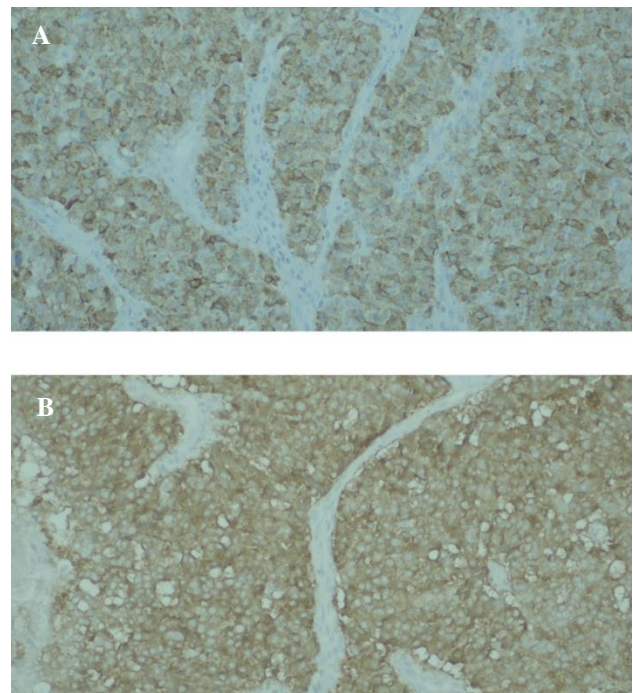


Figure 6: (A) Chromogranin A, granular and diffuse staining (200X magnification), (B) synaptophysin, and diffuse staining (200x magnification).

Histologic examination showed three large cell NEC, with lympho-vascular and perineural invasion (pTNM-T3 (3) N0) (Figure 4). The smaller tumours had expansive

growth (Figure 5), but the greater lesion exhibited partially a pseudo-capsule of fibrotic tissue, with disruption and invasion of splenic tissue and gastric fundus. The neoplastic cells expressed, strongly and diffusely, cam 5.2, synaptophysin and chromogranin A (Figure 6). The ki67 proliferative index of the greater lesion was 62% (Figure 7) and the mitotic rate was 25 per 10 high power field (HPF) (Figure 8). The smaller lesions had a Ki67 proliferative index superior to 40% (Figure 9). P53 was also overexpressed in all the three lesions.

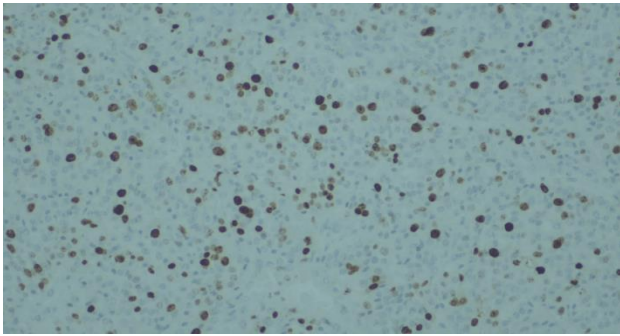


Figure 7: MIB1 (ki67) proliferative index 62% of the larger lesion (200X magnification).

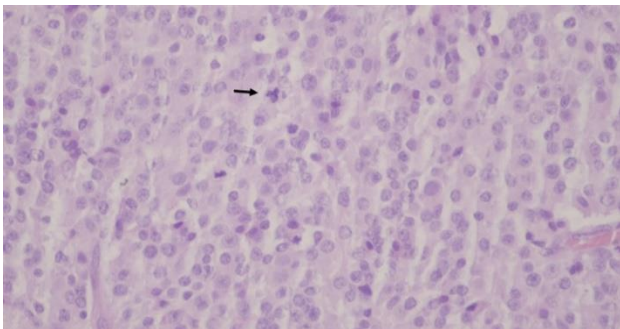


Figure 8: The larger nodule exhibited high mitotic activity, inclusively with atypical forms (arrow), H and E (400X magnification).




Figure 9: Ki67 proliferative index of the smaller lesions (200X magnification-A and 400x magnification-B).

The post-operative course was uneventful and there was complete remission of the hypoglycaemic episodes. Four weeks after surgery the patient experienced no symptoms

in the fasting state, and her blood tests were within normal values. On a subsequent multidisciplinary meeting no adjuvant therapy was decided, only continued surveillance.

DISCUSSION

Clinical hypoglycaemia occurs when the plasma glucose concentration is low enough to cause symptoms and/or signs, which include neurological symptoms, and insulinoma should be suspected in patients who manifest Whipple's triad.^{6,7} Our patient presented with periods of altered state of consciousness and aggressive behaviour that ceased after normalizing her blood glucose levels. This atypical presentation of hypoglycaemia is frequently mistaken for a neuropsychiatric disorder and often results in the missed or delayed diagnosis of the tumour, which leads to a delayed treatment and to the risk of progressive tumour growth, metastasis and death from severe hypoglycaemia.⁶

As stated before, an insulinoma is the most common cause of hypoglycaemia related to endogenous hyperinsulinism, and it usually is a benign and sporadic tumour. Although rare, it is the most common functioning NET of the pancreas and should always be considered in the differential diagnosis.^{7,8}

The 72 hours fasting test remains the gold standard for the diagnosis of insulinoma and includes the measurement of plasma glucose, insulin and C-peptide, at the time hypoglycaemic symptoms appear.⁸ Among non-invasive localization methods, CT yielded a sensitivity of 65-70%. As for somatostatin receptor imaging, it was reported to generate a positive rate of 30 to 50%, with an 85.7% sensitivity for malignant insulinoma.⁴ This is because insulinoma is usually benign and thus of small size, unlike the case we report.

Liver metastasis upon disease onset is the most common manifestation of malignant insulinoma. Rarely, malignancy is diagnosed at the time of recurrence, which occurs for only 2% of the insulinomas overall. The most common metastatic sites of malignant insulinoma are the abdomen, including the retroperitoneal lymph nodes and liver, while bone, lung or other sites are rare.⁴

Camara-de-Sousa et al suggested a particular approach to the patients with the following characteristics that suggest a malignant insulinoma; clinical history of less than 6 months; fasting time before hypoglycaemia less than 8 hours; insulin and C-peptide concentration ≥ 2 μ U/ml and ≥ 4 ng/dl at the glucose nadir, respectively, and a tumour ≥ 2.5 cm. CK19 status, the tumour staging and grading (ki67>2%) and the age of onset >50 years can also be considered indicators of malignancy.⁷ A very high level of chromogranin A and proinsulin may indicate greater potential for aggressive clinical behaviour, as well as a histological grade 3 or more invasive grade 2. Although these patients had shorter clinical presentations, the

diagnosis was late, when most of them already displayed disseminated disease.⁵ Our patient had a clinical history of only 2 months and the tumour had already invaded the spleen and stomach. We speculate whether the insulin production was an acquired phenotype by some cell clones of a pre-existing NET that was already growing to a considerable size. This can be suggested by the existence of hyper-vascular areas in the hypodense mass

on preoperative CT, as well as the three distinct tumours on the final pathology. Surgery is the first-choice therapy for resectable insulinomas and the only curative option.^{2,8} Even unresectable cases can benefit from a debulking surgery in the hope of controlling symptoms.⁹ Medical therapy can be useful both during the preoperative period and for preventing hypoglycaemia in insulinomas with unknown localization.⁸

Table 1: World health organization 2017 classification of the neuroendocrine neoplasm of the pancreas (adapted from).^{1,14}

Type	Differentiation status	Definition	Grade	Mitotic rate	Ki-67 staining (%)
NEN	Well differentiated	NET	G1	<2 per 10 HPF	<3
			G2	2-20 per 10 HPF	3-20
			G3	>20 per 10 HPF	>20
Mi NEN	Well/poorly differentiated	NEC	G3	>20 per 10 HPF	>20
		Small cell type Large cell type			

Abbreviations: NEN - neuroendocrine neoplasm; NET - neuroendocrine tumour; NEC - neuroendocrine carcinoma; Mi NEN - mixed non-neuroendocrine - endocrine neoplasm; HPF - high power field.

Possible options are diazoxide, somatostatin analogs and glucocorticoids.^{2,3,8} With our patient, we successfully prevented hypoglycaemic episodes with the use of continuous intravenous glucose infusion. Aggressive secondary therapies such as chemoembolization or radiofrequency ablation, in case of liver metastasis, should only be used to control hypoglycaemia.³

Our patient's case is rare. What seemed like an insulinoma, turned out to be a high-grade NEC of the pancreas at histological and immunohistochemical examination (Table 1). Traditionally, grade 3 NEC are considered non-functional.¹ To our knowledge this is the second reported case of functional insulin producing high-grade NEC, presenting with symptoms of hypoglycaemia.¹⁰ In our literature search, we have also found a high-grade functional NEC of the pancreas secreting vasoactive intestinal peptide.¹

The existence of three nodules is also very interesting. They could represent independent lesions or be a part of the same lesions with foci of intrapancreatic dissemination.¹¹ Similar morphology, high Ki67 proliferative index as well as the P53 overexpression in all the tumours provide some support to the latter theory and genetic study could provide more information regarding common mutations of clonal evolution.

However, it was not performed due to the lack of next generation sequencing techniques in our institution. Intrapancreatic metastasis is described for pancreatic ductal adenocarcinoma so it is reason to believe that the same phenomenon can happen with pancreatic NEC.¹²

The five years survival rate for malignant insulinomas was described to be 55.6% and the ten years survival rate has been reported to be 29%.^{4,6} For NEC, the overall 5

years survival of the patients is 17%.¹³ Thus, long-term follow-up is mandatory.

Recurrence of the tumour after surgery, either in the form of liver metastases or insulinomatosis, is usually accompanied by hypoglycaemia, therefore these patients should continue doing daily glucose levels measurements.⁴

CONCLUSION

Malignant insulinoma is rare and the main clinical manifestations are hypoglycaemia-related symptoms. De novo neuropsychiatric symptoms, particularly arising in the fasting state and alleviated by the ingestion of food, should prompt the suspicion of insulinoma, although they can be easily misdiagnosed as a primary neurocognitive process.

Also, this case shows that NEC of the pancreas can rarely have the potential to produce functional peptide hormones and intrapancreatic metastasis probably can occur. Surgery helps controlling symptoms of hypoglycaemia, completely reversing the neuropsychiatric syndrome.

Funding: No funding sources

Conflict of interest: None declared

Ethical approval: Not required

REFERENCES

- Graham C, Chauhan A, Anthony L. Can a High-grade Neuroendocrine Carcinoma be Functional. *Am J Med Sci.* 2019;357(3):258-62.
- Garcia FJC, Cruz GVI, Solis NDS, Andres CM, Arino MC, Alfaro MA, et al. Management of

- malignant insulinoma. *Clin Transl Oncol.* 2013;15:725-31.
3. Hirshberg B, Cochran C, Skarulis MC, Libutti SK, Alexander HR, Wood BJ, et al. Malignant Insulinoma: spectrum of unusual clinical features. *Cancer.* 2005;104(2):264-72.
 4. Yu J, Ping F, Zhang H, Li W, Yuan T, Fu Y, et al. Clinical Management of Malignant Insulinoma: a single Institution's experience over three decades. *BMC Endocr Disord.* 2018;18(1):92.
 5. Camara-de-Souza AB, Toyoshima MTK, Giannela ML, Freire DS, Camacho CP, Lourenço JDM, et al. A retrospective study analysing the differences between benign and malignant tumours. *Pancreatology.* 2018;18(3):298-303.
 6. Varela D, Yu A, Saxon D. Insulinoma Masquerading as Transient Neurocognitive Impairment. *Am J Med.* 2018;131(9):377-9.
 7. Caliri M, Verdiani V, Mannucci E, Briganti V, Landoni L, Esposito A, et al. A case of malignant insulinoma responsive to somatostatin analogs treatment. *BMC Endocr Disord.* 2018;18(1):98.
 8. Okabayashi T, Shima Y, Sumiyoshi T, Kozuki A, Ito S, Ogawa Y, et al. Diagnosis and management of Insulinoma. *World J Gastroenterol.* 2013;19(6):829-37.
 9. Mathur A, Gorden P, Libutti SK. Insulinoma. *Surg Clin North Am.* 2009;89(5):1105-21.
 10. Sandoval MA, Pagsisihan D, Berberabe A, Lopez PEG. A malignant cause of hypoglycaemia: a metastatic insulin-secreting pancreatic neuroendocrine carcinoma. *BMJ Case Rep.* 2016;2016:2016214702.
 11. Crippa S, Partelli S, Belfiori G, Paluccci M, Muffatti F, Adamenko O, et al. Management of neuroendocrine carcinomas of the pancreas (WHO G3): A tailored approach between proliferation and morphology. *World J Gastroenterol.* 2016;22(45):9944-53.
 12. Fujita Y, Kitago M, Masugi Y, Tano O, Shinoda M, Abe Y, et al. Two cases of pancreatic ductal adenocarcinoma with intrapancreatic metastasis. *World J Gastroenterol.* 2016;22(41):9222-8.
 13. Fukushima N. Neuroendocrine Neoplasms of the Pancreas: The Pathological View Point. *J Pancreas.* 2018;3:328-34.
 14. Inzani F, Petrone G, Rindi G. The New World Health Organization Classification for Pancreatic Neuroendocrine Neoplasia. *Endocrinol Metab Clin N Am.* 2018;47(3):463-70.

Cite this article as: Amaral MJ, Alexandrino H, Meireles D, Oliveira RC, Serodio M, Tralhao JG. You are not yourself when you are hungry: a rare case of malignant insulinoma. *Int Surg J* 2020;7:2378-83.