

Original Research Article

Step up approach for the management of late presentation of pancreatic trauma patients

Shabi Ahmad, Vikram Singh*, Vinod Kumar Pandey, Shirish Kumar,
Tabrej Alam, Prakhar Pratap

Department of Surgery, Motilal Nehru Medical College, Allahabad, Uttar Pradesh, India

Received: 25 February 2020

Revised: 04 March 2020

Accepted: 05 March 2020

*Correspondence:

Dr. Vikram Singh,

E-mail: vikramsingh812922@gmail.com

Copyright: © the author(s), publisher and licensee Medip Academy. This is an open-access article distributed under the terms of the Creative Commons Attribution Non-Commercial License, which permits unrestricted non-commercial use, distribution, and reproduction in any medium, provided the original work is properly cited.

ABSTRACT

Background: Pancreatic injuries are usually subtle to identify by different diagnostic imaging modalities and these injuries are often overlooked in cases with extensive multi-organ trauma. Our study was conducted to evaluate the outcome of a step-up approach in the management of pancreatic trauma patients with late presentation.

Methods: The study included 15 patients who presented with grade III AAST delayed presentation of pancreatic trauma from September 2017 to 2019. In our step-up approach 2 staged procedure was done, firstly laparotomy with necrosectomy along with closure of proximal pancreatic duct with external drainage of pancreatic duct, in second stage Roux-en-Y pancreaticojejunostomy was done to drain the remnant pancreas as a definitive procedure 3 to 6 months after initial procedure.

Results: In our study, blunt trauma abdomen (83.30%) (n=10) was the most common mode of injury. The main reason for delay in diagnosis of pancreatic trauma was delayed presentation of patient (83.3%) (n=10). Total of 4 patients were admitted to intensive care unit (ICU) at the time of admission. 10 patients underwent both the stages of step up approach management among which one patient had pancreatic fistula as a complication (n=1) (10%) and one patient had post-operative abscess as a complication (n=1) (10%). No mortality was noted in our study.

Conclusions: The step-up approach discussed above proves to be beneficial towards management of patients with delayed presentation of pancreatic trauma in our setting.

Keywords: Pancreatic trauma, Step-up approach, ICU

INTRODUCTION

The pancreas is a relatively uncommon organ to be injured in trauma, occurring in less than 2% of blunt trauma cases, and this injury is associated with considerably high morbidity and mortality in cases of delayed diagnosis, incorrect classification of the injury, or delays in treatment.^{1,2} Mortality for pancreatic injuries ranges from 9% to 34%; however, only 5% of the pancreatic injuries are directly related to the fatal outcome. Physical examination is usually not reliable in the setting of acute pancreatic trauma.³ Early and accurate

diagnosis can decrease morbidity and mortality, and various imaging modalities play a key role in recognition of pancreatic injuries.^{4,5}

Knowledge about the mechanisms of pancreatic injury, the presence of coexisting injuries, the time to diagnosis, the presence or absence of major ductal injury, and the roles of various imaging modalities is essential for prompt, early and accurate diagnosis. Early detection of disruption of the main pancreatic duct is of paramount importance because such disruption is the main cause of delayed complications like pseudo pancreatic cyst.⁶ The

most common site of traumatic pancreatic injury is at the junction of the body and tail. Significant pancreatic injury may occur in the absence of abnormality on various imaging modalities.

Pancreatic trauma occurs commonly in connection with multiple injuries after motor vehicle accidents in adults and bicycle handlebar injuries in children.⁷ Conservative management is mainly advocated for pancreatic trauma without ductal injuries. Computed tomography (CT) is routinely used as the first-line imaging modality in acute abdominal trauma cases and is helpful in recognizing injuries to the pancreas and other organs and their associated complications.⁸ Ultrasonography (US) is useful in cases of pancreatic ascites and pseudocyst formation, which are more likely to occur in cases with traumatic pancreatitis.^{3,9} Magnetic resonance cholangiopancreatography (MRCP) allows direct imaging of the pancreatic duct and its disruption.¹⁰

Pancreatic injuries are classified and graded according to the damage to the pancreatic parenchyma and the ductal system. Grading of pancreatic injuries enables an exact description of injuries, can influence management, and allows a comparison of outcomes and effective quality control of treatment.¹¹ There are several classification systems of traumatic pancreatic injuries.^{12,13} but the pancreatic organ injury scale (OIS) proposed by the American association for the surgery of trauma (AAST) fulfils most of these criteria and at present is the universally accepted classification scheme.¹⁴

Table 1: American association for the surgery of trauma classification of pancreatic trauma.

Grade	Injury	Description
I	Hematoma	Minor contusion without ductal injury
	Laceration	Superficial laceration without ductal injury
II	Hematoma	Major contusion without ductal injury or tissue loss
	Laceration	Major laceration without ductal injury or tissue loss
III	Laceration	Distal transection or pancreatic parenchymal injury with ductal injury
IV	Laceration	Proximal transection or pancreatic parenchymal injury involving the ampulla
V	Laceration	Massive disruption of the pancreatic head

Reproduced from Campbell et al.¹⁵

Our study was conducted to evaluate the outcome of a step-up approach in the management of pancreatic trauma patients with respect to morbidity, mortality and reestablishment of normal pancreatic duct anatomy.

METHODS

The study was carried out in P.G. department of surgery, M.L.N. medical college, Allahabad from September 2017 to 2019 which included 15 patients who presented with grade III AAST delayed presentation of pancreatic trauma. The diagnosis of pancreatic trauma and duct disruption was supported and done by CECT abdomen.

Study description

Our conducted study is a facility based prospective observational study which was conducted over a period of 2 years, from 1 September 2017 to 31 September 2019 in post-graduate department of surgery, M.L.N. medical college, Allahabad (U.P.). Patients who presented with grade III AAST classified pancreatic trauma were included in our study. In total of 15 patients were included in the study having grade III pancreatic trauma.

Our step-up approach included two stage intervention. In the first stage laparotomy with necrosectomy done along with closure of proximal pancreatic duct with non-absorbable suture with external drainage of pancreatic duct, in the second stage Roux-en-Y pancreaticojejunostomy was done to drain the remnant pancreas as a definitive procedure 3 to 6 months after initial procedure.

The patients were followed up for a period of minimum 6 months in order to note the complications and the outcome of the step-up approach done. A total of 15 patients were enrolled in the study satisfying the inclusion criteria with the late presentation of pancreatic trauma with associated duct disruption among which three patients were lost to follow up after the initial procedure of necrosectomy and did not underwent definitive procedure. 2 patients are currently in the awaited group for the definitive procedure.

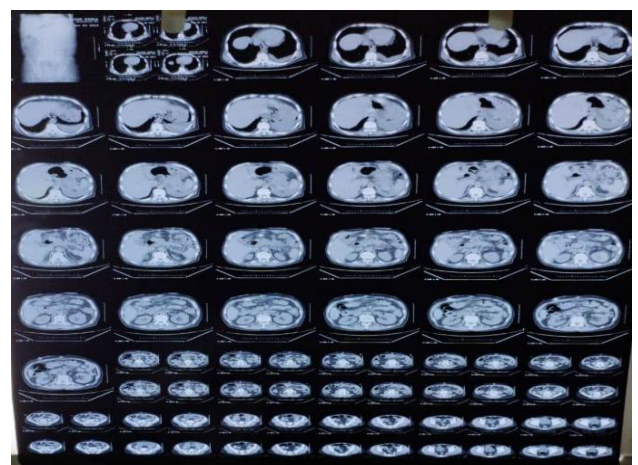


Figure 1: CECT whole abdomen preoperatively showing pancreatic duct injury.

RESULTS

In our study, majority of patients were male (75%) (n=9) and females constituting to 25% of study population.

Table 2: Distribution of patients according to gender.

Sex	Study population N (%)
Male	9 (75)
Female	3 (25)
Total	12(100)

Table 3: Distribution of patients according to age.

Age (years)	Study population N (%)
31-40	9 (75)
41-50	1 (8.3)
51-60	1 (8.3)
>60	1 (8.3)
Total	12(100)

In our study, majority of the patients were in the age group of 31 to 40 years with average age of the patient was 35±10 years.

The most common presenting complaint of the patient of late pancreatic trauma was abdominal pain constituting 75% of the total study population with nausea and vomiting being the second most common presenting complaint followed by dyspnoea.

Table 4: Distribution of patients according to mode of injury.

Mode of injury	Study population N (%)
Blunt trauma	10 (83.3)
Penetrating trauma	1 (8.3)
Unknown	1 (8.3)
Total	12 (100)

Table 5: Distribution of patients according to coexisting medical disorder.

Coexisting medical disorder	Study population N (%)
Cardiovascular disorders	2 (16.6)
Pulmonary disorders	2 (16.6)

In our study, blunt trauma abdomen was the most common mode of injury of the pancreatic trauma constituting to 83.3%. The main reason for delay in diagnosis of pancreatic trauma was delayed presentation of patient constituting as 83.3% (n=10) of the total study population.

In our study total of 4 patients had coexisting medical disorders out of 12 patients with 2 patients having

cardiovascular disorder and 2 having pulmonary disorders.

Table 6: Distribution of patient according to grade of ASA on admission.

Grade of ASA on admission	Study population N (%)
Grade I	11 (91.6)
Grade III	1 (8.33)
Total	12 (100)

In our study majority of patients were in grade I ASA classification of the patient constituting 91.6% of the total study population.

Table 7: Complications of step up approach.

Complication	Study population N (%)
Pancreatic fistula	1 (10)
Abscess	1 (10)
Total	2/10 (20)

Out of total study population of 12 patients, 10 patients underwent both the stages of step up approach management among which one of the patients had pancreatic fistula as a complication (n=1) (10%) and one patient had post-operative abscess as a complication (n=1) (10%).

One patient among the 2 patients in the awaited group had complaint of prolonged pancreatic discharge for more than 5 and half months as a complication (Figure 2 below). Prolonged pancreatic discharge subsided on its own without any active intervention.



Figure 2: Prolonged discharge from drain site.

DISCUSSION

Traumatic pancreatic injuries are rarely isolated to occur and are often associated with other intra-abdominal injuries. The choice of surgical procedure depends on the degree and site of the injury, and several surgical treatment options can be considered for the

pancreaticoduodenal injury according to the severity of the injury.

Pancreaticoduodenal injuries, although relatively rare, have a significant morbidity (36-60%) and mortality (18-23%).¹⁶⁻¹⁹ Similarly according to the study conducted by Recinos et al and Kao et al pancreatic trauma is associated with significant overall mortality and a complication rate of more than 60%.^{20, 21}

CT is the imaging study of choice in patients with hemodynamically stable closed trauma.²² Both the sensitivity and the specificity of the test are around 85% for the detection of pancreatic injury.²² However, the sensitivity to detect duct injury is more limited (43%–54%).^{23,24} A disadvantage of the technique is the need to determine the ideal moment, because immediately after blunt trauma the pancreas may appear normal in 20%–40% of cases, and if it is performed after the first 24 h the lesion may go unnoticed due to the absence of inflammatory reaction.^{22,25}

In our study, majority of patients were male (75%) (n=9) and the average age of the patient was 35±10 years, which is concurrent with the study conducted by Vasquez et al, Akhrass et al, and Cogbill et al where the age is less than 40 years in 80% of the cases and most of the patients are males.²⁶⁻²⁸

Our study data is also concurrent with the study conducted by Chinnery et al where the average age is 30.1±9.6 years.²⁹

In a study conducted by Benjamin et al total of 30 patients were analyzed with the mean age being 38±17 years and majority of them were male (74%) which is concurrent with our study.³⁰

The study conducted by Ragulin et al 27,216 nationally weighted patients with pancreaticoduodenal trauma were admitted in which nearly three-quarters of this cohort (73.6%) were male and the mean age of the patients was 37.7 years which is concurrent to our study.³¹

Out of the 12 patients who were analyzed in our study most of the patient (n=10) (83.3%) had blunt trauma to the abdomen as the most common mode of injury leading to pancreatic duct injury which is concurrent with the study conducted by Menahem et al, Wisner et al.^{32,33} In the review conducted by Petrone et al, the mechanism of injury in 1236 cases reviewed: 59.8% were due to a blunt mechanism, and 40.2% a penetrating mechanism which is concurrent to our study similarly in the study conducted by Ragulin et al blunt trauma abdomen was the most common mode of injury.^{34,31}

In the cases where diagnosis and treatment are delayed >24 h, mortality increases to 40% as compared with 11% for those diagnosed <24 h. Two-thirds of the patients who survive more than 48 hours end up with complications,

and 37% of deaths are late and are related to complications such as fistula, abscess, anastomotic breakdown, pancreatitis, pseudocysts and pneumonia.^{35,36}

There has been a significant change in the approach to the management of pancreatic injuries from complex procedures and towards simple drainage.³⁷ Drainage with the subsequent formation of a controlled pancreatic fistula carries a low mortality, has an acceptable morbidity and is preferred over complex procedures.³⁸

In our study complication rate was found to be 20% (n=2/10) where one patient developed pancreatic fistula and one patient developed postoperative abscess which is comparable to the study conducted by Wisner et al where the complication rate was 25%.³² However, in a study conducted by Chinnery et al 49% of the patients developed complications and 23% of patients died.²⁹

In a study conducted by Ragulin et al the most common complications were pulmonary compromise and infectious complications.³¹ In our study the incidence of pancreatic complication of pancreatic fistula and postoperative abscess formation stands equally at 10% each.

The incidence of pancreatic fistula (PF) ranges greatly due to the variability of definitions among authors. The international study group for pancreatic fistula proposed as a definition the abnormal communication between the pancreatic duct epithelium and another epithelial surface, and in the case of it being postoperative or after trauma, exteriorization through the drain tube.³⁹ The discharge is any measurable volume after the third day post-operative, with a level of amylase 3 times higher than in serum, and no need for radiological confirmation. The incidence of PF observed in study conducted by Petrone et al was 11%.³⁴ According to the experience of Young et al more PF occur during management with only drainage than after procedures with resection.⁴⁰ Major ductal injury is the principal determinant of outcome for patients with pancreatic trauma.

CONCLUSION

The step-up approach discussed above proves to be beneficial towards management of patients with delayed presentation of pancreatic trauma in our setting. With no mortality and easily manageable complications the step-up approach can prove to be breakthrough in the management of pancreatic trauma patients. Although further multicenter studies including large sample size can further substantiate this approach and results studied in the long term of follow up.

Funding: No funding sources

Conflict of interest: None declared

Ethical approval: The study was approved by the Institutional Ethics Committee

REFERENCES

- Cirillo RL, Koniaris LG. Detecting blunt pancreatic injuries. *J Gastrointest Surg.* 2002;6:587-98.
- Kao LS, Bulger EM, Parks DL, Byrd GF, Jurkovich GJ. Predictors of morbidity after traumatic pancreatic injury. *J Trauma.* 2003;55:898-905.
- Schurink GW, Bode PJ, Luijt PA, Vugt AB. The value of physical examination in the diagnosis of patients with blunt abdominal trauma: a retrospective study. *Injury.* 1997;28:261-5.
- Wong YC, Wang LJ, Lin BC, Chen CJ, Lim KE, Chen RJ. CT grading of blunt pancreatic injuries: prediction of ductal disruption and surgical correlation. *J Comput Assist Tomogr.* 1997;21:246-50.
- Fischer JH, Carpenter KD, Keefe GE. CT diagnosis of an isolated blunt pancreatic injury. *AJR Am J Roentgenol.* 1996;167:1152.
- Bradley EL, Young PR, Chang MC, Allen JE, Baker CC, Meredith W, et al. Diagnosis and initial management of blunt pancreatic trauma: guidelines from a multiinstitutional review. *Ann Surg.* 1998;227:861-9.
- Sutherland I, Ledder O, Cramer J, Nydegger A, Catto SA, Cain T, et al. Pancreatic trauma in children. *Pediatr Surg Int.* 2010;26:1201-6.
- Venkatesh SK, Wan JM. CT of blunt pancreatic trauma: a pictorial essay. *Eur J Radiol.* 2008;67:311-20.
- Chen CF, Kong MS, Lai MW, Wang CJ. Acute pancreatitis in children: 10 years experience in a medical center. *Acta Paediatr Taiwan.* 2006;47:192-6.
- Gupta A, Stuhlfaut JW, Fleming KW, Lucey BC, Soto JA. Blunt trauma of the pancreas and biliary tract: a multimodality imaging approach to diagnosis. *Radiographics.* 2004;24:1381-95.
- Linsenmaier U, Wirth S, Reiser M, Korner M. Diagnosis and classification of pancreatic and duodenal injuries in emergency radiology. *Radiographics.* 2008;28:1591-602.
- Wong YC, Wang LJ, Lin BC, Chen CJ, Lim KE, Chen RJ. CT grading of blunt pancreatic injuries: prediction of ductal disruption and surgical correlation. *J Comput Assist Tomogr.* 1997;21:246-50.
- Takishima T, Hirata M, Kataoka Y, Asari Y, Sato K, Ohwada T, et al. Pancreatographic classification of pancreatic ductal injuries caused by blunt injury to the pancreas. *J Trauma.* 2000;48:745-51.
- Moore EE, Cogbill TH, Malangoni MA, Jurkovich GJ, Champion HR, Gennarelli TA, et al. Organ injury scaling, II: Pancreas, duodenum, small bowel, colon, and rectum. *J Trauma.* 1990;30:1427-9.
- Campbell R, Kennedy T. The management of pancreatic and pancreaticoduodenal injuries. *Br J Surg.* 1980;67:845-50.
- Lopez PP, Benjamin R, Cockburn M, Amortegui JD, Schulman CI, Soffer D, et al. Recent trends in the management of combined pancreatoduodenal injuries. *Am Surg.* 2005;71:847-52.
- Lin BC, Chen RJ, Fang JF, Hsu YP, Kao YC, Kao JL. Management of blunt major pancreatic injury. *J Trauma.* 2004;56:774-8.
- Gupta V, Wig JD, Garg H. Trauma pancreaticoduodenectomy for complex pancreaticoduodenal injury. Delayed reconstruction. *JOP.* 2008;9:618-23.
- Young PR, Meredith JW, Baker CC, Thomason MH, Chang MC. Pancreatic injuries resulting from penetrating trauma: a multi-institution review. *Am Surg.* 1998;64:838-43.
- Kao LS, Bulger EM, Parks DL, Byrd GF, Jurkovich GJ. Predictors of morbidity after traumatic pancreatic injury. *J Trauma Injury Infection Critical Care.* 2003;55(5):898-905.
- Recinos G, Bose JJ, Teixeira PG, Inaba K, Demetriades D. Local complications following pancreatic trauma. *Injury.* 2009;40(5):516-20.
- Fisher M, Brasel K. Evolving management of pancreatic injury. *Curr Opin Crit Care.* 2011;17:613-7.
- Jeroukhimov I, Zoarets I, Wiser I, Shapira Z, Abramovich D, Nesterenko V, et al. Diagnostic use of endoscopic retrograde cholangiopancreatography for pancreatic duct injury in trauma patients. *Isr Med Assoc J.* 2015;17:401-4.
- Vijay A, Abdelrahman H, Menyar A, Thani H. Early laparoscopic approach to pancreatic injury following blunt abdominal trauma. *J Surg Case Rep.* 2014;12:1-3.
- Rogers SJ, Cello JP, Schecter WP. Endoscopic retrograde cholangiopancreatography in patients with pancreatic trauma. *J Trauma.* 2010;68:538-44.
- Cogbill TH, Moore EE, Morris JA. Distal pancreatectomy for trauma: a multicenter experience. *J Trauma.* 1991;31:1600-6.
- Akhrass R, Yaffe MB, Brandt CP. Pancreatic trauma: a ten-year multi-institutional experience. *Am Surg.* 1997;63:598-604.
- Vasquez JC, Coimbra R, Hoyt DB. Management of penetrating pancreatic trauma: an 11-year experience of a level-1 trauma center. *Injury.* 2001;32:753-9.
- Chinnery GE, Madiba TE. Pancreaticoduodenal injuries: re-evaluating current management approaches. *South African J Surg.* 2010;48(1):10-4.
- Menahem B, Lim C, Lahat E, Salloum C, Osseis M, Lacaze L, et al. Conservative and surgical management of pancreatic trauma in adult patients. *Hepatobiliary Surg Nutr.* 2016;5(6):470-7.
- Ragulin C, Witkowski R, Chau Z, Wemple D, Santry HP, Tseng JF, et al. National trends in pancreaticoduodenal trauma: interventions and outcomes. *HPB.* 2014;16(3):275-81.
- Wisner DH, Wold RL, Frey CF. Diagnosis and Treatment of Pancreatic Injuries: An Analysis of Management Principles. *Arch Surg.* 1990;125(9):1109-13.

33. Menahem B, Lim C, Lahat E, Salloum C, Osseis M, Lacaze L, et al. Conservative and surgical management of pancreatic trauma in adult patients. *Hepatobiliary Surg Nutr.* 2016;5(6):470-7.
34. Petrone P, Moral AS, Gonzalez Perez M, Ceballos E, Marini CP. Management of pancreatic trauma: a literature review. *Cirugia Espanola* (English Edition). 2017;95(3):123-30.
35. Jurcovich GJ, Bugler E, Moore EE, Feliciano DY, Mattox K. Doudenum and pancreas. *Trauma.* 2004;5:14.
36. Boffard KDB. Manual of definitive surgical trauma care. London: Hodder Arnold; 2003.
37. Madiba TE, Mokoena TR. Favourable prognosis after surgical drainage of gunshot, stab or blunt trauma of the pancreas. *Br J Surg.* 1995;82:1236-9.
38. Degiannis E, Levy RD, Velmahos GC, Potokar T, Florizoone MG, Saadia R. Gunshot injuries of the head of the pancreas: conservative approach. *World J Surg.* 1996;20:68-71.
39. Bassi CD, Butturini G, Fingerhut A, Yeo C, Izbicki J. Postoperative pancreatic fistula: an international study group (ISGPF) definition. *Surg.* 2005;138:8-13.
40. Young PR, Meredith JW, Baker CC, Thomason MH, Chang MC. Pancreatic injuries resulting from penetrating trauma: a multi-institution review. *Am Surg.* 1998;64:838-43.

Cite this article as: Ahmad S, Singh V, Pandey VK, Kumar S, Alam T, Pratap P. Step up approach for the management of late presentation of pancreatic trauma patients. *Int Surg J* 2020;7:1065-70.