

Original Research Article

The role of diagnostic laparoscopy in abdominal masses

Hisham I. El Zanati*, Waleed A. Aboelwafaa, Yasser M. Hamza

Department of Surgery, Faculty of Medicine, Alexandria University, Egypt

Received: 25 December 2019

Revised: 08 February 2020

Accepted: 27 February 2020

*Correspondence:

Dr. Hisham I. El Zanati,

E-mail: hishamzanati@yahoo.com

Copyright: © the author(s), publisher and licensee Medip Academy. This is an open-access article distributed under the terms of the Creative Commons Attribution Non-Commercial License, which permits unrestricted non-commercial use, distribution, and reproduction in any medium, provided the original work is properly cited.

ABSTRACT

Background: Diagnostic laparoscopy is an added tool that has become widely available for the assessment of abdominal masses in addition to conventional imaging. It is the best real time imaging technique due to the magnification and intense illumination provided. The aim of this work is the assessment of the impact of performing diagnostic laparoscopy at the start of operations intended for resection of an abdominal mass.

Methods: This prospective study included 40 patients admitted for surgical resection of an abdominal mass. All Patients were subjected to thorough conventional investigations followed by diagnostic laparoscopy performed prior to the start of the definitive operation. We assessed the extra time needed, complications encountered, effect on decision making and the overall benefit of laparoscopy in this context.

Results: Overall 21 patients (52.5%) did benefit from diagnostic laparoscopy somehow between upgrading the staging, affecting the laparotomy incision site and confirming feasibility of laparoscopic resection. Of the patients who proceeded to a laparotomy (n=30), diagnostic laparoscopy missed local invasion in 7 patients, which precluded the resection of the tumor in 5 of them. Only 1 complication related to diagnostic laparoscopy was encountered in the form of a port-site hematoma (2.5%).

Conclusions: While diagnostic laparoscopy doesn't carry significant added morbidity, it might save the patient an unnecessary laparotomy by altering the preoperative staging and improving the accuracy of anatomical and pathological diagnoses. Laparoscopy has its limitations mainly in the assessment of the retroperitoneal space as well as direct tumor invasion to adjacent organs and vessels.

Keywords: Diagnostic laparoscopy, Abdominal mass, Resectability

INTRODUCTION

When all current staging modalities are utilized, their accuracy in predicting resectability of abdominal tumors is reported to be about 80%, meaning that one in five patients brought to the operating room with the intent of a curative resection might end up having unresectable disease.^{1,2}

Diagnostic laparoscopy (DL) has several advantages compared to other diagnostic modalities. It is the best real time imaging technique due to the magnification and

intense illumination provided. This is reflected in its efficacy in visualization of the abdominal and pelvic cavities, in detection of small amounts of ascitic fluid and small peritoneal deposits which could be missed by the other imaging studies. It can also detect lymphadenopathy and small liver metastasis in addition to aiding in the assessment of local invasion of surrounding structures of a given lesion and deciding on its resectability.^{3,4} Laparoscopic staging of intra-abdominal malignancies should however be viewed as complementary rather than a replacement to other noninvasive diagnostic modalities such as contrast-

enhanced, multidetector computerized tomography, magnetic resonance imaging, positron emission tomography or endoscopic ultrasonography.⁵⁻⁸

An important goal of the technique is to decrease the number of negative laparotomies in patients who appear to have resectable abdominal masses and to decrease the burden of surgery.⁹ This can lead to decreased perioperative morbidity and mortality, shorter hospital stay, faster referral to chemoradiotherapy, improved quality of life, and reduced hospital costs.¹⁰

The aim of this work is the assessment of the impact of performing diagnostic laparoscopy at the start of operations intended for resection of an abdominal mass and the effect this will have on the surgical procedure.

METHODS

This was a prospective interventional study including Forty patients admitted to the department of general surgery at the alexandria main university hospital, Egypt for surgical resection of an abdominal mass over a 1 year period from February 2014 to February 2015. All patients admitted to the department within that year for an elective resection of an abdominal mass were included. Patients requiring an emergency resection and those with 2 or more previous abdominal operations were excluded as laparoscopy was expected to be difficult and carrying an increased risk of bowel injury and therefore not performed. All patients had the usual preoperative diagnostic workup including routine bloods, endoscopic assessment when indicated, ultrasound scans, CT scans and/or MRI scans as required. DL was done after induction of anesthesia just before the planned laparotomy. The outcomes studied included the effect of laparoscopy on the decision to operate through altering the preoperative radiological staging as well as clarifying the diagnosis in patients with equivocal radiological investigations and assessing feasibility of laparoscopic resection. Subsequently the total number and percentage of the patients that benefited from diagnostic laparoscopy was calculated. The extra time added to the procedure through implementing diagnostic laparoscopy was recorded as well as any direct complications of the DL and its limitations highlighted.

The peritoneal cavity was accessed using the open technique. Laparoscopic examination was performed in a systematic fashion. The abdominal contents were explored in two circular paths around the abdomen, one focusing on the anterior abdominal wall and the other on visceral surfaces. The inferior surface of the liver was examined by lifting the organ with a blunt instrument. Exposure was facilitated by repositioning the patient as required.

The further steps to follow including the site and number of other ports were decided according to the initial findings. We specifically looked for hepatic small

surface nodules, minimal ascites, omental or peritoneal deposits (including anterior abdominal wall and small bowel) and relations and attachments of the tumor. Peritoneal and liver deposits were biopsied. Ascitic fluid was sampled for cytological examination.

If laparoscopic intervention was found to be feasible, the operation continued laparoscopically. If not, the site and size of the laparotomy incision is determined. The abdomen is opened under laparoscopic direct visual control.

Ethical approval was obtained from our local ethics committee prior to commencement of the study and informed written consent obtained from all the patients included.

RESULTS

The study included 40 patients: 23 females (57.5%) and 17 males (42.5%). The age ranged from 31 years to 70 years with a mean of 53 years. The diagnoses of the patients included in the study (n=40) is shown in (Table 1). 37 of these were malignant. The setup time for the laparoscope ranged from 10 min 11 s to 14 min 34 s, with a mean time of 12 min 15 s, while the actual diagnostic laparoscopy time ranged from 7 min 45 s to 19 min 37 s with a mean time of 10 min 55 s.

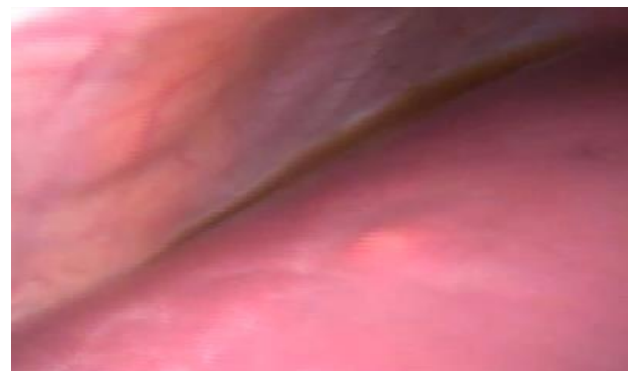

Figure 1: Minute liver deposit not detected by CT.



Figure 2: Peritoneal deposits not detected by CT.

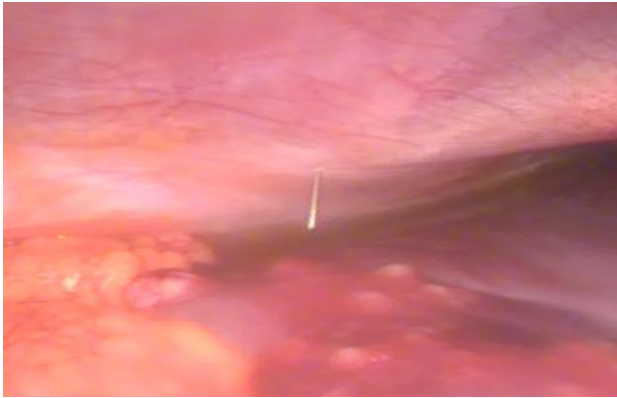


Figure 3: Aspiration of malignant ascites.

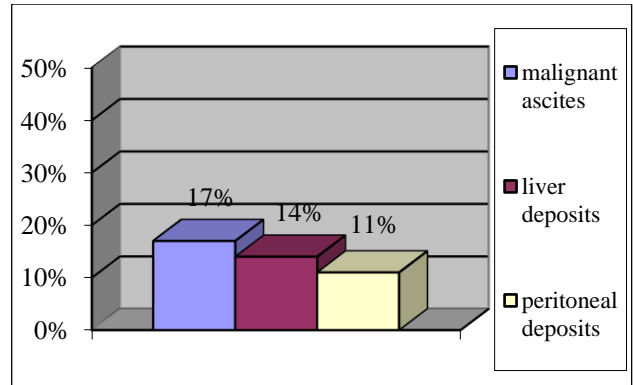


Figure 4: Incidence of the different inoperability criteria in the malignant cases as detected by laparoscopy.

Table 1: Distribution of the study cases according to their diagnosis.

Diagnosis	Number	Percentage N (%)	Comments
Colorectal cancers	16	40	9 rectosigmoid, 6 right colon, 1 descending colon
Gastric masses	6	15	3 GIST, 3 adenocarcinoma
Pancreatic head tumors	5	12.5	4 head proper, 1 peri-ampullary tumor
Suprarenal tumour	3	7.5	1 GIST, 1 solitary metastasis from breast cancer, 1 pheocromocytoma
Liver tumours	2	5	Hepatocellular carcinoma
Ovarian cysts	2	5	Simple cysts
Small intestinal mass	1	2.5	GIST (gastrointestinal stromal tumor)
Mesenteric cyst	1	2.5	-
Splenic mass	1	2.5	Non-Hodgkin's lymphoma
Appendicular cyst	1	2.5	Carcinoid of appendix
Undescended testicular mass	1	2.5	Seminoma on top of undescended testis
Gall bladder mass	1	2.5	Gall bladder carcinoma

Table 2: Cases in which DL changed the staging of the disease.

Diagnosis	Preoperative CT staging	DL findings	Post DL staging
Stomach GIST	III	Peritoneal and omental deposits	IV
Hepatocellular carcinoma	III	Peritoneal deposits and minimal ascites	IV
Small intestinal GIST	Not diagnosed preoperatively	Liver metastasis and minimal ascites	IV
Gall bladder carcinoma	Not diagnosed preoperatively	Liver metastasis and minimal ascites	IV
Stomach GIST	II	Peritoneal deposits	IV
Sigmoid cancer	II	Peritoneal deposits	IV
Pancreatic head cancer	II	Liver metastasis and minimal ascites	IV
Stomach cancer	II	Liver metastasis and minimal ascites	IV
Stomach cancer	III	Liver metastasis and minimal ascites	IV

One complication related to the diagnostic laparoscopy, a port site hematoma, was encountered (2.5% complication rate). Laparoscopy changed the preoperative staging in 9 patients (24.3%) as shown in (Table 2).

Different findings demonstrated by DL indicating inoperability included malignant ascites, liver and peritoneal deposits as shown in Figures 1-4. Laparoscopy was used for definitive treatment in 10 patients after being deemed feasible by DL (25%) as shown (Table 3).

In 8 patients (20%) DL clarified an equivocal preoperative radiological diagnosis. Overall, 21/40 of the study patients (52.5%) benefited from diagnostic laparoscopy one way or the other.

Table 3: Cases that were managed laparoscopically.

Procedure	Number
Gall bladder cancer, laparoscopic cholecystectomy	1
Solitary adrenal metastasis from breast cancer, laparoscopic adrenalectomy	1
Carcinoid of appendix, laparoscopic appendectomy	1
Testicular cancer in an undescended testis, laparoscopic orchidectomy	1
Sigmoid colonic cancer, laparoscopic sigmoid colectomy	4
Mesenteric cyst excision	1
Ovarian cyst excision	1
Total	10

Table 4: Pitfalls of DL.

Diagnosis	DL findings	Laparotomy findings
Adrenal GIST	Huge suprarenal mass seen	IVC infiltrated
Pancreatic head cancer	Mass not seen	Portal vein confluence infiltrated
Pancreatic head cancer	Mass not seen	Portal vein confluence infiltrated
Small intestinal GIST	Intestinal mass+ liver deposit	Sigmoid and urinary bladder infiltrated
Rectosigmoid cancer	Rectosigmoid mass seen	Small intestine infiltrated
Stomach cancer	Gastric mass arising from lesser curve extending posteriorly	Pancreas infiltrated
Pancreatic head cancer	Mass not seen	Portal vein infiltrated

In the patients that underwent laparotomy after laparoscopy with the intent of resection of the mass, missed local invasion was found in 7 cases and in 5 of these cases this precluded the resection of the tumor as shown in (Table 4).

DISCUSSION

Overall 21 (52.5%) of the studied patients did benefit from DL somehow. In ten patients (i.e., 25%) DL led to definitive treatment through laparoscopy and they were saved a laparotomy.

Diagnostic laparoscopy also altered the staging of 9 of the cancer patients (24.3%) by detecting peritoneal deposits, liver deposits or minimal malignant ascites not identified by radiological investigations. Researchers at memorial sloan kettering cancer center and MD anderson cancer center have evaluated the feasibility, yield, and clinical benefit of laparoscopic staging after high-quality abdominal CT staging and found that laparoscopy identified CT-occult metastatic disease in 23% to 37% of patients. Moreover, less than 2% of the patients in whom CT-occult metastases were identified by laparoscopy required subsequent laparotomy for palliation. On the basis of the available data, the National Comprehensive Cancer Network has integrated laparoscopy into the recommended routine staging algorithm for patients with locoregional gastric cancers and selected patients with advanced gastric cancer.³

When laparotomy is pursued after DL, it will be limited to execute the action already decided upon by laparoscopy. This will limit the time, the incision and the magnitude of surgery.

Although aspiration of ascitic fluid for cytology was performed when detected, routine peritoneal lavage and cytology was not performed in this study. Literature review shows controversies regarding the consistency and reliability of the technique.¹¹ Nieveen et al reported that it provides benefit in only 1.3% of patients and has limited prognostic value for survival in this group of patients.¹²

On the other hand, when unexplained ascites was found from the start of the procedure, we considered it as a poor prognostic sign and the disease likely stage IV even before cytological analysis. This was also suggested by Emmanuel et al who stated that cytology does not appear to be important-the mere presence of ascites is what really matters. Large tumors shed tumor cells, but smaller tumors secrete vasoactive peptides that change osmotic gradients and cause ascites; he therefore regards the presence of unexplained intraperitoneal fluid as an absolute contraindication to resection.¹³

In this study DL also demonstrated a benefit over radiological investigations in clarifying the anatomy or undiagnosed pathology in 20% of our patients. The importance of laparoscopy in the diagnosis of the anatomic site of a tumor was also proven by Kriplani et al and Bahinue et al.^{14,15}

Jarnagin et al and Lai et al reported the most common reasons that DL missed irresectable disease were vascular invasion, lymph node metastases, and adjacent organ invasion.^{16,17} In our study laparoscopy was defective in these points as well (Table 4).

Laparoscopic staging of intra-abdominal malignancies should therefore be viewed as complementary rather than a replacement to other noninvasive diagnostic modalities.⁸ This was confirmed by Nicolas et al that

stated that using laparoscopy alone it is impossible to properly analyze the retroperitoneum and its vessels.¹⁸ Accordingly in the pancreatic head cancers in our study we chose not to enter the lesser sac to visualize the tumor as the mere visualization of the tumor would not add any data to our staging, only prolonging the procedure, while trying to assess its resectability, in the absence of laparoscopic ultrasound, by assessing its relationship to the mesenteric and portal vessels would be extremely hazardous.

Another drawback of laparoscopy is the loss of tactile sensation that had long been part of operating surgeon's craft. This is responsible for the decreased ability of DL to assess local invasion and fixation to surrounding structures.

CONCLUSION

While diagnostic laparoscopy doesn't carry significant morbidity, it might save the patient an unnecessary exploratory laparotomy. Laparoscopy can help in making an accurate anatomical and pathological diagnosis in abdominal malignancies. It can also alter the preoperative radiological staging and hence the management plan. Laparoscopy has significant limitations in the assessment of the retroperitoneal space as well as the assessment of direct tumor invasion to adjacent organs. It is also not reliable in detecting vascular and intraluminal spread. Overall, we do recommend the increased use of diagnostic laparoscopy as an adjunct to other diagnostic modalities where feasible prior to laparotomies for resecting abdominal masses.

Funding: No funding sources

Conflict of interest: None declared

Ethical approval: The study was approved by the local Ethics Committee

REFERENCES

- Desmond HB, Nathaniel JS, Lee LS, Eubanks WS. Videoendoscopy and general surgery, A brief History. Mastery of Endoscopic and Laparoscopic Surgery. 2nd edition, Lippincott Williams and Wilkins; 2005: 1-3.
- Blair AJ, John GH, Charles BF. Minimally invasive surgery. Schwartz's Principles of Surgery 8th ed. New York: McGraw-Hill Medical Publishing Division; 2005;13:29.
- Brady PO, Peebles M, Goldschmid SA. Role of Laparoscopy in the evaluation of patients with Suspected hepatic or peritoneal malignancy. Gastrointest Endosc. 1991;37:27-30.
- Els JM, Nieveen VD, Laurens TH, Otto MV. The efficiency of laparoscopic staging in patients with upper gastrointestinal tumors. Cancer. 1997;79:1315-7.
- Kim HJ, Conlon KC, Evans DB, Pisters PWT. Laparoscopic staging, in Abbruzzese JL (eds). MD Anderson Solid Tumor Oncology Series-Pancreatic Cancer. New York. Springer-Verlag; 2002: 115.
- Kevin CC, Desmond T. Diagnostic Laparoscopy. Fischer, Josef E. Mastery of Surgery, 5th Edition Lippincott Williams and Wilkins; 2007;19:252.
- Fernandez CC, Warshaw AL, Levine BA, Copeland EM, Howard RJ, Sugarman HJ et al. Nonendocrine neoplasms of the pancreas. Current practice of surgery, New York: Churchill Livingstone; 1993;16:117.
- Awad SS, Colletti L, Mulholland MW, Knol J, Rothman ED, Scheiman J et al. Multimodality staging optimizes resectability in patients with pancreatic and ampullary cancer. Am Surg. 1997;63:48.
- Charles MV, Jeffrey AD, William DM, Sharlene AT, David CL, Nathaniel JS et al. Utility of Staging Laparoscopy in subsets of peripancreatic and biliary malignancies. Annals Surg. 2002;23:1-7.
- Kevin CC, Desmond T, Fischer, Josef E. Diagnostic Laparoscopy, Mastery of Surgery, 5th Edition. Lippincott Williams and Wilkins; 2007;19:252.
- Waddah BR, Eddie KA, Syed AA, Paul FM, Barry WF, David HB et al. Gastric cancer. MD Anderson Surgical Oncology Handbook 4th ed. Lippincott Williams and Wilkins; 2006;9:212-3.
- Dijkum NEJ, Sturm PD, Wit LT, Offerhaus J, Obertop H, Gouma DJ. Cytology of peritoneal lavage performed during staging laparoscopy for gastrointestinal malignancies. Ann Surg. 1998;228:728-33.
- Emmanuel EZ, Dana O, Brian AB, Steven BG, Alexander SR. Prognostic significance of new onset ascites in patients with pancreatic cancer. World J Surg oncol. 2006;4:16.
- Kriplani AK, Kapur BM. Laparoscopy for preoperative staging and assessment of gastric carcinoma. Gastrointest Endosc. 1991;37:441-3.
- Bahinue TJ, Lewis D, Jenkins RL. Role of staging laparoscopy in treatment of hepatic malignancy. Am J Surg. 1994;167:151-5.
- Lo CM, Lai EC, Liu CL, Fan ST, Wong J. Laparoscopy and laparoscopic ultrasonography avoid exploratory laparotomy in patients with hepatocellular carcinoma. Ann Surg. 1998;227:527-32.
- Jarnagin WR, Bodniewicz J, Dougherty E, Conlon K, Blumgart LH, Fong Y. A prospective analysis of staging laparoscopy in patients with primary and secondary hepatobiliary malignancies. J Gastroint Surg. 2000;4:34-43.
- Nicolas CB, Michael C, Pierre AP, Leo HB, Philippe M. Vascular invasion in pancreatic cancer: Imaging modalities, preoperative diagnosis and surgical management. World J Gastroenterol. 2010;16(7):818-31.

Cite this article as: El Zanati HI, Aboelwafaa WA, Hamza YM. The role of diagnostic laparoscopy in abdominal masses. Int Surg J 2020;7:945-9.