

Original Research Article

Evaluation of adult cases presenting with bleeding per rectum

Arun R.*, Dilip B. Choksi, Milind Patil, Pooja Shah, Sahdevsinh Chauhan

Department of General Surgery, Government Medical College, Baroda, Gujarat, India

Received: 16 September 2020

Revised: 16 September 2020

Accepted: 17 September 2020

*Correspondence:

Dr. Arun R.,

E-mail: dr.r.arunmbbs@gmail.com

Copyright: © the author(s), publisher and licensee Medip Academy. This is an open-access article distributed under the terms of the Creative Commons Attribution Non-Commercial License, which permits unrestricted non-commercial use, distribution, and reproduction in any medium, provided the original work is properly cited.

ABSTRACT

Background: Aim of the study was to find out various proportion of diseases responsible for bleeding per rectum in adults and to find out diagnostic utility of anoproctoscopy, rigid sigmoidoscopy and colonoscopy for patients with bleeding per rectum. It also aims to find out the usefulness of other investigations like upper GI scopy, computed tomography etc., in undiagnosed cases.

Methods: A total no of 129 patients with complaint of bleeding per rectum were included in the study. All cases were subjected to anoproctoscopy and rigid sigmoidoscopy. Colonoscopy was done in cases with severe or recurrent bleeding which were undiagnosed by sigmoidoscopy. If colonoscopy does not reveal the diagnosis upper GI scopy or computerized tomography (CT) angiography was done.

Results: At the end of evaluation of 129 cases with bleeding per rectum, the cause for bleeding identified in 101 cases (78.3%). 28 cases (21.7%) remain undiagnosed.

Conclusions: Large bowel endoscopy increases the diagnostic yield in patients with bleeding per rectum. Rigid sigmoidoscopy is a safe OPD based procedure, recommended in all patients presenting with bleeding per rectum and if the cause for bleeding per rectum cannot be diagnosed by rigid sigmoidoscopy, then colonoscopy is indicated. Even colonoscopy is not diagnostic, then the other investigations like upper GI scopy and CT angiography can be done to identify the source of bleeding.

Keywords: Bleeding per rectum, Rigid sigmoidoscopy, Colonoscopy

INTRODUCTION

The term bleeding per rectum refers to the passage of fresh bright red bleed through the anus with or without stool. Bleeding per rectum is a common clinical problem with a prevalence of 14 to 19% in adults.¹⁻⁴ Lower gastrointestinal disorders are responsible for majority of bleeding per rectum but 10 to 15% bleeding PR is associated with upper gastro intestinal disorders. Most patients bleed from benign sources such as haemorrhoids and diverticula but others have serious colorectal disease including colon cancer.

Lower gastrointestinal endoscopy (Proctoscopy, sigmoidoscopy, colonoscopy) plays an important role in identifying the cause of bleeding per rectum. These procedures offer direct visualization of the mucosa of large intestine.

The present study is an attempt to find out various proportion of diseases responsible for bleeding per rectum in adults and to find out diagnostic utility of anoproctoscopy, rigid sigmoidoscopy and colonoscopy for patients with bleeding per rectum. It also aims to find out the usefulness of other investigations like upper GI scopy, computed tomography etc., in undiagnosed cases.

The aim and objectives of the study were to find out various proportion of diseases responsible for bleeding per rectum in adults, find out diagnostic utility of anoproctoscopy, rigid sigmoidoscopy and colonoscopy for patients with bleeding per rectum and to find out impending percentage of cases of bleeding per rectum remains undiagnosed after anoproctoscopy, rigid sigmoidoscopy, colonoscopy and came out with other useful investigations like upper GI scopy, computed tomography, RBC scintigraphy scan etc.

METHODS

This study was done on patients presenting at department of general surgery at SSG hospital with complaint of bleeding per rectum during the period of June 2017 to December 2018.

This study was cross sectional study. Inclusion criteria included all the patients above 18 years who attended the surgical OPD with complaint of passage of blood per rectum. Exclusion criteria excluded patients not giving informed consent. Patients less than 18 years of age and patients with bleeding per rectum which is associated with acute painful conditions like acute fissure and thrombosed haemorrhoid.

A total no of 129 patients with complaint of bleeding per rectum were included in the study after considering inclusion and exclusion criteria.

In all the cases detailed history was taken and patients were subjected to complete clinical examination including per rectal examination. Depending upon the severity, patients with bleeding per rectum were classified into 3 categories- mild, moderate and severe/profuse. For all the cases ano-proctoscopy was done in left lateral position. Rigid sigmoidoscopy was carried out in left lateral (Sim's) position for all the cases. Rigid sigmoidoscope having diameter of 1.5 cm and length of 25 cm was used. If the source of bleeding was not able to identify even after clinical examination and proctoscopy sigmoidoscopic examination then colonoscopy was planned depending upon the patient's severity of bleeding. In undiagnosed cases, if the patient had severe bleeding per rectum or recurrent episodes of bleeding per rectum then colonoscopy is advised and the patients were sent to outside hospital for colonoscopy. After colonoscopy the patients were followed up and colonoscopy report were noted. If the source of bleeding was not been able to identified even after colonoscopy, then patients were advised for other investigations like computerised tomography, upper GI scopy, etc. depending upon the severity of bleeding and other associated clinical features.

The study was approved by the institutional research and ethical committee.

Statistical test used in this study includes descriptive statistics. Results were expressed in mean and standard deviation.

RESULTS

This study was conducted during the period of June 2017 to December 2018 in Baroda medical college and SSG hospital. 129 patients with complaint of bleeding per rectum were included in the study. Out Of 129 cases 80 cases were male (63%) and 49 were female (37%) (Table 1). Out of 129 cases 111 cases had mild bleeding, 15 cases had moderate bleeding, and 3 cases had severe bleeding.

Table 1: Age and sex distribution of patients with bleeding per rectum.

Age (years)	Total no. of cases	No. of male cases	No. of female cases	Percentage (%)
12-20	3	1	2	2.3
21-30	35	21	14	27.2
31-40	30	17	13	23.3
41-50	32	20	12	24.8
51-60	17	12	5	13.1
61-70	11	9	2	8.5
71-80	1	1	-	0.8
Total	129	81	48	100

Out of 129 cases with bleeding per rectum, the source of bleeding was able to make out in 81 cases (i.e. 63% of cases) after clinical examination, proctoscopy and rigid sigmoidoscopy. Out of 49 patients with haemorrhoidal disease 2 patients had proctitis, 1 patient had sigmoid colon polyp and 2 patients had sigmoid colitis (Table 2).

Table 2: Diagnosis made by rigid sigmoidoscopy in this study.

Diagnosis	No. of cases
Haemorrhoid	51 (2 cases with proctitis, 1 case with sigmoid colon polyp and 2 cases with sigmoid colitis)
Fistula in ano	8
Anal fissure	7
Rectal prolapse	3
Proctitis	2
Colorectal carcinoma	5
Sigmoid colon polyp	1
Colitis	1
Rectal varices	2
Solitary rectal ulcer	1
Total	81

Out of 48 cases in which the diagnosis was not able to made after rigid sigmoidoscopy, 27 cases either had moderate to severe bleeding or recurrent bleeding or had high risk factors of colorectal carcinoma like advance age >50 years, positive family history etc., and these 27 cases were advised and subjected to colonoscopy. Out of 27 cases which were subjected to colonoscopy, diagnosis was able to make out in 11 cases. After employing colonoscopy to the needed cases, the source of bleeding was able to make out in 92 cases (71%) out of 129 cases (Table 3).

Table 3: Diagnosis made by colonoscopy in this study.

Colonoscopy diagnosis	No of cases
Colorectal carcinoma	2
Colitis	2
Crohn's disease	2
Ulcerative colitis	2
Diverticulosis of colon	2
Multiple colonic polyposis	1

Out of 27 cases with either moderate to severe bleeding or recurrent bleeding, colonoscopy not able to find out the source of bleeding in 16 cases. Out of these 16 cases, 8 cases had either complaint of hematemesis or history of liver disease and these 7 cases were advised and subjected to upper GI scopy-6 cases had oesophageal varices and 1 case had gastro intestinal stromal tumour of stomach. 9 cases were advised for CT angiography. Out

of these 9 cases, 1 patient diagnosed with splenic artery pseudo aneurysm and another 1 patient diagnosed with gastro-duodenal artery pseudo aneurysm.

Out of 129 cases with bleeding per rectum, all 129 cases were subjected to clinical examination including per rectal examination, proctoscopy and rigid sigmoidoscopy. 27 cases were subjected to colonoscopy. 7 cases were subjected to upper GI scopy and 3 patients were subjected to CT. After all the above evaluation, diagnosis was made in 101 cases (78.3%) and 28 cases (21.7%) remains undiagnosed (Figure 1).

Various causes for bleeding per rectum identified in this study includes hemorrhoid in 46 cases (37.2%), hemorrhoid with sigmoid colon polyp in 1 case (0.8%), hemorrhoid with proctitis in 2 cases (1.5%), hemorrhoid with sigmoid colitis in 2 cases (1.5%), anal fissure in 7 cases (5.5%), fistula in ano in 8 cases (6.2%), rectal prolapse in 3 cases (2.4%), proctitis in 2 cases (1.5%), solitary rectal ulcer in 2 cases(1.5%), rectal varices in 1 case (0.8%), sigmoid colon polyp in 1 case (0.8%), multiple colonic polyposis in 1 case (0.8%), colon carcinoma in 7 cases (5.5%), colonic diverticulosis in 2 cases (1.5%), Crohn's disease in 2 case(1.5%), ulcerative colitis in 2 cases (1.5%), gastro duodenal artery pseudo aneurysm in 1 case (0.8%), splenic artery pseudo aneurysm in 1 case (0.8%), oesophageal varices in 6 cases (4.6%) and GIST of stomach in 1 case (0.8%) (Table 4 and Figure 2).

Table 4: Various causes of bleeding per rectum at the end of evaluation.

Diagnosis	No. of male cases	No. of female cases	Total no. of cases	Percentage (%)
Haemorrhoid	30	16	46	37.2
Haemorrhoid with proctitis	2	-	2	1.5
Haemorrhoid with sigmoid colon polyp	1	-	1	0.8
Haemorrhoid with sigmoid colitis	1	1	2	
Anal fissure	2	5	7	5.5
Fistula in ano	4	4	8	6.2
Rectal prolapse	2	1	3	2.4
Proctitis	1	1	2	1.5
Solitary rectal ulcer	1	1	2	1.5
Rectal varices	1	-	1	0.8
Colitis	2	1	3	2.4
Sigmoid colon polyp	1	-	1	0.8
Multiple colonic polyposis	-	1	1	0.8
Colorectal carcinoma	5	2	7	5.4
Diverticulosis of colon	2	-	2	1.5
Crohn's disease	1	1	2	1.5
Ulcerative colitis	2	-	2	1.5
Gastro duodenal artery pseudo aneurysm	1	-	1	0.8
Splenic artery pseudo aneurysm	1	-	1	0.8
Esophagealvarices	6	-	6	4.6
Gist of stomach	1	-	1	0.8
Undiagnosed cases	13	15	28	21.7
Total	81	48	129	100.0

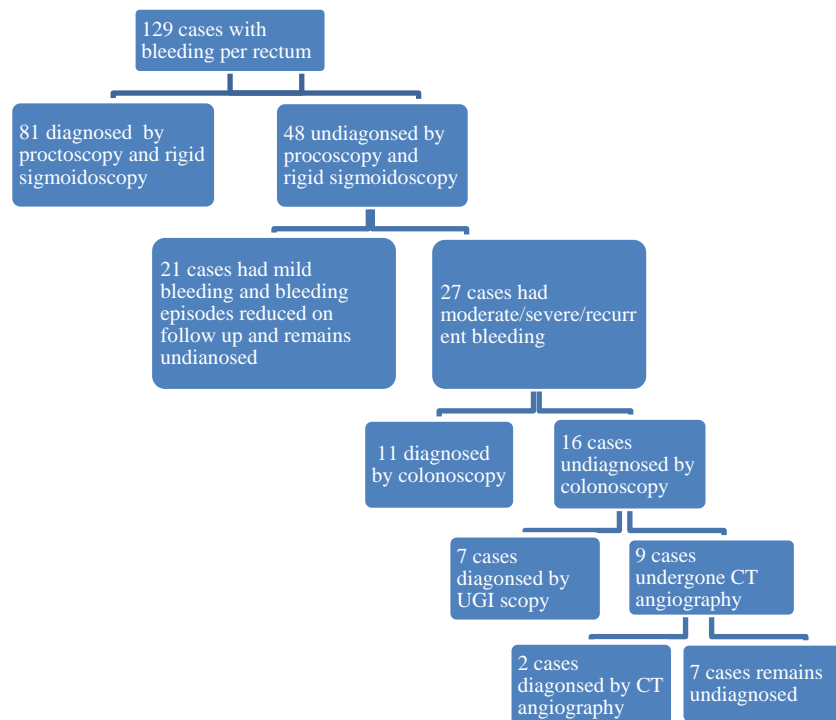


Figure 1: Scheme of diagnostic evaluation done in this study.

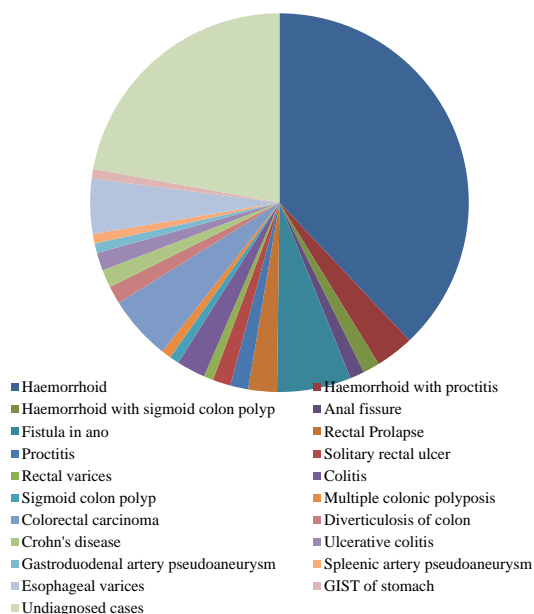


Figure 2: Proportion of various causes of bleeding per rectum in this study.

DISCUSSION

Benign ano rectal pathologies are responsible for majority of bleeding per rectum. But if there was no obvious anal cause found, then there are no clear guidelines how to evaluate the patient further to arrive at the diagnosis. This study evaluated the patients with bleeding per rectum and employed various diagnostic

tests like sigmoidoscopy, colonoscopy, upper GI scopy, CT angiography to find out the various causes responsible for bleeding per rectum.

In 1998, study by Talley et al stated that the prevalence of rectal bleeding was significantly higher in younger individuals (20-40 years of age).² In this study also, the bleeding per rectum was found to be more common in young adults. Out of 129 cases evaluated, 68 (52.7%) cases were of age between 18-40 years of age and 61 (47.3%) cases were of age above 40 years.

In the study by Dehn et al anal diseases like haemorrhoid and fissure were responsible for bleeding in 81% of cases.⁵ In this study, benign anal disorders including haemorrhoid, anal fissure, fistula in ano were responsible for bleeding in 66 cases out of 101 cases in which the source of bleeding identified (65.3%).

Study by Cheung et al, clearly showed the coexistence of benign anal lesions like haemorrhoid with colorectal cancer and other dangerous colorectal disorders and also concluded that the patients with frank rectal bleeding should be screened for the presence of left colon cancer irrespective of the existence of haemorrhoids and also suggested sigmoidoscopy as convenient tool for the screening.⁶ Study by Srinivas et al clearly demonstrated the high diagnostic yield of rigid sigmoidoscopy and also recommended rigid sigmoidoscopy in the workup of patients presenting with bleeding per rectum.⁷ So, in this study all 129 cases with bleeding per rectum were also subjected to rigid sigmoidoscopy and when rigid sigmoidoscopic examination was included in the evaluation of cases, the diagnostic yield in this study was

increased from 54% to 63% which clearly showed the usefulness of rigid sigmoidoscopy as diagnostic tool.

Though colonoscopy is a very useful diagnostic tool in patients with bleeding per rectum, the affordability for the colonoscopy and the availability of resources is very minimal especially in developing countries. Also many studies like Study by Nikpour et al suggested the sufficiency of sigmoidoscopy over colonoscopy in ruling out dangerous lesions leading to bleeding per rectum in low to average risk individuals.⁸ Hence, in this study, among the undiagnosed bleeding per rectum cases, colonoscopy was done only in patients with other high risk factors like moderate/severe/recurrent bleeding, advanced age, positive family history. After employing colonoscopy, the diagnostic yield increases from 63% to 71%.

In a clinical series by Jensen et al 11% of patients initially suspected of having lower gastrointestinal bleeding actually had an upper gastrointestinal source and it recommended upper GI scopy in suspected cases.⁹ In this study, 7 cases had either complaint of hematemesis or history of liver disease and these 7 cases were advised and subjected to upper GI scopy. Upper GI scopy detected lesions in all these 7 cases-esophageal varices in 6 cases and GIST in 1 case. In this study 7 cases (5.4%) with bleeding per rectum is associated with upper GI bleeding.

Study by Ettorre et al demonstrated the usefulness of CT angiography in diagnosing the patient with obscure GI bleeding.¹⁰ In this study, 9 patients with moderate to severe or recurrent episodes of bleeding PR remain undiagnosed even after colonoscopy and upper GI scopy and these 9 cases were subjected to CT Angiography and diagnosis made in 2 cases-1 with gastro duodenal artery pseudoaneurysm and other with splenic artery pseudoaneurysm.

In this study, colorectal carcinoma diagnosed in 7 cases and the incidence of colorectal carcinoma in this study was 5.4%. out of 7 cases 5 cases were diagnosed with clinical examination and rigid sigmoidoscopy and 2 cases were diagnosed with colonoscopy. In the study by Dakubo et al sigmoidoscopy (both rigid and flexible) diagnosed 95.3% of the tumours and colonoscopy diagnosed remaining 4.7% of tumours.¹¹ In this study only rigid sigmoidoscopy was used which detected 71.4% of malignant tumours and Colonoscopy detected the remaining 28.6% of malignant tumours.

Left sided colorectal carcinoma especially carcinoma of recto sigmoid junction and rectal carcinoma were more common than right sided colorectal carcinoma and majority of left sided tumours can be easily diagnosed by rigid sigmoidoscopy. In this study also 6 patients had left sided colorectal tumour and out of these 6 cases 5 cases were diagnosed by rigid sigmoidoscopy. Hence, when resources for colonoscopy were limited rigid

sigmoidoscopy can effectively be used for screening the low to average risk patients with bleeding per rectum.

CONCLUSION

Large bowel endoscopy increases the diagnostic yield in patients with bleeding per rectum. Rigid sigmoidoscopy is a safe OPD based procedure which can detect many lesions in sigmoid colon and ano rectal regions including majority of colorectal carcinoma. So, rigid sigmoidoscopy is recommended in all patients presenting with bleeding per rectum and it can also act as an effective screening tool in the prevention of colorectal carcinoma. If the cause for bleeding per rectum cannot be diagnosed by rigid sigmoidoscopy, then colonoscopy is recommended to identify the source of bleeding. If the cause for bleeding per rectum cannot be diagnosed even by colonoscopy, then the other useful investigations like upper GI scopy and CT Angiography can be done to identify the source of bleeding.

Funding: No funding sources

Conflict of interest: None declared

Ethical approval: The study was approved by the Institutional Ethics Committee

REFERENCES

1. Nelson RL, Abcarian H, Davis FG, Persky V. Prevalence of benign anorectal disease in a randomly selected population. *Dis Colon Rectum.* 1995;38:341-4.
2. Talley NJ, Jones M. Self-reported rectal bleeding in a United States community: prevalence, risk factors, and health care seeking. *Am J Gastroenterol.* 1998;93:2179-83.
3. Crosland A, Jones R. Rectal bleeding: prevalence and consultation behaviour. *Bri Med J.* 1995;311:486-8.
4. Johnson DA, Gurney MS, Volpe RJ, Jones DM, Van Ness MM, Chobanian SJ et al. A prospective study of the prevalence of colonic neoplasms in asymptomatic patients with an age-related risk. *Am J Gastroenterol.* 1990;85(8):969-74.
5. Dehn T, McGinn FP. Causes of ano-rectal bleeding. *Postgraduate Med J.* 1982; 58:92-3.
6. PS Cheung, SK Wong, J Boey, CK Lai. Frank rectal bleeding: a prospective study of causes in patients over the age of 40. *Postgraduate Med J.* 1988;64:364-8.
7. Banothu Srinivas, B. Shailendra. The diagnostic efficiency of sigmoidoscopy in patients with bleeding per rectum. *IAIM.* 2016;3(6):164-9.
8. Nikpour S, Ali Asgari A. Colonoscopic evaluation of minimal rectal bleeding in average-risk patients for colorectal cancer. *World J Gastroenterol.* 2008;14(42):6536-40.
9. Jensen DM, Machicado GA. Diagnosis and treatment of severe hematochezia. The role of urgent

- colonoscopy after
purge. *Gastroenterol.* 1988;95:1574-96.
10. Ettorre GC, Francioso G, Garribba AP, Fracella MR. Helical CT angiography in gastrointestinal bleeding of obscure origin. *Am J roentgenol.* 1997;168:727-31.
11. Dakubo JCB, Seshie B, Ankrah LAN. Utilisation and diagnostic yield of large bowel endoscopy at

KorleBu Teaching Hospital. *J Medical and Biomed Sci.* 2014;3(1):6-13.

Cite this article as: Arun R, Choksi DB, Patil M, Shah P, Chauhan S. Evaluation of adult cases presenting with bleeding per rectum. *Int Surg J* 2020;7:3651-6.