

Original Research Article

A new cannula for suction removal of parenchymal tissue of gynaecomastia

Mahesh Siddapura Gangegowda, Gagan S. Prakash*, Balaji Ramaiah, Chetan Mali S. M.

Department of Plastic Surgery, Kempegowda Institute of Medical Sciences Hospital, Bangalore, Karnataka, India

Received: 20 September 2019

Accepted: 17 October 2019

***Correspondence:**

Dr. Gagan S. Prakash,

E-mail: gagansp@gmail.com

Copyright: © the author(s), publisher and licensee Medip Academy. This is an open-access article distributed under the terms of the Creative Commons Attribution Non-Commercial License, which permits unrestricted non-commercial use, distribution, and reproduction in any medium, provided the original work is properly cited.

ABSTRACT

Background: There are various surgical techniques that are available for surgical management of gynecomastia. The aim of the study was to evaluate the cosmetic results and patient satisfaction of a combined liposuction with excision for gynecomastia.

Methods: Clinical records of patients affected by gynecomastia referred to our department between 2015 and 2018 were analyzed, total of 23 patients were included in the study.

Results: Overall 23 patients underwent surgery for gynecomastia in the study period, a total of 42 breasts were operated as most of the cases were bilateral in nature. 19 patients had bilateral presentation while 4 patients had unilateral presentation. 35 breasts (80%) were operated with a combined liposuction and excision. Liposuction addresses the fatty gynecomastia whereas open excision is used to remove the glandular enlargement. Four patients underwent excision alone as these patients had a firm retro-areolar lump that was suspicious for malignancy. Another four patients underwent liposuction alone.

Conclusions: Surgery is the main stay of management of gynecomastia. Liposuction with excision has had the best outcome with good cosmetic results, acceptable complication rates and good patient satisfaction.

Keywords: Gynecomastia, Liposuction plus excision, Combined liposuction plus excision

INTRODUCTION

Gynaecomastia is defined as a benign enlargement of the male breast. The term gynecomastia was introduced by Galen during the 2nd century AD.^{1,2} Gynecomastia is said to occur in almost two-thirds of adolescent boys.³ True gynecomastia is associated with glandular breast tissue that is >4 cm in diameter.⁴ Pseudo gynecomastia is due to deposition of adipose tissue or due to the presence of an excessive amount of skin. Physiologic gynecomastia occurs during three phases of normal development i.e., neonates, puberty and ageing. Associated with all these three phases is an imbalance between the oestrogen to androgen ratio.² In the newborn it is due to transfer to maternal and placental hormones into the foetal circulation. During early puberty there is a high ratio of

estrogen to androgen ratio, and in ageing there is increased fat tissue, adipose tissue has high aromatase activity and results in peripheral conversion to testosterone to oestrogen. Pathologic gynecomastia is seen in androgen deficiency states such as Klinefelter's syndrome (XXY), hereditary defects of androgen biosynthesis, trauma, orchitis, cryptorchidism, estrogen excess states like gonadal neoplasms (germ cell or non-germ cell), diseases of the liver like non-alcoholic and alcoholic cirrhosis or pharmacologic causes like administration of ketoconazole, spironolactone.

Reassurance is all that is generally required in most cases of physiological gynecomastia. When a primary cause can be identified and corrected gynecomastia generally subsides over a period of months, gynecomastia of long

duration especially greater than one year, surgery is the most effective treatment. Medical therapy is most effective during the early stages of active proliferation, in long standing cases the tissue is unlikely to regress as the tissue is irreversibly fibrotic. Medically treatment with anti-estrogens such as tamoxifen (20 mg/d) can reduce pain and breast tissue size in over half the patients.⁴ Aromatase inhibitors can be effective in the early proliferative phase of the disorder.⁴

Indications for surgery in a patient with gynecomastia include continued growth, pain or tenderness, severe psychological distress, embarrassment or emotional discomfort to interfere with the patient's daily life, and suspected malignancy. 1% of all breast cancers occur in men. There is no increased risk of breast cancer in patients with gynecomastia when compared with the unaffected male population.⁹ The exception is patients with Klinefelter syndrome. These patients have an approximately 60 times increased risk of breast cancer.

The first procedure used to treat gynecomastia was excision with an extra areolar skin incision, but such extra-areolar skin incisions resulted in unsightly scars, in 1946 Webster published an article in the annals of surgery first describing the semi-circular intra areolar incision on 17 patients requiring 32 mastectomies, which remains the standard incision till date. This incision however cannot be used in large breasts especially when there is excess skin. Illouz introduced body contouring with lipolysis, and described over 3000 cases of suction assisted lipectomy. This enabled the contouring of diffusely enlarged breasts with small scars. Zocchi introduced ultrasound guided lipectomy that could be used for selective destruction of adipose tissue and provide better contouring and aesthetic results.⁷

The most widely accepted classification of gynecomastia is the one suggested by Simon et al. Simon et al divided gynecomastia into four grades.⁸

Grade 1

Small enlargement, no skin excess.

Grade 2a

Moderate enlargement, no skin excess.

Grade 2b

Moderate enlargement with extra skin.

Grade 3

Marked enlargement with extra skin.

In their opinion, grades 2b and 3 require some skin resection. The need for skin excision also depends on the shape of the breast. Large breasts with wide bases may be

treated without skin excision. On the other hand, smaller, narrow breasts may require skin excision.

When the decision has been made to surgically intervene in a case of gynecomastia, there are various surgical modalities that are available at the disposal of the operating surgeon, but no single technique or modality is ideal for all cases of gynecomastia, and in most cases a combination of one or more modalities of surgery need to be employed, in this paper we describe our experience with gynecomastia and the different modalities we have used in our practice.

METHODS

All patients operated for gynecomastia in the Department of Plastic Surgery, between January 2015 to December of 2018 were included in the study. Patients were instructed to follow up on 3rd month, 6th month and 1 year post surgery. Patients were examined by one of the operating surgeons and photographs were taken preoperatively after due consent.

Pre-operative evaluation

Apart from routine pre-op investigations, patients who had a breast mass that was hard or fixed or gave history of recent onset of rapid growth were subjected to a sonomammogram and fine needle aspiration cytology to rule out malignancy endocrinology work up was done for all patients including serum testosterone, beta-human chorionic gonadotropin, estradiol and thyroid stimulating hormone.

Operative technique

All the patients were marked, preoperatively in the standing position with the arms by the side, areas of excess fat and skin were clearly marked. All the cases were done under general anaesthesia. Tumescence technique was used for all patients. After induction with the patient in supine position, a stab incision was made at the inframammary crease along the anterior axillary line to allow for injection of tumescent solution. 1 l of RL with 30 ml of 2% lignocaine with 1 ml of adrenaline was used. About 300-500 ml of solution was injected, until visible tumescence was noted and back flow was noted from the needle on removing the syringe.

Conventional liposuction

After infiltration, we used a special 5 mm grating cannula (serrated) for the initial liposuction, the gratings over the cannula help in the initial liposuction and reduce the manual effort required. A finer 3 mm Mercedes cannula was used for final contouring of the breast. During liposuction care was taken not to injure the pectoralis muscle by applying traction upwards, the contralateral palm was used to constantly assess for the shape and change in contour. A close watch was also kept on the

colour and volume of the aspirate. Once a satisfactory contour was obtained, the surrounding fat was contoured to avoid a noticeable saucer deformity.

Open excision

A circum-areolar incision around the nipple-areolar complex extending from 3 o'clock to 9 o'clock position is placed. Incision is deepened and dissection is carried inferiorly till the lower border of the breast tissue using curved Metzenbaum scissors and electrocautery. While commencing the dissection superiorly about 1-1.5 cm of breast tissue is left on the under surface of the nipple areola complex to prevent post-operative adherence of the nipple areola complex to the chest wall leading to a saucer deformity. The remaining breast tissue is then removed through the semi-circular incision.

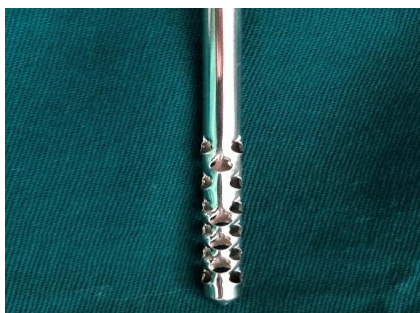

Figure 1: 5 mm grating cannula.

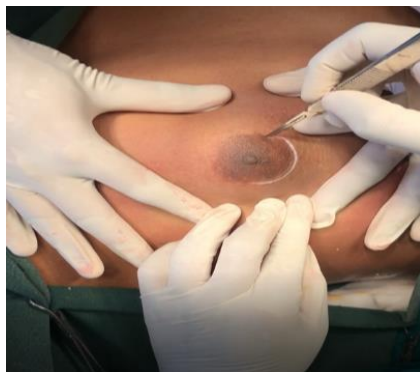

Figure 2: Circum-areolar incision.

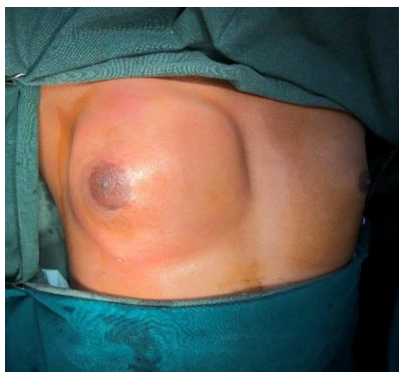

Figure 3: Post injection of tumescent anaesthesia.

Post-surgery suction drain was placed routinely and dressing was done with compressive elastic adhesive bandage to prevent seroma and hematoma formation. Suction drain was removed 48 hours post-surgery. After first dressing on post-op day two, custom made compression garment was given for all patients. Suture removal was done on post op day seven. Patient satisfaction was recorded on subsequent follow up visits.

RESULTS

Overall 23 patients underwent surgery for gynecomastia in the study period, a total of 42 breasts were operated as most the cases were bilateral in nature, 19 patients had bilateral presentation while 4 patients had unilateral presentation. Their ages ranged from 17-49 years (mean-24.5). Most of the breast operated was classified under 1-2b. Most of the cases were treated with liposuction plus excision. 35 breasts (80%) were operated with a combined liposuction and excision. Liposuction addresses the fatty gynecomastia whereas open excision is used to remove the glandular enlargement. Liposuction alone was done in 4 breasts and excision alone in 5 breasts. The mean infiltration volume of tumescent anaesthesia was about 428 ml range between 350-500 ml. Four patients underwent excision alone as these patients had a firm retro-areolar lump that was suspicious for malignancy. Another four patients underwent liposuction alone. Two of these patients had bilateral presentation and other two had unilateral presentation. In the cases with bilateral presentation liposuction alone was done as they had a pure fatty gynecomastia and intraoperatively good results were obtained with liposuction alone, the other two cases were cases of unilateral gynecomastia and the patients underwent liposuction plus excision on the affected side and liposuction was done on the contralateral breast (i.e., the normal breast) for aesthetic symmetrical matching of the chest wall. The mean follow-up time in our study was 4 months (range: 1-12 months).

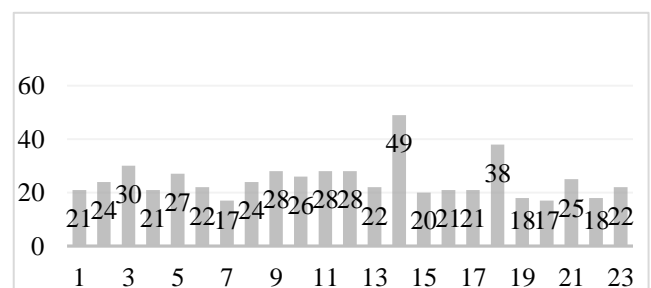


Figure 4: Age distribution.

Complications

2 cases of hematoma were noted in the study, both the cases were taken back to the operating theatre and re-exploration was done and haemostasis achieved. There were no cases of surgical site infection, skin necrosis or residual lumps noted in the surgery.

All the excised breast tissue was sent for routine histopathological examination and the predominant finding was of gynecomastoid hyperplasia. No cases of malignancy were noted in the study.

Table 1: Procedures done.

Liposuction plus excision	Liposuction	Excision
35	4	5
True gynecomastia	Fatty gynecomastia and cosmetic matching	Suspicious for malignancy

DISCUSSION

If well performed, open excision can give excellent results in smaller breast enlargements with distinct subareolar nodules. In more diffuse enlargements and larger breasts it is more difficult to achieve a good result without liposuction. The circum-areolar incision for open excision gives good cosmetic results. The incision should be placed exactly at the margin between the skin and the areola, which results in an almost invisible scar. We routinely used suction drains for all the cases which was removed 48 hours post-surgery and we prescribed custom made chest compression garment for all the patients for a period of 3-6 months. Most of the cases were classified under grade 1 and grade 2a, only 6 cases were classified under grades 2b or 3 with excess skin (Table 2).

Table 2: Degree of gynecomastia.

Degree	No of breasts
Grade 1 and 2a	36
Grades 2b and 3	6

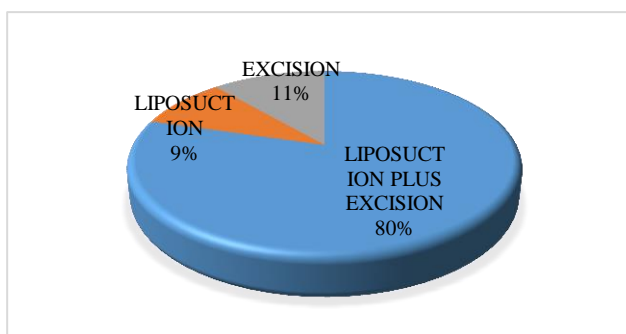


Figure 5: Surgery.

It was found that even patients with excess skin were happy with the cosmetic results post-surgery as the chest wall settles and contracts with customized compression garment over a period of months and we were able to avoid the need for skin excision in most cases. Better cosmetic results were obtained with the liposuction plus excision group and the liposuction alone group. Open excision was done only when there was a suspicion for

malignancy. None of the cases in the study was positive for carcinoma.

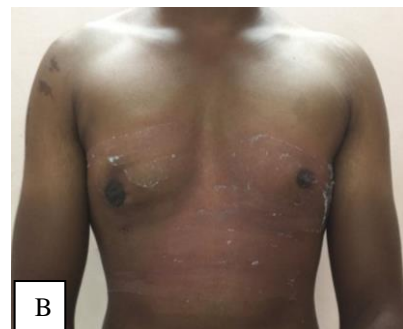
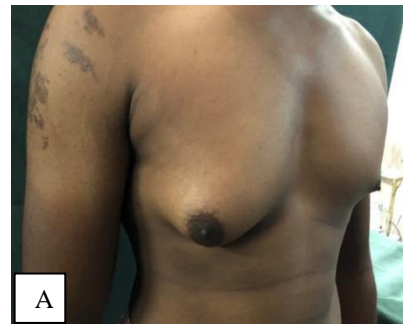
Figure 6 (A-B): A 26 year old patient with right sided unilateral Grade 1 gynecomastia. Patient underwent right liposuction plus excision, pre-op and early post op.

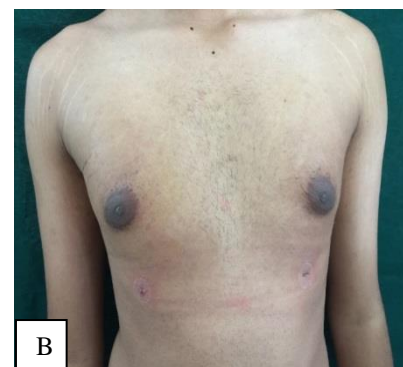
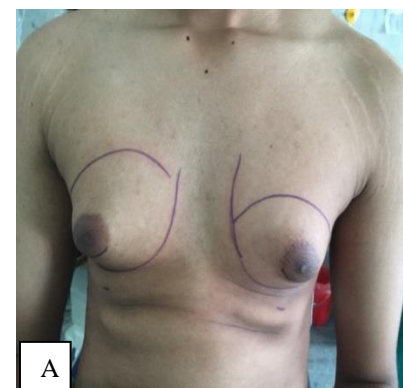


Figure 7 (A-B): 24 year old patient with bilateral gynecomastia, patient underwent bilateral liposuction plus excision, pre-operative, post-operative.

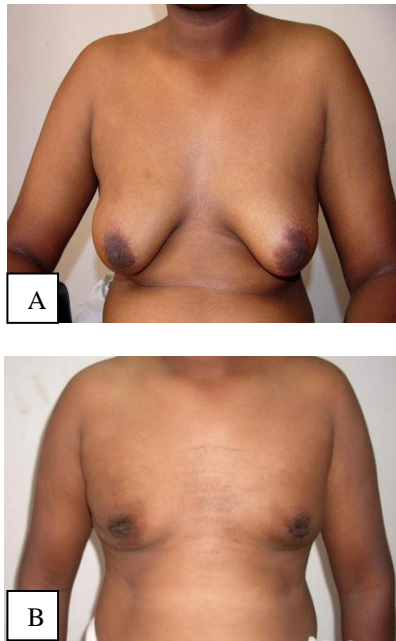


Figure 8 (A-B): A 38 year old patient with bilateral gynecomastia, Grade-4, and patient underwent liposuction plus excision.

CONCLUSION

Surgery is the mainstay of treatment for gynecomastia of all grades, as described there are various surgical modalities available for surgical management, we have found in our study that liposuction with excision had the best outcome, with good cosmetic results, acceptable complication rates and good patient satisfaction.

Funding: No funding sources

Conflict of interest: None declared

Ethical approval: The study was approved by the Institutional Ethics Committee

REFERENCES

1. Goldwyn R. Plastic and Reconstructive Surgery of the Breast. Boston: MA Little Brown; 1976;93:305.
2. McGrath MH. Gynecomastia. In: Jurkiewicz MJ, Mathes SJ, Krizek TJ Ariyan S, eds. Plastic Surgery: Principles and Practice. St. Louis: Mosby; 1990: 1119.
3. Nydick M, Bustos J, Dale JH, Rawson RW. Gynecomastia in adolescent boys. JAMA. 1961;178:449.
4. Bhasin S, Jameson JL. Disorders of the testes and male reproductive system. Harrison's Principles of Internal Medicine. 19th ed. New York: McGraw Hill Education; 2015.
5. Webster JP. Mastectomy for gynaecomastia through a semicircular intra-areolar incision. Ann Surg. 1946;124:557-75.
6. Illouz YG. Body contouring by lipolysis: a 5-year experience with over 3000 cases. Plast Reconstr Surg. 1983;72:591-7.
7. Zocchi M. Ultrasonic liposculpturing. Aesthetic Plast Surg. 1992;16:287-98.
8. Simon BE, Hoffman S, Kahn S. Classification and surgical correction of gynecomastia. Plast Reconstr Surg. 1973;51:48.
9. Cohen IK, Pozez AL, McKeown JE. Gynecomastia. In: Courtiss EH, ed. Male Aesthetic Surgery. St. Louis, MO: Mosby; 1991: 373.
10. Teimourian B, Perlman R. Surgery for gynaecomastia. Aesthetic Plast Surg. 1983;7:155-7.
11. Fruhstorfer BH, Malata. A systematic approach to the surgical treatment of gynaecomastia. Br J Plast Surg. 2003;56(3):237-46.
12. Rosenberg GJ. Gynecomastia: suction lipectomy as a contemporary solution. Plast Reconstr Surg. 1987;80:379-85.
13. Rosenberg GJ. A new cannula for suction removal of parenchymal tissue of gynaecomastia. Plast Reconstr Surg. 1994;94:548-51.

Cite this article as: Gangegowda MS, Prakash GS, Ramaiah B, Mali CSM. A new cannula for suction removal of parenchymal tissue of gynaecomastia. Int Surg J 2019;6:4388-92.