

Case Report

Delayed presentation of extensor pollicis longus tendon injury treated using extensor indicis proprius tendon transfer

Nilesh B. Ghelani, Sankit Shah, Sunmathi B. P.*, Samir Patel

Department of Burns and Plastic Surgery, SCL Hospital, NHL Municipal Medical College, Ahmedabad, Gujarat, India

Received: 23 August 2019

Revised: 16 October 2019

Accepted: 18 October 2019

***Correspondence:**

Dr. Sunmathi B. P.,

E-mail: sanmathirbp@gmail.com

Copyright: © the author(s), publisher and licensee Medip Academy. This is an open-access article distributed under the terms of the Creative Commons Attribution Non-Commercial License, which permits unrestricted non-commercial use, distribution, and reproduction in any medium, provided the original work is properly cited.

ABSTRACT

Spontaneous closed rupture of EPL tendon are frequently associated with rheumatoid arthritis, Colles fracture, sports related injury. In cases of delayed presentation direct tendon repair is not feasible and a tendon transfer is usually recommended. In this study we evaluated the results of extensor indicis proprius (EIP) to extensor pollicis longus (EPL) transfers for EPL ruptures. Four patients, (two male and two females); mean age 32 years (range 20 to 45 years) with EPL tendon rupture underwent EIP to EPL tendon transfer. The mean duration from rupture to surgery was 4.5 weeks (range 4 to 6 weeks). Range of motion of the metacarpophalangeal (MCP), interphalangeal joints (IP) of the thumb and index finger of the operated side was compared with the normal side. The results were scored using geldmacher scheme, for the thumb four functions were scored, the radial abduction angle, the elevation deficit, the opposition distance and flexion extension deficit of MP and IP joints. The mean follow-up period was 5 months. All the four patients were able extend the thumb at MCP joint and oppose the thumb to the MCP of little finger after mean follow up of 5 months. Based on the questionnaire, the results of tendon transfer scored by three (75%) patients was excellent and by one (25%) patient was good. Independent extension of the index finger of operated hand was possible in all 4 patients. The procedure of EIP to EPL tendon transfer provides excellent result for extension of thumb. It is a safe procedure.

Keywords: Extensor pollicis longus, Extensor indicis proprius, Tendon transfer

INTRODUCTION

Spontaneous rupture of the extensor pollicis longus (EPL) tendon is quite frequent and disabling for the patient. Loss of EPL function results in a “dropped thumb” deformity and patient cannot elevate the thumb to the plane of palm. The extensor pollicis tendon present in the third extensor compartment of the wrist provides the extension of the distal phalanx and has a great emphasis for the hand functions. EPL causes the extension of the interphalangeal (IP), metacarpophalangeal (MCP) and carpometacarpal (CMC) joints.

In EPL tendon with clean cut and open wound injury, it is repaired primarily. But usually spontaneous closed rupture of EPL tendon frequently association with rheumatoid arthritis, Colles fracture, sports related injury present sometime later.¹⁻³ In cases of delayed presentation direct tendon repair is not feasible and a tendon transfer is usually recommended.⁴ The use of extensor indicis proprius (EIP), extensor carpi radialis longus (ECRL), extensor pollicis brevis (EPB), abductor pollicis longus (APL), the 3rd and 4th superficial flexor, palmaris longus (PL) for tendon transfer have been described.⁵⁻⁷

EIP tendon transfer for EPL tendon is a good choice because length of EIP is similar to EPL, and both have a similar direction of pull. EIP tendon is expendable as the extension of index finger is not lost. There is no donor site morbidity.

The aim of our study was to observe the long term functional, clinical outcomes and complications of tendon transfer of EIP to EPL to restore the extension of thumb.

CASE REPORT

Four patients who had tendon transfers for EPL tendon rupture between December 2017 to December 2018 in Smt SCL hospital, Ahmedabad. The patients who presented with delayed presentation of rupture of EPL tendon 4 to 6 weeks following trauma was included in our study. Four patients (2 males and 2 females), with mean age of 32 years (20 to 45 years) were presented with inability to extend the thumb few days following trauma. These patients presented with unnoticed injury of

EPL tendon. Among these, one patient had a sharp cut incised wound over wrist for which suturing was done in a local hospital. Three patients had fracture of distal end of radius, one patient was treated conservatively with cast, in other two patients nailing was done. The mean period between the ruptures and the surgery was 4.5 weeks (range 4–6 weeks).

USG of wrist was done to confirm the EPL tendon injury. Before the surgery function and the presence of EIP was evaluated. EIP to EPL tendon transfer was done in these patients under axillary block. The mean follow-up period was 5 months.

To assess the results of thumb function, the elevation of the thumb and opposition of the thumb to metacarpophalangeal (MP) of little finger was assessed. The extension of index finger was measured. The range of motion of thumb and index finger in the operated hand was measured and compared with the other hand.

Table 1: Patient characteristics.

Patient	Gender	Age (yrs)	Etiology	Rupture time before surgery
Patient 1	Female	45	Fracture of distal end of radius	4 weeks
Patient 2	Female	20	Fracture distal Radius, nailing was done	6 weeks
Patient 3	Male	40	Sharp cut incised wound over wrist	4 weeks
Patient 4	Male	27	Fracture distal radius, nailing was done	4 weeks

Table 2: Gelmacher evaluation scheme for scoring the results of extensor tendon repair.

Function	Score (points)	
Radial abduction range (angle between thumb and index finger) (°)	>70	6
	51-70	4
	31-50	2
	9-30	0
Elevation deficit (cm)	0.0-1.0	6
	1.1-2.0	4
	2.1-3.0	2
	>3.0	0
Opposition distance (distance of thumb tip to MP of the little finger) (cm)	0.0-2.5	6
	2.5-4.0	4
	4.1-6.0	2
	>6.0	0
Flexion extension deficit (difference from non-operated hand) (°)	0-5	6
	6-30	4
	31-60	2
	>60	0

Surgical technique

EIP tendon was identified preoperatively, it is usually located on the ulnar side of Extensor digitorum communis tendon to index finger. Its function is assessed by extension of the index finger at MCP and

interphalangeal (IP) joints. All patient was operated under axillary block. Tourniquet was used in all patients.

Schneider and Rosenstein (1983) described the technique of EIP-EPL transfer.⁸ A small transverse incision was made just below the MP joint of the index finger, EIP

tendon located on the ulnar side was identified, isolated and cut. another small transverse incision was made at the level of wrist below the thumb. Transected EPL tendon is identified. The cut EIP tendon is retrieved through this incision by subcutaneous tunneling. The EIP tendon was sutured to the distal stump of EPL tendon using pulvertaft weaving technique with ethilon 3.0. Tension adjustment should be done such that thumb is in full flexion, wrist in full extension and while thumb was in full extension, the wrist was in flexion. To obtain appropriate tension, extension posture of thumb was maintained by giving a splint, with extension of thumb MCP and IP, extension of wrist in 30 degrees and IP joint of other finger in extension, flexion 60 degrees at MCP of other fingers for two weeks, followed by thumb splint for next 4 weeks. Immobilization was maintained for 6 weeks. Active motion was permitted after 6 weeks. Passive motion was started after 3 months. The results were scored using Geldmacher scheme.⁵

Case 1

A female patient aged 20 yrs, presented with inability to extend the right thumb above the plane of palm, patient was treated with nailing for fracture of distal end of radius six weeks back. She was treated with EIP to EPL tendon transfer.

As shown in Figure 2 incision lines are planned for the patient with EPL injury, EIP tendon was identified preoperatively, it is usually located on the ulnar side of Extensor digitorum communis tendon to index finger.

Case 2

A male patient aged 27 yrs, presented with inability to extend the right thumb above the plane of palm, patient was treated with nailing for fracture of distal end of radius four weeks back. He was treated with EIP to EPL tendon transfer (Figure 3).

Case 3

A female patient aged 45 yrs, presented with inability to extend the right thumb above the plane of palm, patient was treated conservatively with cast for fracture of distal end of radius four weeks back. She was treated with EIP to EPL tendon transfer.

Case 4

A male patient aged 40 yrs, presented presented with inability to extend the right thumb above the plane of palm, patient was treated with nailing for fracture of distal end of radius four weeks back. She was treated with EIP to EPL tendon transfer.

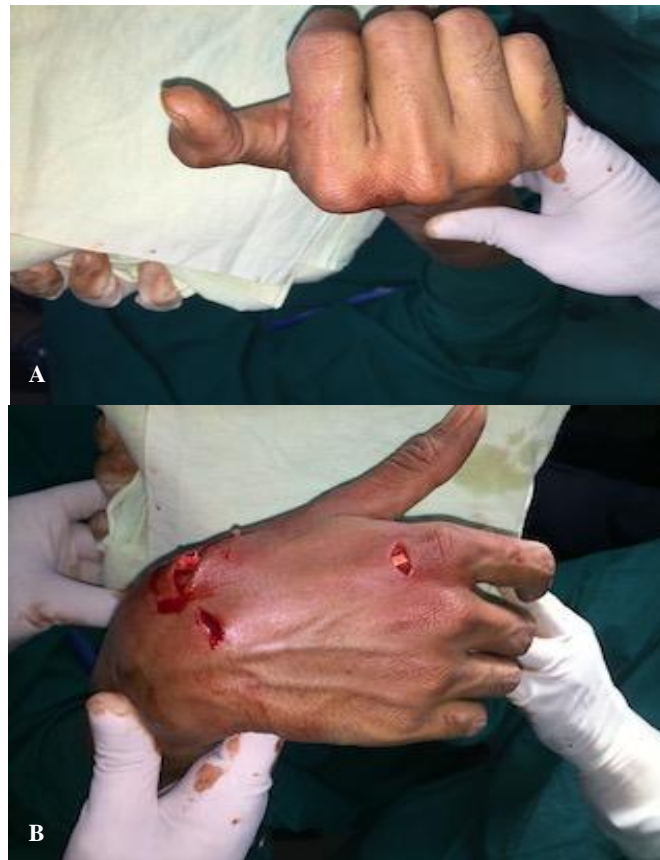

Figure 1: (A) Tension setting is done such that when the wrist is extended, thumb IP joint is flexed, (B) thumb is extended when the wrist is flexed.

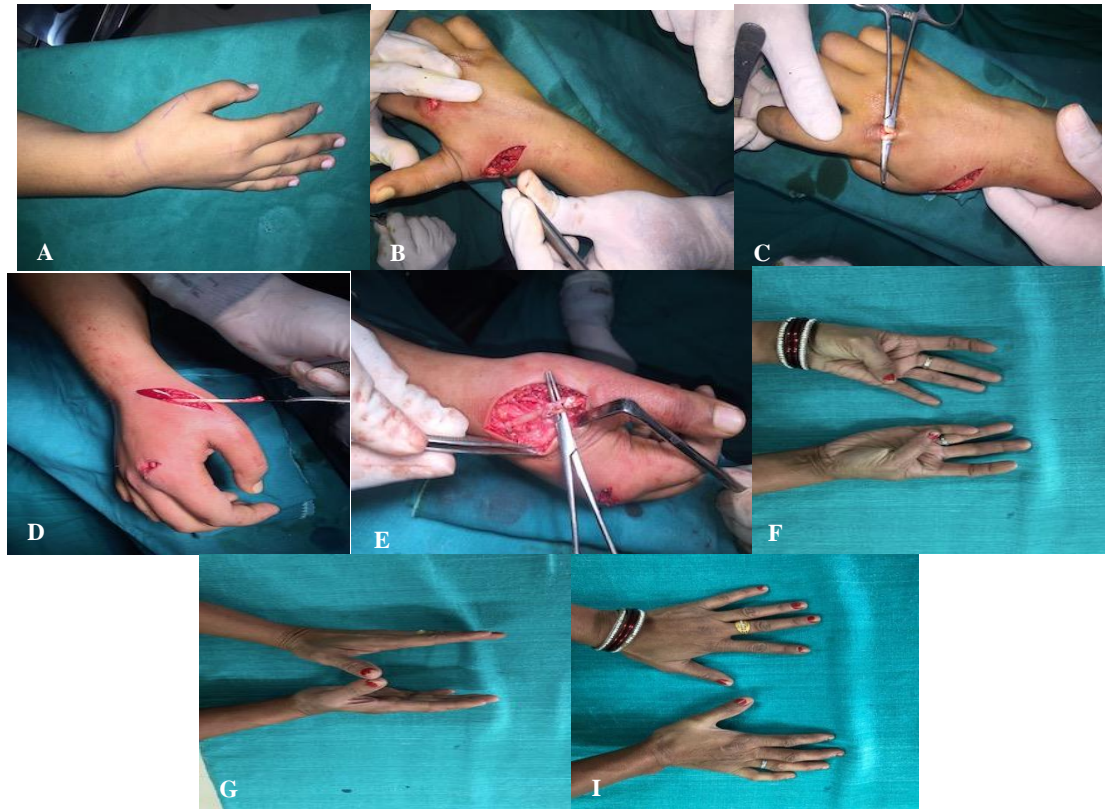

Figure 2: (A and B): Another small transverse incision was made at the level of wrist below the thumb. Transected EPL tendon is identified. (C) Small transverse incision was made just below the MP joint of the index finger. EIP tendon located on the ulnar side was identified, isolated and cut. (D) The cut EIP tendon is retrieved through this incision by subcutaneous tunneling. (E) The EIP tendon was sutured to the distal stump of EPL tendon using pulvertaft weaving technique with Ethilon 3.0. (G, H and I) 2i post op image of the patient, after 6 weeks patient is able to elevate the right thumb above the plane of palm.

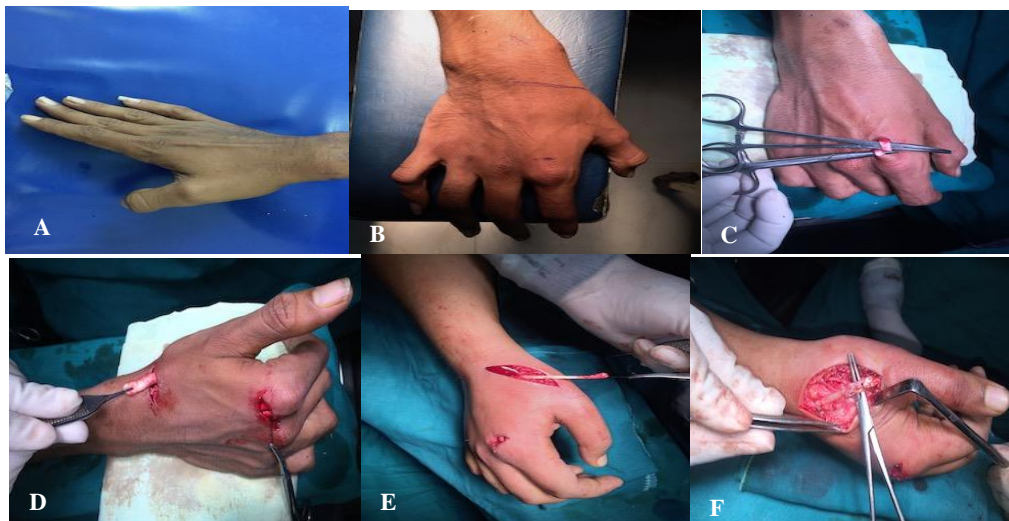


Figure 3: (A) Pre-op image, patient is not able to elevate the thumb above the plane of palm, (B) 27 year old male patient with EPL injury, incision lines are planned for the patient with EPL injury. EIP tendon was identified preoperatively, it is usually located on the ulnar side of Extensor digitorum communis tendon to index finger, (C) small transverse incision was made just below the MP joint of the index finger, EIP tendon located on the ulnar side was identified, isolated and cut, (D) another small transverse incision was made at the level of wrist below the thumb. Transected EPL tendon is identified, (E) the cut EIP tendon is retrieved through this incision by subcutaneous tunneling, (F) the EIP tendon was sutured to the distal stump of EPL tendon using pulvertaft weaving technique with Ethilon 3.0

Table 3: Outcome as per Geldmacher scheme score.

Patients	Score (points) (Geldmacher scheme)	Outcome
Patient 1	23	Excellent
Patient 2	22	Excellent
Patient 3	18	Good
Patient 4	23	Excellent

DISCUSSION

The function of EPL, is to produce extension of IP, MP and TM joints of thumb. EPL also causes adduction at TM joint. Loss of EPL function causes a “dropped thumb” deformity and cannot elevate the thumb to the plane of palm. The functional status in EPL rupture is closely related to EPB and thumb ray joints. After the rupture, the thumb can reach to the neutral position with the intrinsic muscles at IP joint. The EPL is necessary for hyperextension of the thumb. The extension deficit is seen at MCP joint because the EPB cannot extend the joint alone.

Spontaneous Rupture of EPL is, though uncommon is well-known feature-after fracture of distal radius. It is also seen secondary to internal fixation implants used to stabilize the fractures. Tendon rupture may occur in the absence of sharp injuries such as in Rheumatoid arthritis and repetitive microtrauma (overuse). In delayed presentation, due to myostatic contraction, proximal end shortening occurs and therefore primary repair of tendon is not feasible.

Tendon transfers and tendon grafts are the treatment options for chronic/old EPL ruptures. Both these techniques have their own advantages and disadvantages. Free intercalated tendon grafts of palmaris longus tendon is widely used for treating EPL ruptures. Schaller et al compared the results of EIP to EPL tendon transfers and free intercalated tendon grafts for isolated secondary reconstruction of the EPL tendon and found no significant differences between them. However, the tendon grafting operation requires two tendon suture sites, has the risk of developing avascular necrosis, and is faced with the difficulty of setting the correct tension due to myostatic contracture. Another advantage of tendon grafting technique is using of original route and not subcutaneous route of EPL.⁴

Tendon transfer using ECRL, EPB, APL, EIP have been described to reconstruct EPL. In our study EIP tendon transfer was done for chronic EPL injury. EIP transfer is a good option, as there is no lack of independent extension of index finger after transfer. although there may be limited function deficit of index finger, such as extension lag and postoperative weakness, may be the possible complications after EIP tendon transfer, though it does not seem to pose a significant problem for the patient.

EIP tendon to EPL tendon transfer is a simple technique with a short operative time. uses one tendon suture site. EIP tendon transfer has a low morbidity rate. Trevor was the first to cite about biomechanical properties of the EI transfer and few other authors emphasized the success of this transfer.⁸⁻¹⁰ The anatomical variation of of EIP tendon should be kept in mind. Cauldwell reported the prevalence of EIP tendon variations as much as 16.8%.^{11,12}

There are several factors affecting the functional outcomes of EIP tendon transfers, the most important being appropriate tension setting. The standard tensioning position in EIP to EPL transfers is full flexion of thumb when wrist in extension and opposition of the thumb was possible while in full extension when the wrist was in flexion

ECRL and ECRB are the other options for tendon transfer but there is certain loss on radial side in wrist extension as ECRL and ECRB is an important extensor.

In musicians and those who have to use keyboard, EI tendon transfer can cause independent second finger extension loss.

In shah et al, highlighted that closest transfer to EPL functions is the transfer that has been made in such a way that, as being similar to EPL of EI tendon with a pulley formed from 4th compartment retinaculum.¹³

In our study, the results were scored using Geldmacher scheme 5, for the thumb four functions must be scored, the radial abduction angle, the elevation deficit, the opposition distance and flexion extension deficit of MP and IP joints. The geldmacher grading scale is excellent, 24 to 22 points, good 21 to 17 points, satisfactory 16 to 10 points and poor 9 to 0 points.

The extension and the opposition of the thumb to the MP of little finger was unimpaired in all four patients. There was no extension lag in the index finger of all four patients. There was no significant difference in the function and range of motion between injured and uninjured thumb. There were no complications observed postoperatively.

Based on the questionnaire, the results of tendon transfer scored by 3 (75%) patients was excellent and by one (25%) patient was good.

Lemmen et al described the excellent to good results in 11 of 17 patients with the combined etiologies of trauma and inflammatory arthritis.⁵ Ozalp et al shown the results of EIP transfer for the treatment for EPL tendon rupture in 21 patients with rheumatoid arthritis.⁷ in our study, Based on the questionnaire, the results of tendon transfer scored by 3 (75%) patients was excellent and by one (25%) patient was good.

CONCLUSION

The procedure of EIP to EPL tendon transfer technique is the best option for EPL tendon injury. It is a simple procedure with minimal complication and morbidity in the patients with ruptured EPL and delayed presentation. Appropriate tension adjustment is also important for good functional outcomes of EIP tendon transfers. In delayed presentation, tendon transfer thus avoids the need of direct suturing of the degenerated tendon and tendon grafting. It has the risk of developing avascular necrosis, and is faced with the difficulty of setting the correct tension due to myostatic contracture. The EIP tendon transfer for EPL tendon rupture provides very good functional outcome with less donor site morbidity.

Funding: No funding sources

Conflict of interest: None declared

Ethical approval: Not required

REFERENCES

1. Mannerfelt L, Oetker R, Ostlund B, Elbert B. Rupture of the extensor pollicis longus tendon after Colles fracture and by rheumatoid arthritis. *J Hand Surg Br.* 1990;15(1):49–50.
2. Roth KM, Blazar PE, Earp BE, Han R, Leung A. Incidence of Extensor Pollicis Longus Tendon Rupture After Nondisplaced Distal Radius Fractures. *Journal of Hand Surgery.* 2012;37(5):942–7.
3. Dawson WJ. Sports-induced spontaneous rupture of the extensor pollicis longus tendon. *J Hand Surg Am.* 1992;17(3):457–8.
4. Sahin C, Öztürk S, Sever C, Eren F, Uslu A. Tension setting for extensor indicis proprius to extensor pollicis longus transfer using the wide-awake approach. *Hand and Microsurgery.* 2015;1.
5. Lemmen MH, Schreuders TA, Stam HJ, Hovius SE. Evaluation of restoration of extensor pollicis function by transfer of the extensor indicis. *J Hand Surg Br.* 1999;24(1):46–9.
6. Viegas SF. A new modification of extensor indicis proprius transfer to extensor pollicis longus using a retinacular pulley. *Tech Hand Up Extrem Surg.* 2003;7(4):147–50.
7. Ozalp T, Ozdemir O, Coşkunol E, Erkan S, Calli IH. Extensor indicis proprius transfers for extensor pollicis longus ruptures secondary to rheumatoid arthritis. *Acta Orthop Traumatol Turc.* 2007;41(1):48–52.
8. Schneider LH, Rosenstein RG. Restoration of extensor pollicis longus function by tendon transfer. *Plast Reconstr Surg.* 1983;71(4):533–7.
9. Moore JR, Weiland AJ, Valdata L. Tendon ruptures in the rheumatoid hand: analysis of treatment and functional results in 60 patients. *J Hand Surg [Am].* 1987;12:9-14.
10. Noorda RJ, Hage JJ. Extensor indicis proprius transfer for loss of extensor pollicis longus function. *Arch Orthop Trauma Surg.* 1994;113:327-9.
11. Cauldwell EW, Anson BJ, Wright RR. The extensor indicis proprius muscle - a study of 263 consecutive specimens. *Q Bull Northwest Univ Med Sch.* 1943;17(4):267–79
12. Yu W. Long-Term Functional Evaluation on Tendon Transfer to Restore Extension of the Thumb using Extensor Carpi Radialis Brevis. *International Journal of Surgery Research & Practice.* 2015.
13. Shah MA, Buford WL, Viegas SF. Effects of extensor pollicis longus transposition and extensor indicis proprius transfer to extensor pollicis longus on thumb mechanics. *J Hand Surg Am.* 2003;28(4):661–8.

Cite this article as: Ghelani NB, Shah S, Sunmathi BP, Patel S. Delayed presentation of extensor pollicis longus tendon injury treated using extensor indicis proprius tendon transfer. *Int Surg J* 2019;6:4138-43.