

Case Report

A large ureteric calculus: is there a role for open surgery in the modern era?

Haraesh Maranna*, Tariq Hameed, Pawan Lal

Department of Surgery, Maulana Azad Medical College and Associated Hospitals, New Delhi, India

Received: 14 August 2019

Accepted: 13 September 2019

***Correspondence:**

Dr. Haraesh Maranna,

E-mail: haraesh92@yahoo.co.in

Copyright: © the author(s), publisher and licensee Medip Academy. This is an open-access article distributed under the terms of the Creative Commons Attribution Non-Commercial License, which permits unrestricted non-commercial use, distribution, and reproduction in any medium, provided the original work is properly cited.

ABSTRACT

A 36 year old gentleman presented with recurrent urinary tract infections, hematuria and lump in the left side of abdomen for 4 months. Clinically a soft, non-tender lump in left lumbar region with well-defined margins was palpable. CT scan of abdomen revealed a calculus of size 45 mm at the left vesico-ureteric junction with gross left hydronephrosis. Patient underwent open ureterolithotomy in view of the large size of calculus and due to stone impaction. Post-operative period was uneventful. Patient was followed up for 6 months and remained asymptomatic.

Keywords: Recurrent urinary tract infection, Open ureterolithotomy, Large ureteric calculus

INTRODUCTION

Ureteric stones are usually small and present with loin pain. The stones are composed of calcium oxalate or phosphate in 80% of cases. Struvite (magnesium ammonium phosphate), cysteine and uric acid are other types of stones.¹ The spontaneous passage of the ureteral stones is depends upon both the location (proximal, mid, and distal ureter) and size of the stone.² Blockage of ureter due to stones can lead to ureteric colic. Ureteric obstruction can leading to impaired renal function and dilation of kidneys.³ Open ureterolithotomy was performed for ureteric calculus more than 1 cm size. Technological advancements in the last two decades have led to developments such as extracorporeal shock wave lithotripsy (ESWL) and endoscopic procedures like ureteroscopic lithotripsy.⁴

Recently laparoscopic ureterolithotomy have been tried for ureteric stones.⁵ In this article, we report a case of a large ureteric calculus for which open ureterolithotomy was performed.

CASE REPORT

A 36 year old male presented with complaints of recurrent urinary tract infection, hematuria and left side abdominal lump of 4 months duration. The patient had recurrent left side colicky abdominal pain for 3 months which was relieved after taking analgesics. On examination a retroperitoneal lump of size 10×8 cms was palpable in the left lumbar region. The lump was non tender, soft and all margins were well appreciable. Blood investigations were done and complete blood count, renal function tests, liver function tests were normal. Urine microscopic examination revealed presence of oxalate crystals and microscopic hematuria. An X-ray kidney ureter and bladder (KUB) was done which showed a large left lower ureteric calculus (Figure 1). CT scan of abdomen showed a calculus of 45 mm at the left vesico-ureteric junction with gross hydronephrosis of left kidney (Figure 2). A 99 m Tc-DTPA renal dynamic study was done to find out the functional status of the kidneys. The scan revealed enlarged hydronephrotic left kidney with poor cortical function, right kidney normal in size and cortical function (Figure 3). The split glomerular

filtration rate (GFR) was 29% left and 71% right kidney respectively.

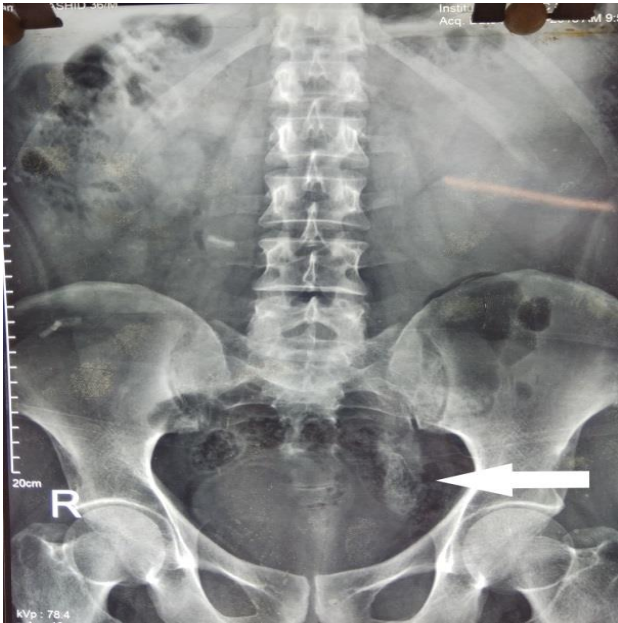


Figure 1: A plain radiograph of kidney ureter bladder showing left lower ureteric calculus.

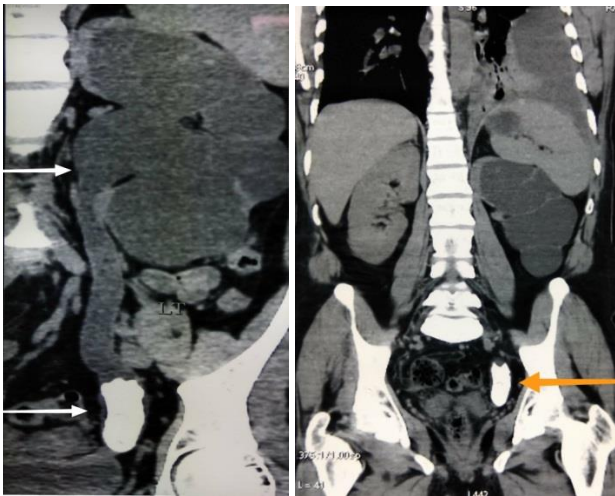


Figure 2 (A and B): A CT scan of abdomen showing a 45 mm calculus in the left vesico-ureteric junction with dilated left ureter and gross hydronephrosis of left kidney.

Patient was planned for open ureterolithotomy in view of the large size of calculus and due to impaction of stone in the vesico-ureteric junction. A left suprapubic incision was made and retroperitoneal space was entered. Dilated left upper ureter with hydronephrotic left kidney was noted. Open left ureterolithotomy was done and the calculus was extracted and primary closure of ureter was done (Figure 4). A drain was placed in the left retroperitoneal region and wound closed in layers. A post-operative X-ray KUB showed no residual calculus. Post-operative period was uneventful and the patient was

passing clear urine. Drain was removed on post-operative day 3. The patient was followed up regularly and the size of abdominal lump had reduced and the patient remained asymptomatic. A follow up ultrasonogram was done after 3 months which showed a decrease in hydronephrosis of left kidney.

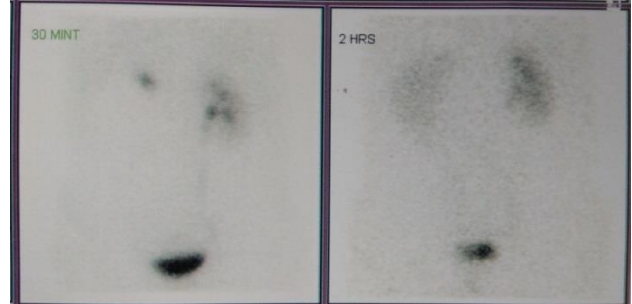


Figure 3: DTPA scan showing poor cortical function in left kidney and normally functioning right kidney.



Figure 4: Extracted stone of 45 mm from the left vesico-ureteric junction.

DISCUSSION

Ureteric stones are common problems encountered in surgical practice. While smaller stones may have spontaneous expulsion, larger stones require surgical intervention. The longest stone reported so far was by Taylor in 1934 which was 21.5 cm in length.⁶ The largest ureteric calculus was reported by Mayer in 1934, which measured 11×5.5×5 cm and weighted 286 g.⁷ Improvements in ESWL and ureteroscopic procedures has almost eradicated the need for open surgery in management of ureteric stones.⁸ Laparoscopic

ureterolithotomy, a minimally invasive alternative to open ureterolithotomy has been performed for large ureteric stones.⁹ The disadvantages include the longer operative time, the risk of injury to intra-abdominal structures inherent in the laparoscopic approach, the risk of postoperative urinoma and the conversion to open surgery.¹⁰ Decreased morbidity, reduced hospitalisation and therefore reduced costs have led endoscopic surgeries being the first line of management for ureteric stones.^{10,11} The current indications for open surgery for management of ureteric stones include high risk patients, precluding multiple general or major regional anaesthesia, anatomical abnormalities of the ureter that prevent ureteroscopy, failure of minimal invasive methods, large impacted calculus, previous open ureteric surgery (including ureteric re-implantation or anti-reflux procedures) and patient preference.^{8,11,12} Spinal deformities which prevent patient positioning for ureteroscopy is another indication for open ureterolithotomy.¹³ The treatment options should always be discussed with the patient. In our patient open surgery was performed due to the size of the stone and due to stone impaction and the anticipated difficulties during endoscopic approaches. Although we are continuously pushing the boundaries of endoscopic management of ureteric stones, open surgery is occasionally the most effective approach.¹⁴

CONCLUSION

Our case demonstrates that despite the various developments in endoscopic technologies, there is still an important role for open surgical management of certain ureteric stones.

Funding: No funding sources

Conflict of interest: None declared

Ethical approval: Not required

REFERENCES

1. Hammady A, Gamal WM, Zaki M, Hussein M, Abuzeid A. Evaluation of ureteral stent placement after retroperitoneal laparoscopic ureterolithotomy for upper ureteral stone: randomized controlled study. *J Endourol.* 2011;25(5):825-30.
2. Perez Castro E, Osther PJ, Jinga V, Razvi H, Stravodimos KG, Parikh K. Differences in ureteroscopic stone treatment and outcomes for distal, mid-, proximal, or multiple ureteral locations: the clinical research office of the endourological Society Ureteroscopy Global Study. *Eur Urol.* 2014;66(1):102-9.
3. Swenson DW, Darge K, Ziniel SI, Chow JS. Characterizing upper urinary tract dilation on ultrasound: a survey of North American pediatric radiologists' practices. *Pediatr Radiol.* 2015;45(5):686-94.
4. Ather M, Paryani J, Memon A, Sulaiman M. A 10-year experience of managing ureteric calculi: changing trends towards endourological intervention-is there a role for open surgery? *BJU Int.* 2001;88(3):173-7.
5. Harewood L, Webb D, Pope A. Laparoscopic ureterolithotomy: the results of an initial series, and an evaluation of its role in the management of ureteric calculi. *Br J Urol.* 1994;74(2):170-6.
6. Taylor WM. Large ureteral calculi. Report of a case. *J Urol.* 1934;32(1):93-102.
7. Mayers MM. A Giant Ureteral Calculus (Weight: 286 Grams). *J Urol.* 1940;44(1):47-53.
8. Muslumanoglu A, Karadag M, Tefekli A, Altunrende F, Tok A, Berberoglu Y. When is open ureterolithotomy indicated for the treatment of ureteral stones? *Int J Urol.* 2006;13(11):1385-8.
9. Rathod R, Gutta S, Bansal P. A giant ureteric calculus. *Indian J Urol.* 2013;29(3):263.
10. Hamdi S, Kenan. A simple manipulation for removal of large distal ureteral stone during standart ureterolithotomy: A Case Report. *Int J Urol.* 2007;5(1).
11. Kane C, Bolton D, Stoller M. Current indications for open stone surgery in an endourology center. *Urology.* 1995;45(2):218-221.
12. Paik M, Wainstein M, Spirnak J, Hampel N, Resnick M. Current indications for open stone surgery in the treatment of renal and ureteral calculi. *J Urol.* 1998;159(2):374-9.
13. Teo J, Goh E, Teoh B, Git K. Open Ureterolithotomy In an Era of Endoscopic Surgery for a Patient with Spina Bifida: Was It an Appropriate Decision? *UroToday Int J.* 2012;5(5).
14. Cancian M, Brito J, Renzulli J, Pareek G. Endourologic and Open Ureterolithotomy and Common Sheath Reimplant for Large Bladder and Distal Ureteral Calculi. *J Endourol Case Reports.* 2016;2(1):209-11.

Cite this article as: Maranna H, Hameed T, Lal P. A large ureteric calculus: is there a role for open surgery in the modern era?. *Int Surg J* 2019;6:3860-2.