

## Case Report

# A rare case of shoulder swelling: epithelioid sarcoma- case report

**Shivmurthy Khandalkar, Aditya Ghatnekar\*, Virendra S. Athavale, Trupti Tonape, K. Srilikhitha, Kuldip A. Patil, Miten Ranka, Shweta Kutty, Jyotsna Gogineni, Sree Kumar B.**

Department of General Surgery, D. Y. Patil Medical College, Pune, Maharashtra, India

**Received:** 31 July 2019

**Revised:** 15 September 2019

**Accepted:** 16 September 2019

**\*Correspondence:**

Dr. Aditya Ghatnekar,

E-mail: [likitha.093@gmail.com](mailto:likitha.093@gmail.com)

**Copyright:** © the author(s), publisher and licensee Medip Academy. This is an open-access article distributed under the terms of the Creative Commons Attribution Non-Commercial License, which permits unrestricted non-commercial use, distribution, and reproduction in any medium, provided the original work is properly cited.

### ABSTRACT

Epithelioid sarcoma is a rare soft tissue sarcoma classified under tumor of uncertain histogenesis. Incidence being 0.4/million/year, it is divided into proximal variant-where in the proximal parts of the body are more involved and distal variant which is commoner and less aggressive of the two predominantly involving distal parts of upper limb followed by distal lower extremities and proximal upper limb. It has a male preponderance (1.8:1), although females have better prognosis comparatively, also it has a tendency of lymphatic spread with 13% metastasis. Recurrence of 77% is reported. Definitive diagnosis is made only on tissue biopsy. Most common variant is pseudo granulomatous type. This case report is based on a case which presented with a single right anterior shoulder swelling and was found to be of epithelioid sarcoma on biopsy. A 60 years old female patient came to OPD of D. Y. Patil Medical College, Pune, with complaints of swelling over her right shoulder since 1 month, initially small and gradually increasing in size of swelling. No history of pain and loss of appetite or weight. On examination, a 4×3 cms firm to hard swelling present over anterior part of right shoulder. It was observed to be non-tender, well defined and mobile. Patient has been investigated with X-ray, FNAC, and ultrasound of the swelling. FNAC was significant other giant cell lesion of soft tissue hence taken up for excision biopsy which showed epithelioid sarcoma on histopathology with faint focal positivity for pancytokeratin and EMA and negative for LCA, CK-3 and S-100.

**Keywords:** Tumors, Epithelioid sarcoma, EMA positive tumors, Shoulder swelling, Soft tissue tumors, Hard woody knot

### INTRODUCTION

Epithelioid sarcoma is a rare soft tissue sarcoma of uncertain histogenesis.<sup>1</sup> It is a high grade soft tissue tumor that has a known propensity for local recurrence, regional lymph node involvement, and distant metastases.<sup>2</sup> Patients have been described as presenting with either a superficial lesion or deep lesions, usually of the extremities. The superficial lesions are described as a “hard woody knot”.<sup>3</sup> These rarely limit function but often ulcerate later in their course. They are frequently mistaken for ulcers, abscesses, or infected warts that fail medical management. Part of the diagnostic dilemma is

the “deceptively harmless appearance during the initial period of the disease.”<sup>4</sup> Because epithelioid sarcoma presents innocuously, it is often mistaken as a benign process, which can result in insufficient treatment.

Therefore, we present this case to emphasize the need for clinicians to consider this diagnosis when a slow growing tumor is found on the extremity.

### CASE REPORT

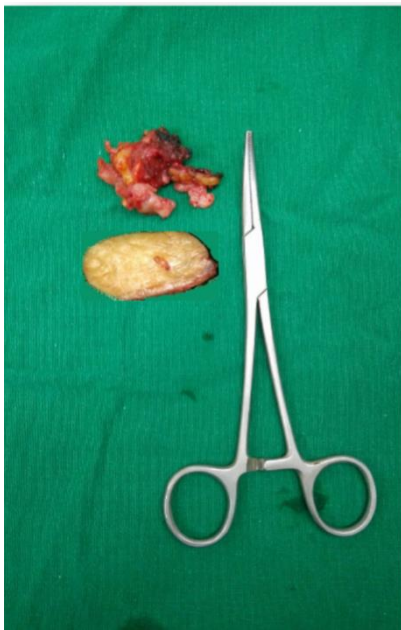A 60 years old female patient from Pune came to OPD of Dr. D. Y. Patil hospital, Pune with complaints of swelling

over her right shoulder since 1 month. Initially small gradually progressed to the present size of approximately 3×4 cms. No history of pain or trauma. No history of tingling sensations and no h/o difficulty in limb movements. No history of fever or nausea or vomiting. No history of other swellings in the body.

On examination, A well-defined ~ 4×3 cms swelling is seen over anterior part of right shoulder. Skin over the swelling appears normal. Non-tender and there was no local rise of temperature, firm to hard in consistency, and was mobile. Skin over the swelling was pinchable. No restriction of hand movements. No lymphadenopathy. Systemic examination was within normal limits.

On X-ray of right shoulder was normal. USG was significant other thick walled well defined lesion, neurogenic tumour. FNAC was significant other giant cell lesion of soft tissue.

Following which patient was taken up for wide local excisional biopsy.



**Figure 1: Excised specimen of the swelling.**

HPE of the excision biopsy was significant other epithelioid sarcoma with faint focal positivity for pancytokeratin and EMA and negative for LCA, CK- 3 and S-100 with free margins.

Medical oncologist opinion was taken in view of the HPE report, was advised to get evaluated for metastasis and to undergo radiotherapy.

On further evaluation, USG of abdomen and pelvis showed no abnormalities. HRCT thorax significant other ill-defined small sub pleural nodule (3 mm) in anterior segment of right upper lobe. Following which she had

undergone radiotherapy, as per medical oncologist advice.

## DISCUSSION

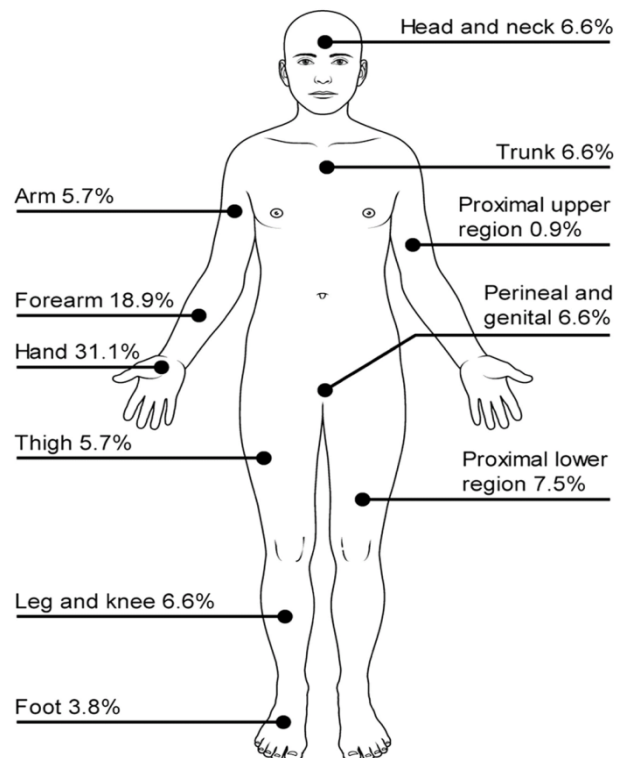
Epithelioid sarcoma (ES) is a rare, high-grade malignancy that represents the most common primary soft tissue sarcomas of the hand. It is classified under tumour of uncertain histogenesis.

It was first described by Enzinger in 1970, typically presenting as a subcutaneous nodule or deep dermal mass in the distal extremities.<sup>2</sup> Proximal variant was first described in 1997 by Guillou et al.<sup>5</sup>

Incidence is 0.04/million/year in 2005 with male: female ratio being 1.8:1, with females having better prognosis.

It is divided into two variants: distal and proximal

Proximal where the former is more common and less aggressive of the two. The most common primary site for epithelioid sarcomas is distal upper extremities followed by distal lower extremities and proximal extremities.



**Figure 2: Percentage of site of occurrence.**

Most tumors present as a firm to hard palpable mass either in deep tissues or in the dermis. The superficial lesions often ulcerate causing a mistaken diagnosis, where as deep tumors may mimic ganglion cysts or be attached to tendon sheaths and be mistaken for giant cell tumors.

About 13% present with multifocal tumors and about 13% present with metastatic disease. Definitive diagnosis

is made only on tissue biopsy with immunohistochemical markers.

**Table 1: Positive IHC in conventional and large cell subtypes in 106 cases of epithelioid sarcoma.<sup>6</sup>**

Antibody	Conventional (n=70)	Large cell (n=36)	Total (n=106)
	N (%)	N (%)	N (%)
<b>Vimentin</b>	70 (100)	36 (100)	106 (100.0)
<b>AE1/AE3</b>	68 (97)	34 (94)	102 (96.2)
<b>Epithelial membrane antigen</b>	69 (99)	35 (97)	104 (98.1)
<b>CD34</b>	42 (60)	24 (67)	66 (62.3)
<b>S-100 Protein</b>	13 (19)	3 (8)	16 (15.1)
<b>INI1</b>	57 (81)	29 (81)	86 (81.1)

\*: Data are given as number (percentage).

It has a tendency to spread by lymphatics with, metastatic rate of 45%, of which more common are to lung. Recurrence rate is reported to be 77%. Loss of INI1 (aka hSNF5 and SMARCB1) has been seen in 80% of epithelioid sarcomas.<sup>4</sup>

MRI is the modality of choice for diagnosis prior to biopsy and pathologic diagnosis as it helps in determining anatomic boundaries. Also helps in differentiating recurrence from postoperative changes after multiple excisions.

Immunohistochemical studies have shown that vimentin reactivity is present in almost all cases. Cytokeratin AE1/AE3 and epithelial membrane antigen were positive in 96% and 98% of the cases respectively. There is consistent staining for CA-125, and some have suggested using it as a serum marker to monitor for metastasis.<sup>6</sup>

Negative S100 is typical (distinguishing it from malignant peripheral nerve sheath tumor), endothelial markers (distinguishing it from epithelioid angiosarcoma), CK5/6 (distinguishing it from squamous cell carcinoma).<sup>6</sup>

CD34 is expressed in 50-60% of epithelioid sarcomas, but is negative in carcinomas, helping to distinguish the two. P63 is also a useful marker that is present in virtually all squamous cell carcinomas, but absent in epithelioid sarcomas.<sup>6</sup>

Wide surgical resection remains the most recommended treatment modality. Epithelioid sarcoma has recurrence rates of up to 77% after marginal resection in some long-term studies. It has also been noted to spread proximally in the same limb, distant to the original tumor (so-called "local metastasis").

Amputation can be considered if there are multiple recurrences or if there is not a significant loss of function (like a fingertip). However, it does not seem to help with "local metastasis" control.

### **Role of adjuvants**

As epithelioid sarcoma is rare and slow growing, makes it difficult to have long term follow up to find significant difference between different adjuvant treatment methods. Radiation therapy is used in some institutions for primary and recurrent cases for limb salvage, with favorable results compared to amputation.<sup>7</sup>

The late effects (scarring, stiffness, and neuropathy) can be particularly debilitating in the hand. Chemotherapy (doxorubicin) has been used for multifocal, large (>5 cm), or metastatic disease. It has not been shown to improve survivorship. The better prognostic factors includes younger age at presentation, female gender, smaller size <2 cm, site at distal extremities, stage of the disease, low mitotic index.

### **CONCLUSION**

Epithelioid sarcoma is a rare malignant soft tissue tumour with high rate of recurrence and metastasis. Diagnosis may be delayed due to its benign appearance in presentation in the initial stage of the disease. Tissue diagnosis with immunohistochemical typing remains the diagnostic investigation of choice. Treatment includes surgical resection combined with radiotherapy and adjuvant chemotherapy.

*Funding: No funding sources*

*Conflict of interest: None declared*

*Ethical approval: Not required*

### **REFERENCES**

1. Kumar V, Abbas AK, Aster JC. Bones, joints and soft tissue tumors. Robbins Basic Pathology. 9th ed. Philadelphia: Elsevier Saunders; 2013: 792.
2. Enzinger FM. Epithelioid sarcoma- a sarcoma simulating granuloma or carcinoma. Am Cancer Societ. 1970;26(5):1025-41.
3. Goldblum JR, Folpe AL, Weiss SW. Malignant soft tissue tumors of uncertain type. Enzinger and Weiss's Soft tissue Tumors. 6th ed. Philadelphia: Elsevier Saunders; 2014: 1086-1098.

4. Noujaim J, Thway K, Bajwa Z, Bajwa A, Maki RG, Jones RL, et al. Epithelioid sarcoma: opportunities for biology driven targeted therapy. *Front Oncol.* 2015;5:186.
5. dos Santos LM, Nogueira L, Matsuo CY, Talhari C, Santos M. Proximal-type epithelioid sarcoma- case report. *Bras Dermatol.* 2013;88(3):444-7.
6. Chibani L, Guillou L, Teuier P, Decoruvelaere AV, Gregoire F, Jose M, et al. Epithelioid sarcoma- a clinicopathologic and immunohistochemical analysis of 106 cases from the french sarcoma group. *Am J Clin Pathol.* 2009;131:222-7.
7. Horseinzadah P, Cheung F. Epithelioid sarcoma. *Electronic sarcoma update newsletter.* 2009;6(6).
8. Jawad MU, Extein J, Min ES, Scully SP. Prognostic factors for survival in patients with epithelioid sarcoma: 441 cases from SEER database. *Clin Orthopaedics Related Res.* 2009;467:2939-48.
9. Guzzetta AA, Montgomery EA, Lyu H, Hooku CM, Meyer CF, Loeb DM, et al. Epithelioid sarcoma: one institution's experience with a rare sarcoma. *J Surgery Res.* 2012;177(1):116-22.
10. Sobanko JF, Meijer L, Nigra TP. Epithelioid sarcoma- a review and update. *J Clin Aesthet Dermatol.* 2009;2(5):49-54.
11. Sakharpe A, Lahat G, Gulamhusein T, Liu P, Bolshakov S, Nguyen T, et al. epithelioid sarcoma and unclassified sarcoma with epithelioid features : clinicopathological variables, molecular markers and a new experimental model. *Oncologist.* 2011;16(4):512-22.
12. Nishibaba, Higashi Y, Goto Y, Hisaoka M, Kanekura T. Epithelioid sarcoma with multiple lesions on left arm: a case report. *J Med Case Report.* 2016;10:295.
13. Callister MD, Ballo MT, Pisters PWT, Patel SR, Feig BW, Pollock RE, et al. Epithelioid sarcoma: results of conservative surgery and radiotherapy. *Int J Radiat Oncol-Biol-Physics.* 2001;51(2):384-91.

**Cite this article as:** Khandalkar S, Ghatnekar A, Tonape T, Srilikhitha K, Patil KA, Ranka M, et al. A rare case of shoulder swelling: epithelioid sarcoma- case report. *Int Surg J* 2019;6:3845-8.