

Case Report

Actinomycosis of the abdomen mimicking acute appendicitis

David Molina Davila^{1*}, Francisco Terrazas Espitia¹, Alejandro Corona Figueroa¹,
Jose Donis Hernandez², Jimena Gonzalez Cal Y. Mayor³

¹Department of Digestive Surgery, ²Department of Infectology, ³Department of General Medicine, Hospital Espanol, Mexico

Received: 23 July 2019

Accepted: 06 September 2019

*Correspondence:

Dr. David Molina Davila,

E-mail: david.molina.davila.md@gmail.com

Copyright: © the author(s), publisher and licensee Medip Academy. This is an open-access article distributed under the terms of the Creative Commons Attribution Non-Commercial License, which permits unrestricted non-commercial use, distribution, and reproduction in any medium, provided the original work is properly cited.

ABSTRACT

Bacteria of the genus *Actinomyces* are non-spore-forming filamentous, *Microaerophilic* or strict anaerobic, Gram-positive bacilli, mainly belonging to the human commensal flora of the oropharynx, gastrointestinal tract, and urogenital tract; *Actinomycosis israelii* is most frequently isolated in human infection by this bacteria (90% of the cases), and is a very rare, generally a polymicrobial granulomatous infection which affects the cervicofacial (55% of all cases), abdominopelvic (22%) and thoracic (15%) regions, causing formation of abscesses, woody fibrosis and sinus discharge of characteristic sulfur granules. We present the case of a 42 year old patient with no prior medical history who presented to the emergency room with acute onset abdominal pain in the lower right quadrant, leukocytosis and neutrophilia, as well as ultrasonographic images which suggested acute appendicitis, the patient underwent laparoscopic appendectomy and cultures of abscesses surrounding the appendix were positive for *A. israelii*, which was also isolated in the histopathological specimen. The patient underwent antimicrobial treatment with ampicillin-sulbactam for a three month period postoperatively.

Keywords: Actinomycosis, Acute abdomen, Appendicitis, Laparoscopy

INTRODUCTION

Bacteria of the genus *Actinomyces* belong to the Actinobacteria phylum and Actinomycetales order and are non-spore-forming filamentous, *Microaerophilic* or strict anaerobic, Gram-positive bacilli, mainly belonging to the human commensal flora of the oropharynx, gastrointestinal tract, and urogenital tract; these bacteria are related to other genera such as *Corynebacterium*, *Mycobacterium*, *Nocardia*, and *Propionibacterium*. There are more than 30 species of *Actinomyces*, *Actinomyces israelii* being the most frequently isolated species in human infections. Actinomycosis infection presents a wide spectrum of clinical features, depending on the anatomical site affected (mainly respiratory tract, genitourinary tract, digestive tract, central nervous

system, bones and joints). It frequently mimics other diseases such as tuberculosis, nocardiosis or cancer.¹

Diagnosis and bacteriological identification of *Actinomyces* is challenging given a high failure rate of culture due to previous antibiotic therapy, inhibition of *Actinomyces* growth by concomitant and/or contaminant microorganisms, inadequate culture conditions or inadequate short-term incubation. The most appropriate clinical specimens are tissue from surgical biopsy or pus indicating suspicion for actinomycosis to the microbiologist in order to ensure prolonged culture on appropriate media.² Gram staining of pus and pathology of infected tissue is usually more sensitive than culture, *Actinomyces* spp invaded tissues, develop a chronic granulomatous infection characterized by the formation of sulfur granules, which are formations of 0.1-1 mm in

diameter, composed of an internal tangle of mycelial fragments and a rosette of peripheral clubs.³

Abdominal actinomycosis represents only up to 20% of all cases of Actinomycosis Spp infection, and though it has been widely acknowledged for over 100 years, it still remains underdiagnosed by most physicians, who mistake it for local inflammatory or malignant pathologies.

CASE REPORT

We present the case of a 42 year old female patient, with no prior history of chronic degenerative diseases, who presented to the emergency room with acute, generalized abdominal pain, which irradiated to the right iliac fossa, which was exacerbated by movement and was accompanied by nausea, anorexia and obstipation, as well as low grade fever (38.0°F).

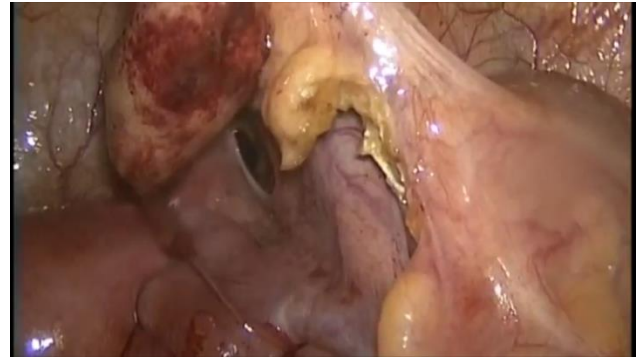

Figure 3: Intraoperative image of the swollen appendix, which presented with surrounding free purulent liquid on initial laparoscopy, which was collected and sent for microbiological study.

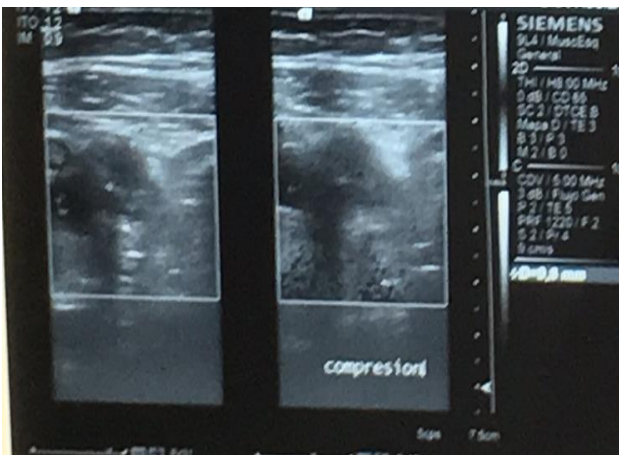


Figure 1: Pelvic ultrasonography that shows no changes on appendicular diameter upon compression, suggesting appendicitis.

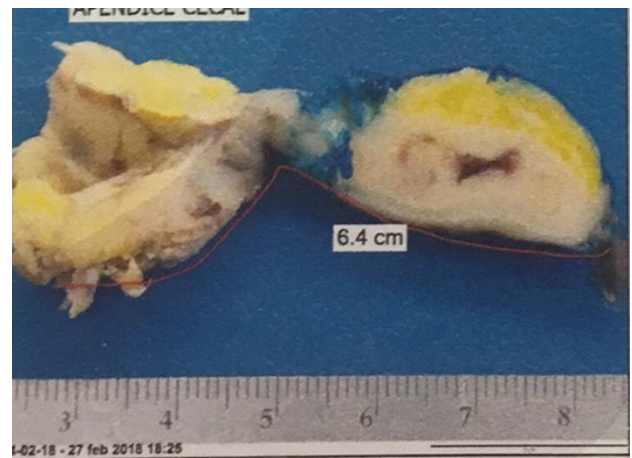


Figure 4: Specimen sent postoperatively for histopathological study.

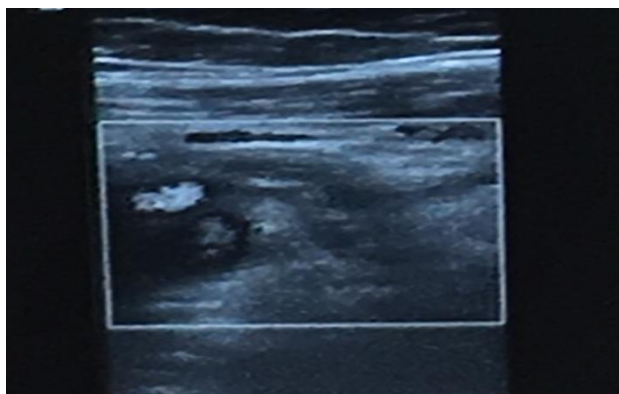


Figure 2: Preoperative pelvic ultrasonography which periappendiceal fat straining and free fluid, as well as enlargement of the appendiceal diameter.

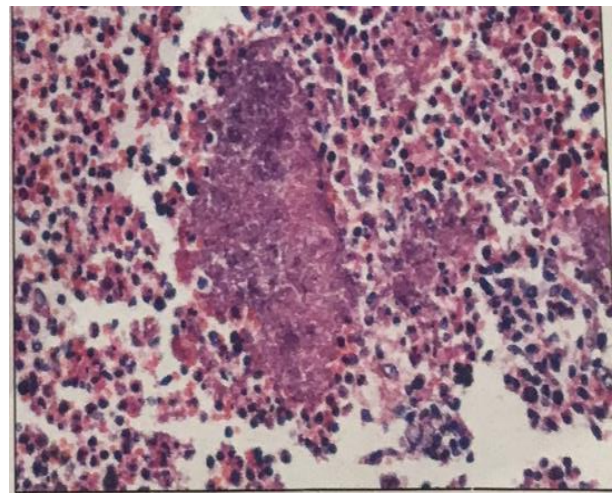


Figure 5: Histopathology slide of the appendix showing characteristic chronic granulomatous reaction and “sulfur granules” caused by Actinomyces species infection.

On admission to the emergency department, the patient presented vital signs within normality, being conscious, alert, neurologically intact, with discomfort related to dorsal decubitus. Abdominal examination highlighted the presence of a tense abdomen, painful upon deep palpation, with apparent peritoneal irritation at the time of admittance. Pain increased upon deep palpation of the lower right abdominal quadrant with rebound tenderness, Mc Burney's and Blumberg's sign was present. Generalized ileus was noted upon abdominal auscultation.

Admission laboratory testing showed hemoglobin of 12.8 g/dl, with leukocytes reported at 13 mil / mm³, neutrophil bands of 7%, glucose of 83, without evidence of biochemical alterations in blood count or blood chemistry. The emergency service requested assessment by the general surgery service, requesting complementary imaging studies.

A simple abdominal radiography reported the presence of segmental ileus predominantly in the right iliac fossa, right psoas was reported as unidentifiable on the right iliac fossa, which suggested local inflammatory process. An ultrasound reported no alterations in the uterus, endometrium, or ovaries, free fluid was observed in the right iliac fossa, surrounding the appendix, as well as periappendicular fat stranding and abnormally thickened appendix, all of which suggested acute appendicitis.

The patient was admitted to the general surgery ward and scheduled to undergo laparoscopic appendectomy. One 12 mm trocar was placed under direct vision in the umbilicus, two 5 mm trocars were placed in the left iliac fossa and the hypogastrium. Laparoscopy revealed free fluid in the abdominal cavity surrounding the appendix, which appeared swollen and erythematous and surrounded by fibrin. The mesoappendix was identified and haemostasis was performed using a harmonic ACE scalpel. Once vascular control was achieved, 2 endoloops were used proximal and one distal to the caecum, the appendix was then removed with laparoscopic scissors, extracted from the abdominal cavity with a sterile specimen container, and sent to pathology for histopathological analysis. We then proceeded with careful inspection of all quadrants of the abdomen without any further pathologic findings.

The patient had an adequate postoperative recovery, and was started on oral liquids 12 hours after surgery, she was progressed to a bland diet 6 hours after tolerating liquids and was discharged 36 hours after the surgical procedure. She was discharged with a prescription for oral antibiotics (cefuroxim), and analgesics. The patient referred continuous abdominal discomfort, which she referred to as being sporadic, with acute exacerbation and starting in the right iliac fossa, without any irradiation, worsening in the subsequent 4 days in spite of analgesics. She was once again admitted to the emergency department where she underwent laboratory testing and

an abdominal CT-scan to rule out residual abscess. The laboratory findings and abdominal CT-scan were reported to be normal, so analgesics were modified with an adequate response. Upon re-admission we received the histopathological analysis of the appendix, which revealed acute appendicitis affecting the serosa and muscular layers, with surrounding nodule formation as well as bacterial Gram + bacterial colonies, which were compatible with *Actinomyces* Sp. therefore the infectology department was consulted, and antimicrobial therapy was modified, starting her on ampicillin/sulbactam intravenously. The patient remained under observation for 4 days, without any pain or fever, with an adequate tolerance for bland diet, without presenting any other symptoms, therefore, the infectology department agreed on her discharge, prescribing a 3 month antibiotic therapy with ampicillin-sulbactam and continuing medical observation during this period.

The patient remained asymptomatic and an abdominal CT-scan and laboratory testing was performed upon finishing antimicrobial therapy prescribed by the infectology department. No abnormal findings were reported in either.

DISCUSSION

Actinomycosis is a rare infectious disease caused mainly by *Actinomyces* spp. (90% of the cases are caused by *A. israeli*) a gram-positive, branching and slow growing, Microaerophilic, or obligatory anaerobic bacteria, which until recently was considered to be a fungal organism; it is a form of granulomatous infection of the cervicofacial (55% of all cases), abdominopelvic (22%) and thoracic (15%) regions, which causes tissular invasion and is characterized by the formation of abscesses, woody fibrosis and sinus discharge of characteristic sulfur granules.⁴

Actinomyces is a normal commensal of the oral cavity, gastrointestinal and urogenital tracts, but it can become pathogenic when mucosal barriers are breached. Actinomycosis is generally a polymicrobial infection, which is generally accompanied by as many as 5-10 bacterial species. For human infection to occur, it requires the presence of such companion bacteria to accomplish infection by elaborating a toxin or enzyme or by inhibiting host defenses. Oro-cervical infection is the most frequent form of presentation; the appendix and the ileocecal region seem to be most commonly involved in the abdomen. Actinomycosis is most common in middle aged male patients. It has been shown that history of recent abdominal surgery, bowel perforation, cancer, poor oral hygiene and dental procedures as well as intrauterine contraceptive devices can predispose to *Actinomyces* invasion, due to mucosal disruption, which can manifest several weeks or months after the initial insult.⁵

Preoperative diagnosis of abdominal *Actinomyces* is difficult due to its infrequent and unspecific presentation, an exhaustive clinical history regarding recent abdominopelvic or dental procedures as well as history of intrauterine device usage may orient the physician in interpreting imaging studies and laboratory findings, oncological pathologies, as well as inflammatory bowel disease should also be ruled out as a differential diagnosis. Radiologic and ultrasonographic findings are unspecific, which make CT scan of the abdomen the most valuable preoperative diagnostic imaging study. Common CT scan findings in actinomycosis involving the bowel are concentric wall thickening, which may be accompanied by a cystic or solid mass in the vicinity of the affected bowel segment. This mass is usually surrounded by inflammatory infiltrations. Given the presence of fibrosis, it is common to observe strong enhancement after contrast material administration.⁶

Surgical management of abdominal actinomycosis and particularly appendiceal or ileocecal actinomycosis is valuable as a therapeutic adjunct, allowing for debridement of necrotic tissue, extensive lavage of regional abscesses and drainage of inflammatory surrounding liquid. It also allows the surgeon to perform biopsy and to acquire tissue for histopathological and microbiological study. Inflammatory reaction in actinomycosis is suppurative, with formation of abscesses that contain one or more granules (organized aggregates of filaments), 30-3000 micrometer in diameter that are bordered by eosinophilic club like Splendore-Hoeppli material.⁷

CONCLUSION

Abdominal actinomycosis is a rare entity which should be part of the surgeons differential diagnosis on patients with a previous history of recent abdominal surgery, bowel perforation, cancer, poor oral hygiene and dental procedures as well as intrauterine contraceptive devices that present with abdominal pain resembling acute appendicitis; if suspected on laparoscopic exploration, cultures and biopsies should be obtained to rule out this

diagnosis and consult the infectology department for long term antimicrobial management and prevention of recurrence or further complications.

Funding: No funding sources

Conflict of interest: None declared

Ethical approval: Not required

REFERENCES

1. Ferry T, Valour F, Karsenty J, Breton P, Gleizal A, Braun E, et al. Actinomycosis: etiology, clinical features, diagnosis, treatment, and management. *Inf Drug Res.* 2014;7:183-97.
2. Moniruddin, ABM. Begum, H. Nahar, K. Actinomycosis: an update. *Medicine today.* 2010;22(1):43-7.
3. Veenakumari L, Sridevi C. Actinomycosis in histopathology - Review of literature. *IAIM.* 2017;4(9):195-206.
4. Sudhakar SS, Ross J. Short term treatment of actinomycosis: two cases and a review. *Clin Infect Dis.* 2004;38:444-7.
5. Liu K, Joseph D, Lai K, Kench J, Ngu M. Abdominal actinomycosis presenting as appendicitis: two case reports and review. *J Surg Case Reports.* 2016;2016(5):rjw068.
6. Suk Hee Heo, Sang Soo Shin, Jin Woong Kim, Hyo Soon Lim, Hyun Ju Seon, Sook-In Jung, et.al. Imaging of actinomycosis in various organs: a comprehensive review. *Radiographics.* 2014;34:19-33.
7. Liu V, Val S, Kang K, Velcek F. Case report: actinomycosis of the appendix—an unusual cause of acute appendicitis in children. *J Pediatr Surg.* 2010;45(10):2050-2.

Cite this article as: Davila DM, Espitia FT, Figueroa AC, Hernandez JD, Mayor JGCY. Actinomycosis of the abdomen mimicking acute appendicitis. *Int Surg J* 2019;6:3822-5.