

## Original Research Article

# Laparoscopic management of non-palpable un-descended testes: our experience

Zahid M. Rather<sup>1\*</sup>, Nighat Ara Majid<sup>2</sup>, Raja Waseem M.<sup>3</sup>, M. Nazrull Islam<sup>1</sup>

<sup>1</sup>Department of Surgery, <sup>2</sup>Department Gynaecology and Obstetrics, <sup>3</sup>Department of Radiology, Govt. Medical College Srinagar, Jammu and Kashmir, India

**Received:** 15 May 2019

**Revised:** 15 July 2019

**Accepted:** 29 July 2019

**\*Correspondence:**

Dr. Zahid M. Rather,

E-mail: [drzahidmrather@yahoo.com](mailto:drzahidmrather@yahoo.com)

**Copyright:** © the author(s), publisher and licensee Medip Academy. This is an open-access article distributed under the terms of the Creative Commons Attribution Non-Commercial License, which permits unrestricted non-commercial use, distribution, and reproduction in any medium, provided the original work is properly cited.

## ABSTRACT

**Background:** The purpose of the study was to determine the sensitivity and specificity of laparoscopy in localizing non-palpable testes, its therapeutic role, mean operative time, conversion rate, complications and hospital stay.

**Methods:** A total of 52 patients were included in the study and was conducted from June 2012 to June 2017. These boys were examined as outpatients, at the time of admission and after general anesthesia to exclude palpable testes and were subjected to diagnostic and operative laparoscopy.

**Results:** We identified 52 patients with 66 non palpable un-descended testes. The most common age of presentation was 1-4 years. Majority of patients i.e. 27 were on the left side. Ultra-sound identified testis >2 cm from deep inguinal ring in 20, near deep ring <2 cm in 20 and at inguinal canal in 6 patients. In the diagnostic laparoscopy, high intra-abdominal testis found in 34, low intra-abdominal testis in 24, blind ending of vas and vessels in 2 patients. The operative procedures performed are diagnostic laparoscopy, laparoscopic orchidopexy, laparoscopic orchidectomy, conversion to open orchidopexy and open orchidectomy. The mean operative time was 53.67±2.37 for unilateral and 102.76±5.38 for bilateral cases. The postoperative complications include surgical emphysema, wound infection and scrotal haematoma. The mean hospital stay was 14.23±2.37 hours for unilateral and 16.27±5.38 hours for bilateral.

**Conclusions:** Laparoscopic orchidopexy appears to be a feasible, minimally invasive, less postoperative pain and trauma, faster convalesce and return to normal activity and an effective technique for the management of low intra-abdominal testes.

**Keywords:** Un-descended testis, Laparoscopy, Orchidopexy

## INTRODUCTION

The definition of cryptorchidism is that a testicle is not within the scrotum and cannot be manipulated into the scrotum.<sup>1</sup> In contrast, an ectopic testis descends normally through the external inguinal ring but is diverted to an aberrant position.<sup>2</sup> The incidence of cryptorchidism is 3% in full term neonates, rising to 30% in premature boys.<sup>3</sup> During the first months of life, testis may continue their normal descent process. Cryptorchidism occurs in 1–2%

by 3-month of age, and decreases to 0.8–1.2% in boys at 1-year-old.<sup>3-5</sup> The condition of non-palpable testis may fall into one of the following categories: agenesis, vanishing tests, intra-abdominal testes or inguinal testes.<sup>6</sup> Reasons for treatment of cryptorchidism are increased infertility, testicular malignancy, testicular torsion, trauma and psychological stigma of an empty scrotum to the patient and their parents.<sup>7</sup> The incidence of carcinoma in situ is determined to be 1.7% among patients with undescended testes.<sup>8</sup> Therefore, early diagnosis and

treatment of undescended testis are needed to preserve fertility and to prevent testicular malignancy.<sup>9</sup> The surgical management for nonpalpable testes is diagnostic laparoscopy.<sup>10</sup> The evidence shows that radiologic studies to localize the testis are of very little value, with sensitivity and specificity of approximately 45% and 78%, respectively.<sup>11-13</sup> In experienced hands, laparoscopy is capable of providing 100% accuracy in the diagnosis of the intra-abdominal testis with minimal morbidity. With the advancements in laparoscopic techniques and instruments, laparoscopic orchidopexy has become standard procedure in the management of non-palpable un-descended testes.

### Objectives

The purpose of the study was to assess and observe the following parameters.

The sensitivity and specificity of laparoscopy in localizing non-palpable testes, to evaluate the therapeutic role of laparoscopy in non-palpable testes, mean operative time, conversion rate, postoperative complications (wound infection, Intra-abdominal abscess), hospital stay.

### METHODS

The study was conducted from June 2012 to June 2017. A total of 52 patients were included in the study. It was a prospective, observational study. A written, informed consent was obtained from all participants and ethical clearance was granted by our college ethical committee. All patients who presented to the outpatient department with complaints of absent testes were examined and boys with non-palpable testes were included in the study. Patients with non-palpable testes were subjected to diagnostic and operative laparoscopy. These boys were examined as outpatients, at the time of admission and after general anesthesia to exclude palpable testes. All patients were followed up for a period of 1 year post operatively. The data was collected prospectively including age, diagnostic laparoscopy finding, duration of surgery, complications and hospital stay. All the patients enrolled for the study were evaluated by detailed history, thorough general physical examination and focused systemic examination. Informed consent was taken before surgery. All patients received a prophylactic dose of injection ceftriaxone 15-20 mg/kg one hour before the surgery.

### Operative technique

All procedures were done under general anesthesia and caudal block. Inguinal examination was performed in each child under anesthesia to confirm the preoperative diagnosis. Children were premedicated with syrup promethazine (phenegan) 0.4 mg/kg given 2 hours before shifting to operation theatre.

### Diagnostic laparoscopy

Two commonly used techniques are either an open or closed approach. We prefer to use a closed technique of a Veress needle through the umbilicus followed by the dilation of the tract using a step system to allow for placement of a 2-3 mm to 5 mm trocar through the umbilicus depending upon the size of patients; generally a zero-degree lens was used. Pneumoperitoneum is achieved with carbon dioxide at a flow rate of 1 l/min (depending on the size of the child) at a maximum pressure of 15 mmHg; the pelvis is evaluated using a 0° 2.8 mm lens. The area of the internal inguinal ring was inspected bilaterally and subsequent trocars were placed under laparoscopic visualization into the right and left lumbar region in line with the umbilical port. Subsequent surgery was planned according to the laparoscopic findings.

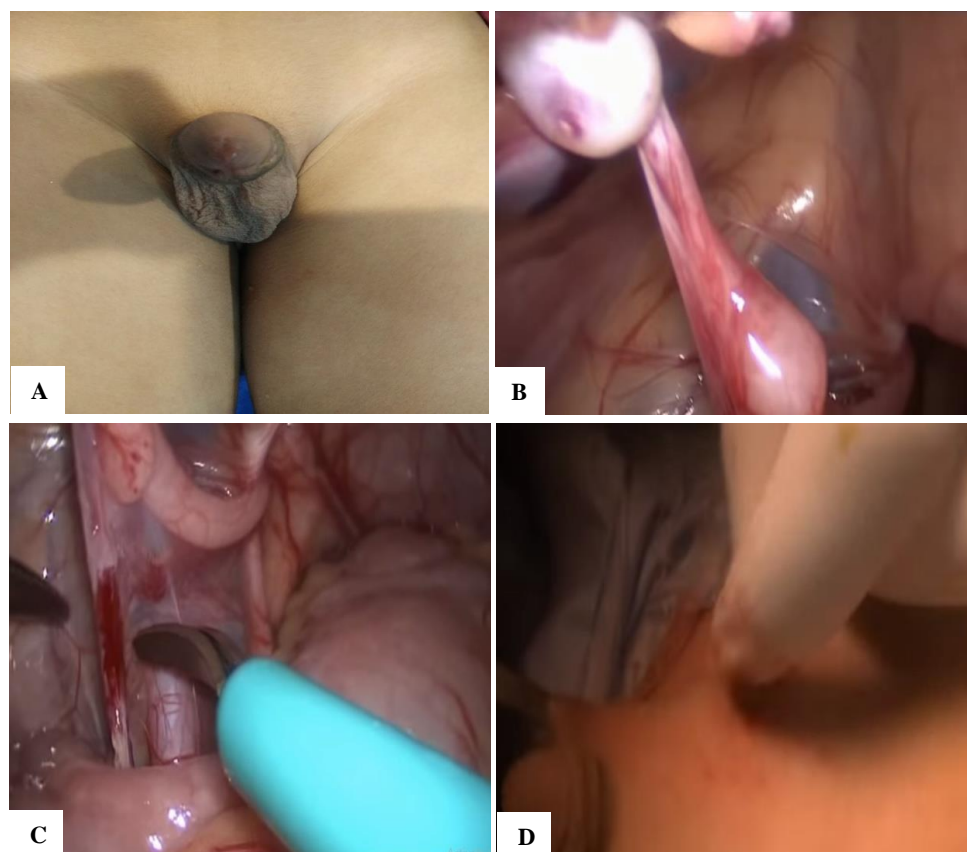
A diagnostic laparoscopy was done for rest of the abdominal quadrants in all cases. Inguinal ring was first examined to evaluate its patency, and then the iliac areas and pelvis were inspected. If intra-abdominal blind ending cord structures were found, no further exploration was performed and a diagnosis of intra-abdominal vanishing testes was made.

If an intra-abdominal testis was found it was classified as high and low depending on its position to the internal ring. High i.e. in the iliac fossa or pelvic inlet or pelvis (>2 cm from the internal ring), low i.e. adjacent to the internal ring/emergent testis (<2 cm from the internal ring). With gentle traction on the testis, the most distal gubernacular attachment was divided with electric hook cautery and gubernaculum forming a handle for mobilizing the testis. Stretch maneuver was performed to see the mobility of the testis. Dissection was started lateral to the spermatic vessels and continued in cephalad direction over the iliac vessels. Once the testis has been adequately mobilized which was confirmed by performing stretch maneuver where the testis is stretched to the contralateral inguinal ring. The dissection was further carried out medially all around the ring to complete the herniotomy. Peritoneal coverage between the vas deferens and urinary bladder was dissected. A triangular area of peritoneum between vas deferens and testicular vessels was left intact to preserve blood supply of testis. The pathway to the ipsilateral hemiscrotum was created. Usually a neotunnel was created between the medial umbilical ligament and the inferior epigastric artery (Prentiss maneuver) to gain extra length for reaching the scrotum.

A blunt tip of the laparoscopic dissector was passed over the pubic bone into the ipsilateral hemiscrotum thus creating a pathway. A dartos pouch was prepared in the hemiscrotum. A suction cannula was passed along the passage which was created transabdominally by laparoscopic dissector and grasping the tip of the suction cannula a long curved clamp was passed into the abdominal cavity and stretched in all directions to create

adequate passage for bringing the testes down. The testis was grasped; ensuring that only gubernacular tissue is grasped. The testes were brought out into the scrotum and the length checked by deflating the abdomen. Releasing the pneumoperitoneum gave additional length. Any tension found on the pedicle was released by further mobilization of the peritoneal flaps. Testes were fixed in scrotum using 5-0 chromic catgut suture. Testes with a

long mesoorchium were found to have more mobility and were mobilized easily compared to testes which were attached to the retroperitoneum by narrow stalk or embedded in the retroperitoneum. At the end of the procedure, abdomen was examined for any bleeding, the pneumoperitoneum was released, trocars were removed. Trocar sites were closed. Children were discharged home next day.



**Figure 1: (A) Preoperative photograph showing right side un-descended testes, (B) intra-operative photograph showing intra-abdominal testes, (C) intra-operative photograph showing release of adhesions, (D) intra-operative showing orchidopexy on right side.**

### **Postoperative care**

Orals were started as soon as the patients started to tolerate them. A second dose of intravenous antibiotics (Ceftriaxone 15-20 mg per kg IV) was given 12 hours after surgery. Analgesics were given on demand only. Monitoring of the patient for Pulse, Temperature, Respiratory rate, urine output, and appearance of bowel sounds and passage of flatus was done. The patients were typically discharged home on 1st or 2<sup>nd</sup> postoperative day. Patients were followed in the OPD at 1 week; 4 weeks and 6 months and 1 year to check the relapse or recurrence and atrophy of testis.

### **RESULTS**

This prospective study was conducted from June 2012 to June 2017. Patients with non-palpable testes were

subjected to diagnostic and operative laparoscopy. 52 patients were included in the study; in which total 66 procedures were performed (14 patients were undergone bilateral orchidopexy). The age of the patients ranged from 01 to 25 years and most common age of presentation was 1-4 years (Table 1). Majority of patients presented with un-descended testis i.e. 27 (40.90%) were on the left side, 11 (16.66%) on the right and remaining 14 (42.42%) were bilateral. Ultra-sound identified testis >2 cm from deep inguinal ring in 20 (30.30%), near deep ring <2 cm in 20 (30.30%) and at inguinal canal in 6 (9%) and at superficial inguinal ring in 6 (9%) and testis not localized in 14 (21.21%) patients (Table 1). Following findings were observed in the diagnostic laparoscopy, high intra-abdominal testis in 34 (51.51%), low intra-abdominal testis in 24 (36.36%), blind ending of vas and vessels in 2 (3%) and vas and vessels entering deep ring 6 (9%). The operative procedures performed

are diagnostic laparoscopy in 2 (3%), laparoscopic orchidopexy in 48 (72.72%), laparoscopic orchidectomy in 10 (15.15%), conversion to open orchidopexy 4 (6%), open orchidectomy in 2 (3%). The mean operative time was  $53.67 \pm 2.37$  for unilateral and  $102.76 \pm 5.38$  for bilateral cases. There was no major life threatening

complication of surgery. The postoperative complications include surgical emphysema 2 (3%), wound infection 1 (1.5%) and scrotal haematoma 1 (1.5%). The mean hospital stay was  $14.23 \pm 2.37$  hours for unilateral and  $16.27 \pm 5.38$  hours for bilateral.

**Table 1: Demographic data of patients.**

	Number of patients	Percentage (%)
<b>Age in years</b>		
1-4	22	42
5-8	20	38.4
9-12	4	7.6
13-16	2	3.8
$\geq 16$	4	7.6
<b>Side Distribution</b>		
Right side	11	16.66
Left side	27	40.90
Bilateral	28	42.42
<b>Ultrasound Localization</b>		
Testis away from deep ring > 2 cm	20	30.30
Testis near deep ring < 2 cm	20	30.30
Testis localized in inguinal canal	6	9
Testis at superficial inguinal ring	6	9
Testis not localized	14	21.21

**Table 2: Diagnostic laparoscopy.**

Findings	Number (%)	Morphology	Number	Percentage (%)
<b>High intra-abdominal testis</b>	34 (51.51)	Normal	8	12.12
		Hypoplastic	20	30.30
		Atropic	6	9
<b>Low intra- abdominal testis</b>	24 (36.36)	Normal	22	33.33
		Hypoplastic	2	3
		Atropic	0	0
<b>Blind ending of vas and vessels</b>	2 (3)	No testis found	2	3
<b>Vas and vessels entering deep ring</b>	6 (9)	Normal testis	6	9

**Table 3: Operative procedures performed.**

Operative procedure	Number	Percentage (%)
<b>Diagnostic laparoscopy</b>	2	3
<b>Laparoscopic orchidopexy</b>	48	72.72
<b>Laparoscopic orchidectomy</b>	10	15.15
<b>Conversion to open orchidopexy</b>	4	6
<b>Open orchidectomy</b>	2	3

**Table 4: Intra operative and postoperative data.**

		Mean $\pm$ SD
<b>Mean operative time</b>	Unilateral 19	$53.67 \pm 2.37$
	Bilateral 14	$102.76 \pm 5.38$
<b>Postoperative stay</b>	Unilateral 19	$14.23 \pm 2.37$
	Bilateral 14	$16.27 \pm 5.38$

Continued.



		Mean±SD
Postoperative complications		
Surgical emphysema	2	3
Wound infection	1	1.5
Sacrotal haematoma	1	1.5
Intra-abdominal abscess	0	0

## DISCUSSION

The aim of surgical management of the UDT in young boys is to preserve spermatogenesis and allow for screening and detection of any malignant transformation by performing an early orchidopexy.<sup>14,15</sup> Approximately 80% of UDT are palpable, and they are managed by an orchiopey performed through a small inguinal incision. Non-palpable testes, on the other hand, represent a diagnostic and therapeutic challenge.

Although numerous strategies exist for the treatment of boys with non-palpable testes, controversy remains concerning the most effective treatment. Traditionally, an open inguinal exploration was undertaken to locate the missing testis, followed by a conventional orchidopexy or orchiectomy.

The current initial surgical procedure of choice for the non-palpable UDT is a diagnostic laparoscopy.<sup>16</sup> The findings on laparoscopy dictate the next step of management; either a one- or two-stage laparoscopic assisted orchiopey, a laparoscopic orchiectomy or an inguinal exploration if the vas deferens and spermatic vessels pass through the internal ring into the inguinal canal. None of the imaging techniques USG, CT, MRI has proved 100% reliable in predicting presence or absence of the testis. Comparative study between USG, MRI and laparoscopy recommended laparoscopic evaluation as the preferable method in cases of non-palpable testes, as leaving a probable atrophic or viable intra-abdominal testes missed by these investigation may expose the child to the risk of future malignancy. In our study, USG was accurate in 42% of the patients for localizing the testes and thus is unnecessary in boys with non-palpable testis because it rarely localizes a true non-palpable testes and it does not alter the surgical approach in the patients. It is however useful for picking up other intra-abdominal anomalies.

Diagnostic laparoscopy and laparoscopic orchidopexy has begun to surpass surgical exploration as the primary treatment in boys with non-palpable testis, gaining wide acceptance in the surgery community as the most effective means of relocating an intra-abdominal testes to a dependent position. Our study showed that patients with intra-abdominal testis and intra-abdominal blind ending cord structures benefited from laparoscopy from the fact that this technique provided them with a definitive diagnosis, direct surgical approach according to the location of testes and avoidance of unnecessary abdominal exploration in cases of vanishing testis.

Laparoscopy is widely and safely used by urologists, however, it carries some risks, especially in children given their size and the limited workspace in the peritoneum, as well as additional costs for the health care system. Vascular, bowel, and solid organ injuries are among the possible complications seen with laparoscopy.<sup>17-19</sup> We took a study with 52 patients diagnosed clinically as un-descended, non-palpable testis and subjected all of them to the diagnostic laparoscopy and proceed. Out of 52 patients 14 patients were operated on both sides in the same sitting (bilateral orchidopexy). In our study patients were in the age range of 1 to 18 years and majority was in the age group of 1-4 years.<sup>20,21</sup> Our study reports a majority of un-descended non-palpable testis noticed on the left side (40.90%) and 16.66% on right side and rest were bilateral (42.42%).<sup>22</sup> The incidence of bilateral un-descended testis was relatively higher as compared to other studies because our centre is main referral unit for laparoscopy and our patients presented early as compared to other studies. Secondly percentage of bilateral non-palpable testis is higher in younger age group. In our study all patients have undergone ultrasound preoperatively and shows localization of testis in 78.78%, and majority of patients have high intra abdominally testis >2 cm from inguinal ring (51.51%) followed by low intra-abdominal testis < 2 cm from inguinal ring (36.36%). Ultrasound was not found to be useful in identifying intra-abdominal testes.<sup>23</sup> A prospective study used high-resolution ultrasound to examine 40 boys with 52 UDTs, comparing the findings to those at surgical exploration. Up to 91% of palpable and 87% of non-palpable testes were identified, with an overall sensitivity of 90%, specificity 33%, positive predictive value 96% and negative predictive value 17%.<sup>24</sup>

Diagnostic laparoscopy was done in all the patients and relation of testis to deep inguinal ring was noted. Simultaneously relationship of vas and spermatic vessels was determined. The overall success of laparoscopy as a diagnostic tool about non-palpable testis was 100%. Vanishing testes was found in 3% of cases which had advantage of avoiding unnecessary groin exploration and 96.9% cases the morphology of testes was determined and so diagnostic followed by therapeutic benefit of laparoscopy was 96.9%.<sup>22,25</sup> Morphology of testis was correlated with localization of testis which revealed that features of hypoplasia were high in intra-abdominal testis. Our study revealed normal testis in 54.54% of cases. Next common finding was hypoplastic testis (33.33%). This is unison with the study conducted by Boekmann and Humphery.<sup>26,27</sup> The various modalities of

intervention included diagnostic laparoscopy for all patients and further management was dictated by presence/ morphology of testis. Orchidopexy was done in 54 (81.81%) non-palpable testis laparoscopic orchidopexy was done in 48 (72.72%) and conversion to open orchidopexy was 4 (6%).<sup>22,28,29</sup> The reasons for conversion were dense adhesions of testis with surrounding structures. Orchiectomy was done 12 (18.18%), laparoscopic orchiectomy in 10 and open orchiectomy in 2 patients. Reasons for orchiectomy were that 6 testes were atrophic and 6 testes were hypoplastic and could not be mobilized adequately as determined by stretch test.<sup>25,30</sup> The reason for high success as compared to other studies was that in our study 87.87% testis were located at intra-abdominal or intracanalicular, only 2 (3%) of patients have vanishing testis.<sup>20,31</sup> The mean operative time was more in earlier cases and decreased gradually as we mastered the technique. Mean operative time for unilateral undescended was  $53.67 \pm 2.37$  minutes and for bilateral undescended the duration was longer; mean  $102.76 \pm 5.38$  minutes.<sup>32,33</sup> In our study there was no major life threatening complication. The post-operative complications were to the tune of 4 (6%), which includes surgical emphysema in 2 (3%), wound infection 1 (1.5%) and scrotal haematoma 1 (1.5%). None of patients in our study have developed intra-abdominal abscess or testicular atrophy.<sup>25,34</sup> The complication rate in our study was lower as compared to other studies, which can be explained on the basis that all the procedures were done by a single skilled laparoscopic surgeon. The mean hospital stay in our patients was  $14.23 \pm 2.37$  hours for unilateral cases and  $16.27 \pm 5.38$  hours for bilateral cases.

## CONCLUSION

We concluded that imaging modalities like USG, CT and MRI has limited role in the diagnosis of non-palpable undescended testes. If testes is examined bimanually under anesthesia is still non-palpable, diagnostic laparoscopy should be used to identify its size, location, and structure and therapeutic as well. Laparoscopic orchidopexy appears to be a feasible, minimally invasive, less post-operative pain and trauma, faster convalesce and return to normal activity with fewer complications and an effective technique for the management of low intra-abdominal testes.

## ACKNOWLEDGEMENTS

We are thankful to our colleagues Dr Rifat, Shamsul Afaq who provided expertise that greatly assisted the research.

*Funding: No funding sources*

*Conflict of interest: None declared*

*Ethical approval: The study was approved by the Institutional Ethics Committee*

## REFERENCES

- Pillai SB, Besner GE. Pediatric testicular problems. *Pediatr Clin North Am.* 1998;45:813-30.
- Rajfer J. Congenital anomalies of the testis and scrotum. In: Walsh PC, Retick AB, Vaughan, editors. *Campbell's urology.* 7th ed. Philadelphia, PA: WB Saunders; 1998: 2172.
- Berkowitz GS, Lapinski RH, Dolgin SE, Gazella JG, Bodian CA, Holzman IR. Prevalence and natural history of cryptorchidism. *Pediatrics* 1993;92:44-9.
- Virtanen HE, Bjerknes R, Cortes D, Jørgensen N, Rajpert-De Meyts E, Thorsson AV, et al. Cryptorchidism: classification, prevalence and long-term consequences. *Acta Paediatr.* 2007;96:611-6.
- Scorer CG. The descent of the testis. *Arch Dis Child.* 1964;39:605-9.
- Koyama T, Nonomura K, Ameda K, Kakizaki H, Yaksuni. Laparoscopic Evaluation and Management of the Nonpalpable Testis. *Diagn Ther Endosc.* 1997;4(2):69-74.
- Chui CH, Jacobson AS. Laparoscopy in the evaluation of the non-palpable undescended testes. *Singapore Med J.* 2008;41(5):206-8.
- Giwerzman A, Bruun E, Frimodt-Møller C, Skakkebaek NE. Prevalence of carcinoma in situ and other histopathological abnormalities in testes of men with a history of cryptorchidism. *J Urol.* 1989;142:998-1001.
- Guo J, Liang Z, Zhang H, Yang C, Pu J, Mei H, et al. Laparoscopic versus open orchiopexy for non-palpable undescended testes in children: a systemic review and meta-analysis. *Pediatr Surg Int.* 2011;27:943-52.
- Esposito C, Caldamone AA, Settini A, El-Ghoneimi A. Management of boys with nonpalpable undescended testis. *Nat Clin Pract Urol.* 2008;5:252-60.
- Elder JS. Laparoscopy for impalpable testes: Significance of the patent processus vaginalis. *J Urol.* 1994;152:776-8.
- Diamond DA, Caldamone AA. The value of laparoscopy for 106 impalpable testes relative to clinical presentation. *J Urol.* 1992;148:632-4.
- Moore RG, Peters CA, Bauer SB, Mandell J, Retik AB. Laparoscopic evaluation of the nonpalpable tests: A prospective assessment of accuracy. *J Urol.* 1994;151:728-31.
- Lee PA, O'Leary LA, Songer NJ, Coughlin MT, Bellinger MF, LaPorte RE. Paternity after bilateral cryptorchidism. A controlled study. *Arch Pediatr Adolesc Med.* 1997;151:260-3.
- Walsh TJ, Dall'Era MA, Croughan MS, Carroll PR, Turek PJ. Prepubertal orchiopexy for cryptorchidism may be associated with lower risk of testicular cancer. *J Urol.* 2007;178:1440-6.
- Tennenbaum SY, Lerner SE, McAleer IM, Packer MG, Scherz HC, Kaplan GW. Preoperative laparoscopic localization of the nonpalpable testis:

- A critical analysis of a 10-year experience. *J Urol.* 1994;151:732-4.
17. Philips PA, Amaral JF. Abdominal access complications in laparoscopic surgery. *J Am Coll Surg.* 2001;192:525-36.
  18. Kirchhoff P, Dincler S, Buchmann P. A multivariate analysis of potential risk factors for intra- and postoperative complications in 1316 elective laparoscopic colorectal procedures. *Ann Surg.* 2008;248:259-65.
  19. Philosophe R. Avoiding complications of laparoscopic surgery. *Fertil Steril.* 2003;80(Suppl 4):30-9.
  20. Ismail K, Ashour M, El-Afifi M, Hashish A. Laparoscopy in the management of impalpable testis. *World J Surg.* 2009;33(7):1514-9.
  21. Satar N, Bayazit Y, Doran S. Laproscopy in management of impalpable testicle. *Acta Chir Belg.* 2005;105(6):662-6.
  22. Zubair M, Javad IM, Saleem M. Role of Laparoscopy in Diagnosis of Non-palpable Undescended Testis. *The Professional.* 1998;4(4):80-1.
  23. Ekenze SO, Nwankwo EP, Okere PC. The utility of ultrasonography in the management of undescended testis in a developing country. *World J Surg.* 2013;37:1121-4.
  24. Adesanya OA, Ademuyiwa AO, Bode CO, Adeyomoye AA. Diagnostic value of high resolution ultrasound in localisation of the undescended testis in children. *Afr J Paediatr Surg.* 2013;10:127-30.
  25. Khan SA, Laghari AA, Abbasi MR, Bhatti S. Laparoscopic assisted- management of impalpable testis in patients older than 10 years. *J Soc Lapro Endoscop Surgeons.* 2010;14(2):251-5.
  26. Humphrey GME. Laparoscopy in the management of the impalpable undescended testes. *Br J Surg.* 1998;7:983-5.
  27. Boeckmann W, Brauers A, Mersdorf A, Rohrmann D, Jakse G. Diagnostic and Therapeutic Laparoscopy of the Non palpable testis. *Scand. J Urol Nephrol.* 1996;30(6):479-84.
  28. Hinyokika N, Zasshi Z. Management of impalpable testis-The value of laparoscopy for subsequent treatment. *BJU.* 1991;82(7):125-32.
  29. Godbole PP, Morecroft JA, Mackinnon AE. Laparoscopy for impalpable testis. *Br J Surg.* 2005;84:1430-2.
  30. Bakr AA, Kotb M. Laparoscopic orchidopexy: The treatment of choice for the impalpable undescended testis. *JSLs.* 1999;2(3):259-63.
  31. Hassan ME, Mustafawi A. Laproscopic management of impalpable testes in children – new classification; lessons learned and rare anomalies. *Laproendosc Adv Surg.* 2010;20(3):265-9.
  32. Mark SD. The role of laparoscopy in evaluation of the impalpable undescended testes. *Aust NZJ Surg.* 1997;67(6):332-4.
  33. Argos RMD, Unda FA, Orpez RA, Lorenzo GC. Diagnostic and therapeutic laparoscopy for nonpalpable testis. *Surg Endoscopy.* 2003;17(11):1756-8.
  34. Lindgren BW, Franco I, Bilick S, Selwyn B, William A, Lane S, Steven C. Laparoscopic Fowler Stephens Orchidopexy for the high abdominal testis. *J Urol.* 1999;162:990-4.

**Cite this article as:** Rather ZM, Majid NA, Raja WM, Islam MN. Laparoscopic management of non-palpable un-descended testes: our experience. *Int Surg J* 2019;6:3188-94.