

## Original Research Article

# Evaluation of the malignancy risk in benign breast disease using screening mammography

Bharathidasan Rajamanickam<sup>1</sup>, Maheshwari Narayanan<sup>2\*</sup>,  
Mithun Govind Dandapani<sup>1</sup>, Ambujam<sup>1</sup>

<sup>1</sup>Department of General Surgery, <sup>2</sup>Department of Biochemistry, Vinayaka Missions Medical College, Karaikal, Puducherry, India

**Received:** 24 April 2019

**Revised:** 07 May 2019

**Accepted:** 09 May 2019

### \*Correspondence:

Dr. Maheshwari Narayanan,

E-mail: maheshwari22.narayanan@gmail.com

**Copyright:** © the author(s), publisher and licensee Medip Academy. This is an open-access article distributed under the terms of the Creative Commons Attribution Non-Commercial License, which permits unrestricted non-commercial use, distribution, and reproduction in any medium, provided the original work is properly cited.

## ABSTRACT

**Background:** Breast cancer is the most common female cancer worldwide representing nearly 25% of the population. The study was designed to find the correlation between mammographic screening and histopathology in the diagnosis of malignancy among patients breast disease.

**Methods:** This analytical study was done on 163 patients who came to the General Surgery Out-Patient Department, VMCM, Karaikal were screened. From this, 125 patients who were clinically diagnosed with benign breast disease were further evaluated with mammography. A detailed history, clinical examination, and investigations including mammography, histopathological examination in the operated specimen were done.

**Results:** In the study 10% lump in the central area, 20% in lower inner quadrant, 12% in lower outer quadrant, 22% in upper inner quadrant and 36% in upper outer quadrant. In the study, all the 100 subjects were diagnosed to have a benign lesion in mammogram, in hpe 87% were diagnosed to have benign lesion and 13% were diagnosed to have malignant lesions.

**Conclusions:** Even though BI-RADS 2 and 3 mammography showed the majority of benign lesions, there is an increasing trend of malignancy in higher BI-RADS criteria, on further histopathological examination. Sensitivity, positive predictive value, and diagnostic accuracy are very high for mammographic screening.

**Keywords:** Breast cancer, Bi-Rads, Lower quadrant, Histopathological

## INTRODUCTION

Earlier cervical cancer was the most common cancer in Indian woman but now the incidence of breast cancer has surpassed cervical cancer and is the leading cause of cancer death.<sup>1</sup> The main reasons for this observed hike in mortality are due to lack of adequate breast cancer screening, diagnosis of disease at advanced stage and unavailability of appropriate medical facilities.<sup>2,3</sup> According to various studies, the majority of carcinoma breast cases in the west report in stages I and II of the disease, whereas in India 45.7% report in advanced stages. Disease presentation in such conditions results in

increased mortality in India.<sup>4,5</sup> The observed breast cancer rates and HRs further contribute to evidence of an increase in breast cancer risk following benign biopsy, including some histologic diagnosis in the absence of atypia. Atypical hyperplasia, cytologic atypia, and lobular carcinoma *in situ* were associated with an elevated breast cancer risk that is consistent with other published data.<sup>6</sup> As a group, the more common low-risk histologic diagnosis showed a statistically significant association with subsequent breast cancer development, with a risk increase almost twice the risk experienced by women with normal mammogram evaluations.<sup>7,8</sup>

**METHODS**

This analytical study was done on 163 patients who came to the General Surgery out-patient department from the year 2017-2018 VMMC, Karaikal were screened. From this, 125 patients who were clinically diagnosed with benign breast disease were further evaluated with mammography. A detailed history, clinical examination, and investigations including mammography, histopathological examination in the operated specimen were done.

**Inclusion criteria**

Inclusion criteria were 30-70 years females; clinical diagnosis of benign breast disease; family history of benign breast disease/family history of breast malignancy; histological and radiological studies suggestive of benign breast disease.

**Exclusion criteria**

Exclusion criteria were a previous diagnosis of breast cancer; previous mastectomy (unilateral or bilateral) or breast reduction; biopsies with indeterminate histological classification.

**Procedure**

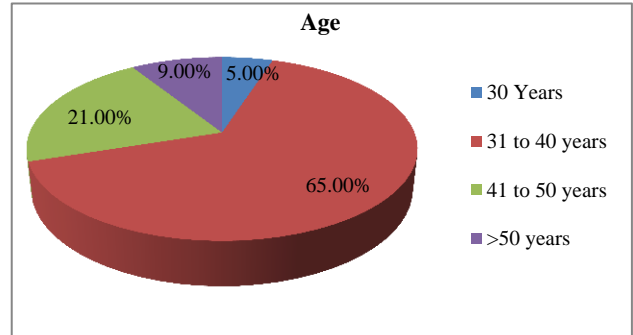
Women with screening mammograms scored with BIRADS 3, 4, 5, or 0 are recalled for further assessments within a maximum of 2 months after the screening test to confirm or to rule out malignancy. Further assessments may include imaging procedures (additional mammography, ultrasonography, and magnetic resonance imaging) and/or invasive procedures (fine-needle aspiration, core-needle biopsy, and open biopsy) If the further assessments rule out malignancy, women are invited to regular screening in 2 years. Cancers detected at regular screening and interval cancers were included in the analyses. Interval cancers (primary breast cancers diagnosed after a negative screening test and before the next screening invitation) were identified by merging data from screening participants with population-based cancer registries, the regional Minimum Basic Data Set, and hospital-based cancer registries. Both invasive and in situ carcinomas were considered in this study.

**Statistical analysis**

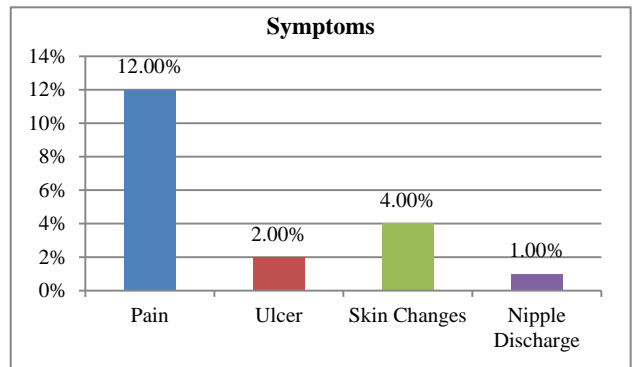
Data were entered into Microsoft excel data sheet and was analyzed using SPSS 22 version software. Categorical data was represented in the form of Frequencies and proportions. Chi-square test was used as a test of significance for qualitative data. Continuous data were represented as mean and standard deviation. Graphical representation of data: MS Excel and MS word were used to obtain various types of graphs such as bar diagrams and pie diagrams.

**RESULTS**

Figure 1 shows in the study, majority i.e. 65% were in the age group 31 to 40 years, 21% were in the age group 41 to 50 years, 9% were in the age group >50 years and 5% were 30 years.

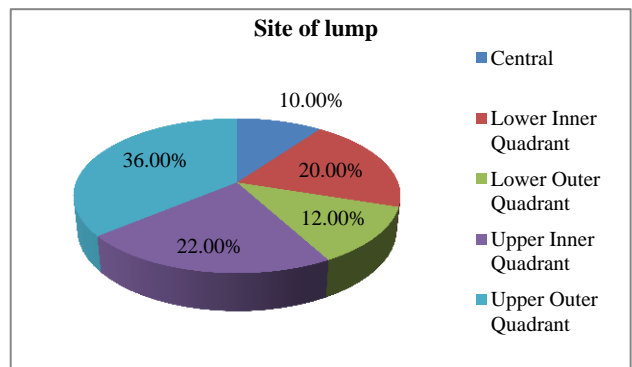


**Figure 1: Age distribution of subjects.**



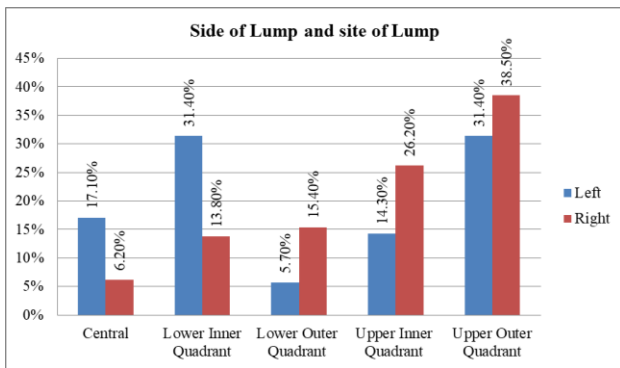
**Figure 2: Symptoms among subjects.**

Figure 2 shows the study, 12% presented with pain, 2% with ulcer, 4% with skin changes and 1% with nipple discharge.



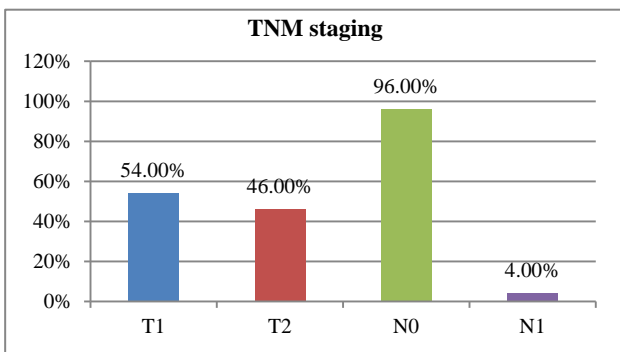
**Figure 3: Site of lump among subjects.**

In Figure 3, the study, 10% lump in the central area, 20% in lower inner quadrant, 12% in lower outer quadrant, 22% in upper inner quadrant and 36% in upper outer quadrant.



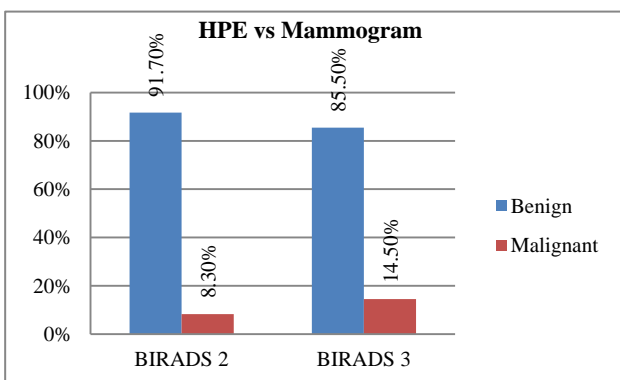
**Figure 4: Comparisons between side of lump and site of lump.**

Figure 4 shows in the study, on left side 31.4% had lump in upper outer quadrant and lower inner quadrant, 17.1% in central area, 14.3% in upper inner quadrant and 5.7% in lower outer quadrant. On right side, majority of subjects i.e. 38.5% had lump in upper outer quadrant, 26.2% in upper inner quadrant, 15.4% in lower-outer quadrant, 13.8% in lower-inner quadrant and 6.2% in the central area. There was a significant difference in the site of the lump with respect to the side of lump.



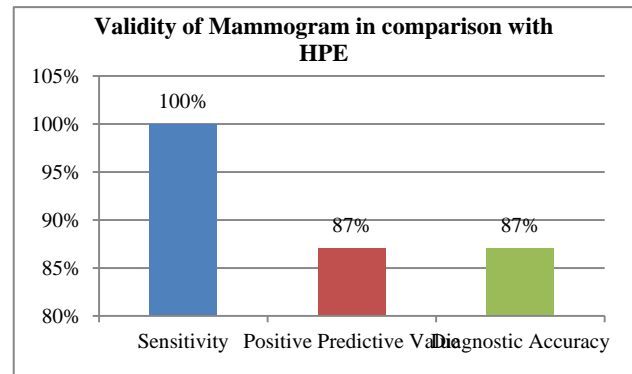
**Figure 5: TNM staging of tumour in the study.**

Figure 5 shows in the study 54% had T1 staging and 46% had T2 staging, 96% had N0 staging and 4% had N1 staging.



**Figure 6: Comparison between HPE and mammogram findings among subjects.**

Figure 6 shows in the study among 24 subjects with BI-RADS 2, 91.7% was benign lesion and 8.3% had malignant lesion and among 76 subjects with BI-RADS 3, 85.5% were benign lesions and 14.5% had malignant lesions. There was no significant association between Mammogram and HPE findings.



**Figure 7: Comparison between HPE and mammogram findings among subjects.**

Figure 7 shows in the study all the 100 subjects were diagnosed to have a benign lesion in Mammogram, in HPE 87% were diagnosed to have Benign lesion and 13% were diagnosed to have malignant lesions. The sensitivity of Mammogram in diagnosing Benign breast lesion was 100%, positive predictive value was 87% and diagnostic accuracy was 87%.

## DISCUSSION

Developed in the early 1990s, the BI-RADS scoring method has been used extensively as a surrogate to histopathological reporting of breast cancer. In BI-RADS mammograms are categorized from 0 – 6, with category 0 requiring further investigation and category 6 being a biopsy-proven malignancy.<sup>9</sup> Prior to the implementation of BI-RADS, there was a lack of uniformity in reporting of mammography findings and this often resulted in varied reporting and management strategies.<sup>10</sup> This ambiguity had also led to increased difficulties in establishing performances standards across settings. This had been the main impetus in developing the BI-RADS system and several research studies have shown the scoring system to be useful in predicting the likelihood of cancer.<sup>11</sup> These results are also seen in my study and hence further show the value of BI-RADS ineffective management of breast cancer.<sup>12</sup> In this study, majority i.e. 65% were in the age group 31 to 40 years, 21% were in the age group 41 to 50 years, 9% were in the age group >50 years and 5% were 30 years. The mean age was 39.27±7.22 years. This was in accordance with the literature and similar to a few other studies. Benign breast disease was seen commonly among the young age group. As age increases risk of malignancy increases. Hartmann et al noted that fibrocystic change is the most common disease in which precancerous lesions are seen. The most common age group of these lesions is 31–40 years. This

was similar to the present study. Benign breast lesions with associated precancerous breast lesions must be separated from pure benign breast lesions and need future evaluation and follow-up. In this study all women presented with lump and out of this, 12% presented with pain, 2% with an ulcer, 4% with skin changes and 1% with nipple discharge.<sup>13</sup> Jackson et al conducted a study matching with the present one and found that commonest presentation of benign breast diseases was breast lump followed by nodularity of the breast.<sup>14</sup> The commonest presentation was a breast lump which comprised 69 (69%) cases followed by the modularity of the breast (17%) and breast pain (13%). In this study, 23.7% attained menarche at 11 years of age, 20.6% at 12, 21.6% at 13, 18.6% at 14 and 15.5% at 15 years respectively which was statistically significant ( $p=0.004$ ). In the study, 22% of the subject's attained menopause and 78% not attained menopause. This was also statistically significant.<sup>14</sup> Kerlikowske their evaluation of risk factors for benign breast lesions in a case-control study based on 288 women with histologically proven benign breast disease (BBD) described that late menopause was associated with an increased risk of benign breast disease. Early age at menarche was associated with an increased risk, but the estimate was not statistically significant.<sup>15</sup> Lehman Kin their study reaffirmed that the upper and outer quadrant was the commonest site of the lump in our patients (55 patients), while the upper inner quadrant was involved in 37, the lower and outer in 15 and the lower and inner quadrant in Liberman et al in his series had 29 patients (58%) with the lump in the upper and outer quadrant.<sup>16,17</sup> Both studies showed the upper and outer quadrant to be the dominant quadrant to have a palpable lump. These findings were very similar to the present study, in the study among 24 subjects with BI-RADS 2, 91.7% was benign lesion and 8.3% had malignant lesion and among 76 subjects with BI-RADS 3, 85.5% were benign lesions and 14.5% had malignant lesions. There was no significant association between Mammogram and HPE findings ( $p=0.436$ ).<sup>17</sup> All the 100 subjects were diagnosed to have a benign lesion in Mammogram, in HPE 87% were diagnosed to have Benign lesion and 13% were diagnosed to have malignant lesions. It was found to have 100% Sensitivity (95% CI=95.77, 100), 87% Positive Predictive Value (95% CI=79.02, 92.24) and equal percentage of Diagnostic Accuracy (95% CI=79.02, 92.24)<sup>18</sup> In another related study, Orel et.al found that the standardized terminology of the BI-RADS lexicon does allow quantification of the likelihood of malignancy for various lesions. In that study, the features with the highest positive predictive value were spiculated margins, irregular shape, linear morphology of microcalcifications, and the segmental or linear distribution of microcalcifications. The predictive accuracy in these two categories is large enough to encourage more active utilization of BI-RADS.<sup>19,20</sup>

## CONCLUSION

Even though the correlation between family history with breast malignancy is not statistically significant, there is a

greater risk of developing high-risk types of benign breast disease in families with a history of breast cancer. Early menarche is associated with increased risk of benign breast disease. Correlation of age of menopause and risk of breast disease is inconclusive as the majority did not attain menopause. Upper outer quadrant is the most common site of a benign breast lump, which is statistically significant.

*Funding: No funding sources*

*Conflict of interest: None declared*

*Ethical approval: The study was approved by the Institutional Ethics Committee*

## REFERENCES

1. Ballard-Barbash R, Taplin SH, Yankaskas BC. Breast Cancer Surveillance Consortium: a national mammography screening and outcomes database. *Am J Roentgenol.* 1997;169(4):1001–8.
2. Bassett LW. Quality determinants of mammography: clinical image evaluation. In: Kopans DB, Mendelson EB, eds. *Syllabus: a categorical course in breast imaging.* Oak Brook, Ill: Radiological Society of North Am. 1995: 57- 67.
3. Berg WA, Campassi C, Langenberg P, Sexton MJ. Breast imaging reporting and data system: Inter- and Intraobserver variability in feature analysis and final assessment. *AJR Am J Roentgenol.* 2000;174:1769–77.
4. Berg WA, D'Orsi CJ, Jackson VP, Bassett LW, Beam CA, Lewis RS. Does training in the Breast Imaging Reporting and Data System (BI-RADS) Improve biopsy recommendations or feature analysis agreement with experienced breast imagers at mammography? *Radiology.* 2002;224:871–80.
5. Boyd NF, Guo H, Martin LJ. Mammographic density and the risk and detection of breast cancer. *N Engl J Med.* 2007;356(3):227–36.
6. Byrne C, Schairer C, Brinton LA. Effects of mammographic density and benign breast disease on breast cancer risk (United States). *Cancer Causes Control.* 2001;12(2):103–10.
7. Carter CL, Corle DK, Micozzi MS. A prospective study of the development of breast cancer in 16,692 women with benign breast disease. *Am J Epidemiol.* 1988;128(3):467–77.
8. Cummings SR, Tice JA, Bauer S. Prevention of breast cancer in postmenopausal women: approaches to estimating and reducing risk. *J Natl Cancer Inst.* 2009;101(6):384–98.
9. D'Orsi CJ. American College of Radiology mammography lexicon: an initial attempt to standardize terminology. *AJR.* 1996;166:779-80.
10. Dupont WD, Page DL. Risk factors for breast cancer in women with proliferative breast disease. *N Engl J Med.* 1985;312(3):146–51.
11. Elmore JG, Barton MB, Mocerri VM. n-year risk of false positive screening mammograms and clinical

- breast examinations. *N Engl J Med.* 1998;338:1089-96.
12. Frederick BW Jr, Samuel WB, Bland KI. History of breast cancer. In: *The Breast – Comprehensive management of benign and malignant disease*, (3rd ed.). Philadelphia: WB Saunders; 2001: 220.
  13. Hartmann LC, Sellers TA, Frost MH. Benign breast disease and the risk of breast cancer. *N Engl J Med.* 2005;353(3):229–37.
  14. Jackson FI. Acceptability of periodic follow-up as an alternative to biopsy for mammographically detected lesions interpreted as probably benign. *Radiology.* 1989;173:580-1.
  15. Kerlikowske K, Cook AJ, Buist DS. Breast cancer risk by breast density, menopause, and postmenopausal hormone therapy use. *J Clin Oncol.* 2010;28(24):3830–7.
  16. Lehman CD, Rutter CM, Eby PR, White E, Buist DS, Taplin SH. Lesion and patient characteristics associated with malignancy after a probably benign finding on community practice mammography. *AJR Am J Roentgenol.* 2008;190:511–5.
  17. Liberman L, Abramson AF, Squires FB, Glassman JR, Morris EA, Dershaw DD. The breast imaging reporting and data system: positive predictive value of mammographic features and final assessment categories. *AJR.* 1998;171:35-40.
  18. Ojeda FH, Nguyen J. How to improve your breast cancer program: standardized reporting using the new American College of Radiology Breast Imaging-Reporting and Data System. *Indian J Radiol Imaging.* 2009;19(4):266–77.
  19. Orel SG, Kay N, Reynolds C, Sullivan DC. BI-RADS categorization as a predictor of malignancy. *Radiology.* 1999;211:845–50.
  20. Page DL, Dupont WD, Rogers LW. Atypical hyperplastic lesions of the female breast: A long-term follow-up study. *Cancer.* 1985;55(11):2698–708.

**Cite this article as:** Rajamanickam B, Narayanan M, Dandapani MG, Ambujam. Evaluation of the malignancy risk in benign breast disease using screening mammography. *Int Surg J* 2019;6:1887-91.