

Case Report

Segment V spontaneous hepatic haemorrhage from hepatic cirrhosis: an emergency abdominal surgery case report

Budhi Ida Bagus^{1*}, Metria Ida Bagus², Fittrani Andri³

¹Department of Surgery, Sebelas Maret University, Indonesia

²Department of Surgery, Medical Faculty, Sebelas Maret University, Indonesia

³Department of Surgery, Moewardi General Hospital, Indonesia

Received: 20 November 2018

Accepted: 30 January 2019

*Correspondence:

Dr. Budhi Ida Bagus,

E-mail: budhi_suryaadnyana@yahoo.com

Copyright: © the author(s), publisher and licensee Medip Academy. This is an open-access article distributed under the terms of the Creative Commons Attribution Non-Commercial License, which permits unrestricted non-commercial use, distribution, and reproduction in any medium, provided the original work is properly cited.

ABSTRACT

A spontaneous hepatic haemorrhage (SHH) is a rare condition that results from a breach in the hepatic parenchyma that occurs without an external cause. It is an acute surgical emergency as it results in intra-abdominal bleeding that, if untreated, will progress to haemorrhagic shock and death. The clinical presentation is often non-specific but emergent, and rapid diagnosis and treatment is required, often involving a number of services including interventional radiology, hepatology and surgery. SHH is a rare event most commonly caused by HCC and hepatic adenoma although there are numerous other causative lesions including all recognized benign and malignant hepatic tumours including metastatic cancer. The mechanism of spontaneous bleeding remains unclear but there is evidence for compromised vascular integrity at least in patients with HCC and the incidence of the condition in patients with connective tissue diseases. A diagnosis of SHH is based on a clinical index of suspicion in patients with a known underlying condition. However, this is not always as straightforward as SHH is a rare complication in patients with connective tissue disease. Spontaneous hepatic haemorrhage is one of acute abdominal emergency case with high morbidity and mortality rate. Emergency operation plays an important role in managing this case.

Keywords: Abdominal emergency, Cirrhosis, Emergency operation, Morbidity, Mortality, Spontaneous hepatic haemorrhage

INTRODUCTION

A spontaneous hepatic haemorrhage (SHH) is a rare condition that presents acutely to both hepatobiliary and general surgeons. Management of the condition is challenging because of the emergent presentation requiring immediate intervention, the presence of underlying chronic liver disease and the multiple potential underlying aetiological conditions.¹

The clinical presentation is often non-specific but emergent, and rapid diagnosis and treatment is required, often involving a number of services including

interventional radiology, hepatology and surgery. The acute management can be complex because of co-existing chronic liver disease, and this may contribute to poor outcomes. In spite of these issues, SHH has never been comprehensively reviewed possibly because of its rarity, the potentially wide range of underlying conditions.^{2,3}

A diagnosis of SHH is based on a clinical index of suspicion in patients with a known underlying condition. However, this is not always as straightforward as SHH is a rare complication in patients with connective tissue disease. In many patients with adenoma, SHH is the first presentation and in patients with HCC SHH will be the

first presentation in up to 80%. Initial workup should include an assessment of liver function, coagulation status with the emphasis on defining and quantifying underlying hepatic function and the presence of cirrhosis.^{1,3}

CASE REPORT

We reported a single rare case of 56 years old male, presented to our emergency department with pain at whole abdomen since 24 hours before admission. There was no history of trauma before. The patients was diagnosed with diffuse peritonitis and haemorrhagic shock grade III with previous untreated Hepatitis C history. Emergency laparotomy was done, 2500 cc blood found intraoperatively with spontaneous bleeding from segmen V of the liver and minimal bile leak came out from the edge of the liver laceration. The bleeding was came out from laceration of the liver parenchyma, oozing from the edge of the liver laceration and there was no active bleeding from great vessel found during exploration, as seen on Figure 1. Controlled of the bleeding can be done by hepatoraphy using absorbable material along the edge of the segment 5th liver laceration according to Couinaud liver segmentation (as seen on Figure 2) and no other procedure was needed to control the bleeding. Liver biopsy from the edge of the liver laceration was taken, there was no liver nodul found during exploration. The pathologic result was liver cirrhosis. Seven packed red cell (PRC) transfusion was needed during post operative treatment on the intensive care unit (ICU). There were no post operative complication and this patient discharged from hospital on day 6 with no further morbidity and bile leak post operatively.

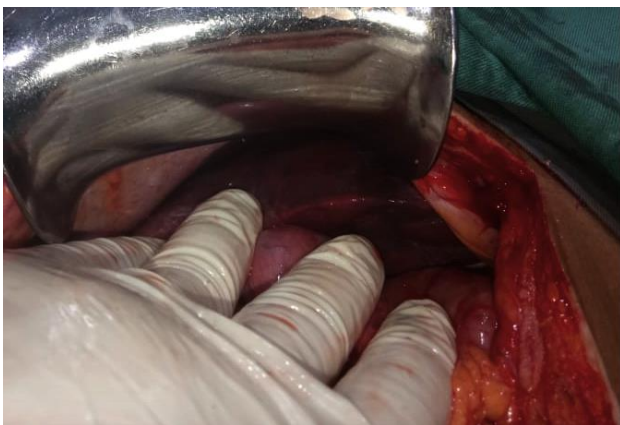


Figure 1: Segmen V hepatic haemorrhage.

Another option to control the bleeding from spontaneous hepatic haemorrhage is performing computerize tomography scanning angiography to evaluate the source of the bleeding and possibility to do embolization, but this technique can only be done in stable haemodynamic patients. 2 weeks after discharged from hospital, we did abdominal CT Scan to evaluate any other pathology from

the liver, there was no liver nodul found from the abdominal CT and no intra abdominal fluid collection was found after surgery.

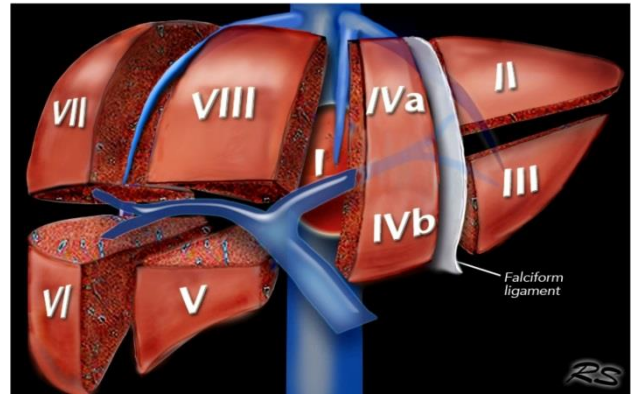


Figure 2: Couniaud liver segmentation.

DISCUSSION

Cirrhosis results from chronic liver disease, and is characterized by advanced fibrosis, scarring, and formation of regenerative nodules leading to architectural distortion. In the past cirrhosis was generally thought to be irreversible but recent studies have shown that treatments aimed at the underlying cause especially in earlier stages of the disease can improve or even reverse fibrosis. Patients with cirrhosis are at increased risk of numerous complications and have a decreased life expectancy. In 2010, cirrhosis was the eight leading cause of death in the United States and, combined with its complications accounted for approximately 49500 deaths.^{1,4,5}

Cirrhosis can remain compensated for years before development of decompensating events like jaundice, ascites, encephalopathy and/or variceal hemorrhage. The median survival of patients with compensated cirrhosis is much longer than in patients with evidence of decompensation and is about 9 years.^{1,5,6,7}

The main goals of management of compensated cirrhosis are (1) treatment of underlying etiology; (2) early recognition and treatment of complications; and (3) preventing superimposed insults. Specific therapy directed against underlying etiology has shown to improve survival, long-term outcomes and regression of fibrosis. Evidence favoring regression of cirrhosis has now been documented in entire spectrum of chronic liver diseases including viral hepatitis, autoimmune hepatitis, primary biliary cirrhosis, biliary obstruction, NASH and hemochromatosis. The last few years have seen significant improvement in cure rates for chronic liver disease especially viral hepatitis though the use of more effective anti-viral therapy for hepatitis B virus (HBV), HBC and HBD. More importantly regression of fibrosis associated with ant-viral therapy is associated with improved liver function.^{2,8,9}

Spontaneous hemorrhage from the liver occurs evenly from benign or malignant causes, one-third of which are primary liver disease. If the patients presents emergently, angiographic embolization may control the bleeding and allow for elective resection once the sequelae of bleeding have resolved.^{3,10,11}

A spontaneous hepatic haemorrhage (SHH) is a rare condition that results from a breach in the hepatic parenchyma that occurs without an external cause. It is an acute surgical emergency as it results in intra-abdominal bleeding that, if untreated, will progress to haemorrhagic shock and death. The clinical presentation is often non-specific but emergent, and rapid diagnosis and treatment is required, often involving a number of services including interventional radiology, hepatology and surgery. The acute management can be complex because of co-existing chronic liver disease, and this may contribute to poor outcomes. In spite of these issues, SHH has never been comprehensively reviewed possibly because of its rarity, the potentially wide range of underlying conditions and the fact that many publications in the area are small series of less than five patients or case reports.^{1,3}

SHH is a rare event most commonly caused by HCC and hepatic adenoma although there are numerous other causative lesions including all recognized benign and malignant hepatic tumours including metastatic cancer. The mechanism of spontaneous bleeding remains unclear but there is evidence for compromised vascular integrity at least in patients with HCC and the incidence of the condition in patients with connective tissue diseases (amyloid and SLE) and polyarteritis nodosa indicates that this is an important factor in the pathogenesis of the condition. Cross-sectional imaging with CT scanning is the mainstay of diagnosis and initial management emphasizes the use of arterial embolization to obtain haemostasis with a hepatectomy reserved for patients with bleeding tumours after formal staging and assessment of their liver function.^{3,10,12}

Another cause of spontaneous hepatic haemorrhage is rupture of the liver tumor. Hepatic hemangioma is the most common benign liver tumor, with the majority being cavernous hemangiomas, with little chance of malignant transformation. In general, a hepatic hemangioma with a diameter <4 cm is asymptomatic and prone to be neglected, being discovered only as an incidental imaging finding. The diagnosis of a hepatic hemangioma is dependent on ultrasound, CT, and magnetic resonance imaging, all of which provide a diagnostic accuracy of >90%. Hepatic hemangiomas with a diameter >4 cm are regarded as giant hemangiomas and can cause symptoms such as abdominal discomfort and other catastrophic complications including rupture, internal hemorrhage, coagulation disorder.^{4,12}

CONCLUSION

Spontaneous hepatic haemorrhage is one of acute abdominal emergency case with high morbidity and mortality rate. Emergency operation play an important role in managing this case.

Funding: No funding sources

Conflict of interest: None declared

Ethical approval: Not required

REFERENCES

1. Nusrat S, Khan MS, Fazili J, Madhoun MF. Cirrhosis and its complications: Evidence based treatment. World J Gastroenterol. 2014;20(18):5442–60.
2. Srinivasa S, Lee WG, Aldameh A, Koea JB. Spontaneous hepatic haemorrhage: a review of pathogenesis, aetiology and treatment. HPB (Oxford). 2015;17(10):872–80.
3. Rosales A, Que FG. Spontaneous Hepatic Hemorrhage: A Single Institution's 16-Year Experience. Am Surg. 2016;82(11):1117–20.
4. Fulong H, Xiaoli Y. Spontaneous internal hemorrhage of a giant hepatic hemangioma. Medicine (Baltimore). 2017;96(47):e8702.
5. Oshita N, Itamoto T, Oshita A. A rare case of a spontaneously ruptured secondary hepatic malignant lymphoma. Surg Case Rep. 2018;4:44.
6. Recordare A, Bonariol L, Caratozzolo E, Callegari F, Bruno G, Di Paola F. Management of spontaneous bleeding due to hepatocellular carcinoma. Minerva Chir. 2002;57(3):347–56.
7. Nakao A, Matsuda T, Koguchi K, Funabiki S, Mori T, Kobashi K. Spontaneous rupture of hepatocellular carcinoma of the caudate lobe. Anticancer Res. 2000;20(3):2223–7.
8. Yoshida H, Mamada Y, Tani N, Uchida E. Spontaneous ruptured hepatocellular carcinoma. Hepatol Res. 2016;46(1):13–21.
9. Zhu LX, Geng XP, Fan ST. Spontaneous rupture of hepatocellular carcinoma and vascular injury. Arch Surg. 2001;136:682–7.
10. Ong GB, Chu EP, Yu FY, Lee TC. Spontaneous rupture of hepatocellular carcinoma. Br J Surg. 1965;52:123–9.
11. Leung KL, Lau WY, Lai PB, Yiu RY, Meng WC, Leow CK. Spontaneous rupture of hepatocellular carcinoma. Conservative management and selective intervention. Arch Surg. 1999;134:1103–7.
12. Deneve JL, Pawlik TM, Cunningham S, Clary B, Reddy S, Scoggins C, et al. Liver cell adenoma: a multicenter analysis of risk factors for rupture and malignancy. Ann Surg Oncol. 2009;16:640–8.

Cite this article as: Bagus BI, Bagus MI, Andi F. Segment V spontaneous hepatic haemorrhage from hepatic cirrhosis: an emergency abdominal surgery case report. Int Surg J 2019;6:1013-5.