

Original Research Article

Surgical treatment of Abdominal Echinococcosis

Anuroop Thota¹, A. Dinakar Reddy^{2*}, Venkata Narasimha Rao V.¹

¹Department of General Surgery, ²Department of Surgical Gastroenterology, NRI Medical College and General Hospital, Chinnakakani, Guntur District, Andhra Pradesh, India

Received: 25 October 2018

Accepted: 29 October 2018

***Correspondence:**

Dr. A. Dinakar Reddy,

E-mail: dinakar.reddy04@gmail.com

Copyright: © the author(s), publisher and licensee Medip Academy. This is an open-access article distributed under the terms of the Creative Commons Attribution Non-Commercial License, which permits unrestricted non-commercial use, distribution, and reproduction in any medium, provided the original work is properly cited.

ABSTRACT

Background: Cystic Echinococcosis is a zoonosis with worldwide geographical distribution caused by dog tapeworm. Cystic echinococcosis most frequently involves only one organ by forming a solitary cyst. Hydatid disease commonly involves the liver (75%) and lungs (15%), followed by other regions of the body (10-15%). Multi-organ abdominal HD is the most serious form and is potentially fatal.

Methods: It is a retrospective study for a duration of 3 years. The recorded data of all the patients undergoing treatment has been collected and analyzed.

Results: A total of 30 patients were identified. Most common organ involved was liver followed by spleen, pancreas and kidney. Cysts are more commonly seen in right lobe. All the patients underwent surgical treatment. 17 patients underwent open surgery, while 13 patients were treated by laparoscopy. Cysto biliary communication was identified in 3 patients, all in laparoscopy and a primary closure was done. All the patients were started on albendazole 400 mg twice daily per oral at least 15 days prior to surgery and this treatment was continued for 3 months post-operatively.

Conclusions: Hydatid disease is endemic in sheep farming and cattle farming areas of Asia. Most patients remain asymptomatic for years. Diagnosis is by imaging techniques. Echinococcal infection usually requires multimodality treatment and the best treatment is always individualized. Surgery along with anti-helminthic treatment holds the best curative measure at present.

Keywords: Cystic echinococcosis, Echinococcosis, Hydatid disease, Pericystectomy, Zoonosis

INTRODUCTION

Cystic Echinococcosis is a zoonosis with worldwide geographical distribution. It is caused by dog tapeworm, *Echinococcus granulosus* and is endemic in livestock raising areas.¹ The mature forms of the parasite lodge in the intestines of animals like dogs and eggs are excreted in feces. These eggs can be ingested by humans and we become an end point to the life cycle.^{1,2} After ingested eggs are digested in the stomach and oncosphere larva enters the small intestine. It then pierces the small intestine wall and enters the circulatory system. It can

access any solid organs, but majority reach the liver and lung. Cystic echinococcosis most frequently involves only one organ by forming a solitary cyst. The metacestode growth and formation of a cyst is the beginning of a chronic disease named cystic echinococcosis or hydatidosis.³

Hydatid disease commonly involves the liver (75%) and lungs (15%), followed by other regions of the body (10-15%). Multi-organ abdominal HD is the most serious form and is potentially fatal.⁴ Diagnosis of cystic echinococcosis is based mainly by imaging, while

serology tests such as indirect hemagglutination, enzyme linked immunosorbent assay, immunoblots or latex agglutination that use antigens specific for *E. granulosus* are used to verify the imaging results.⁵ The imaging technique of choice for is ultrasonography. MRI is often preferred to CT scans when diagnosing cystic echinococcosis since it gives better visualization of liquid areas within the tissue². Management options for cystic echinococcosis (CE) include surgery, percutaneous management (puncture, aspiration, injection, and respiration), drug therapy, and observation.

The aim of the study is to evaluate the surgical treatment of abdominal echinococcosis in the department of surgical gastroenterology at NRI General hospital.

The parameters analyzed are:

- Epidemiology
- Clinical features
- Diagnosis
- Surgical treatment
- Post-operative morbidity

METHODS

Present study was a retrospective study. Duration of the study was 3 years. Recorded data was collected from medical records department.

Inclusion criteria

All the patients who have been surgically treated for abdominal echinococcosis in the department of surgical gastroenterology at NRI General Hospital are included in the study.

Exclusion criteria

- Cases not treated surgically
- Cases with extra abdominal echinococcosis

Procedure to be followed

This is a retrospective study. The recorded data of the patients who underwent surgical management for abdominal echinococcosis during the study period was collected. The factors analyzed are epidemiology, clinical features, diagnosis, choice of surgical management and post-operative morbidity.

Statistical analysis

Descriptive and inferential statistical analysis has been carried out in the present study. Results on continuous measurements are presented on Mean \pm SD (Min-Max) and results on categorical measurements are presented in number (%). Significance is assessed at 5 % level of significance. Chi-square/Fisher exact test has been used

to find the significance of study parameters on categorical scale between two or more groups.

RESULTS

A total of 30 patients, who underwent surgical treatment for abdominal echinococcosis were identified. The mean age was 46.7 years with range between 24-75 years. Males and females are equally distributed with a M:F of 1:1.1. Majority of the patients are from rural background. The most common presenting complaint was pain abdomen, which is seen in 28 patients (93.3%), swelling was the presenting complaint in 2 patients (6%), 1 patient presenting with an ulcer over the anterior abdominal wall. This ulcer was due to the pressure necrosis caused by underlying cyst. Only 1 patient presented with clinical jaundice (Table 1).

Table 1: Epidemiological and clinical data.

Variable	Number
Total number of cases	30
Age (mean)	46.7 years
M:F	1:1.1
Rural:urban	4:1
Presenting complaints	
Pain	26
Swelling	2
Jaundice	1
Ulcer over the abdomen	1
Palpable mass	
Hepatomegaly	7
Splenomegaly	2
Co-morbidities	
Hypertension	4
Diabetes mellitus	2
Coronary artery disease	1

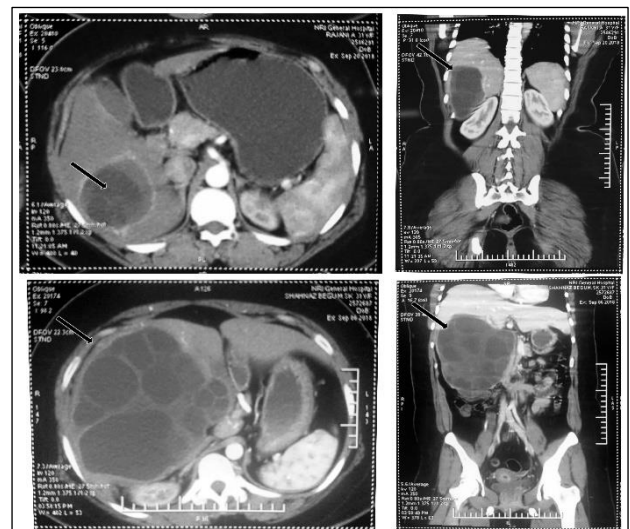


Figure 1: Contrast Enhanced Computed Tomography (CECT) images showing cyst in liver.

Seven patients had co-existing comorbidities. Hypertension was most common and was found in 4 patients. On per abdominal examination, a palpable mass was felt in 11 cases. Out of these 9 cases had a hepatomegaly, while 2 cases had splenomegaly. On blood investigations, serum bilirubin ranged between 0.2-2.8 with a mean of 0.57. Biochemical elevation of serum bilirubin was seen in 2 cases. Serum alkaline phosphatase (ALP) was elevated in 9 patients with a range of 40-220 and a mean of 114.9. Total leucocyte count was elevated in 3 patients. Ultrasonogram and contrast enhanced computed tomography (CECT) (Figure 1) of the abdomen was done in all the patients. Mostly common organ involved was liver: 25 cases (83%), spleen alone 2 cases, pancreas alone 1 case, liver and spleen 1 case, liver and kidney 1 case (Table 2).

Table 2: Imaging and biochemical analysis.

Organ involved	
Liver alone	25
Spleen alone	2
Pancreas alone	1
Liver + Spleen	1
Liver + Kidney	1
Biochemical parameters	
Serum Bilirubin	0.2-2.8 mg/dl
Serum Alkaline Phosphatase	40-220 IU
Total Leucocyte count	3500-16,000 cells/cu.mm

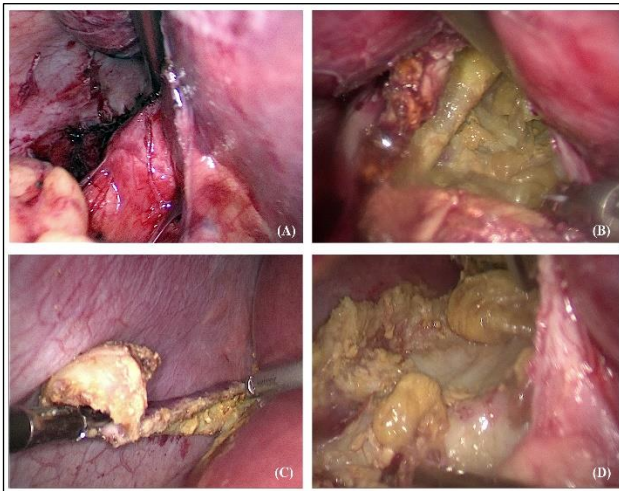


Figure 2: Laparoscopic images: (a) Hydatid cyst in the inferior surface of liver; (B) and (D) Cyst cavity with daughter cysts; (C) Pericystectomy.

Cysts are more commonly seen in right lobe. Patients with cysts in the liver underwent open or laparoscopic marsupialisation. Splenectomy was done for splenic hydatid cysts and the patient with hydatid cyst in the tail of pancreas underwent distal pancreatectomy and splenectomy. Patient with splenic cysts were given triple vaccination atleast 10 days prior to surgery. All the patients underwent surgical treatment. 17 patients

underwent open surgery, while 13 patients were treated by laparoscopy (Figure 2) (Table 3).

Table 3: Distribution of types of surgery.

Organ involved	No. of cases	Procedure done	
		Laparoscopy	Open
Liver	27	Pericystectomy (13)	Pericystectomy (17)
Pancreas (tail)	1	-	Distal pancreatectomy + Splenectomy
Spleen	3	-	Splenectomy
Kidney	1	-	Pericystectomy

Mean duration of surgery in patients undergoing open surgery was 122.6 mins, and in those undergoing laparoscopic surgery was 114.6 mins (Table 4).

Table 4: Operative analysis.

Variable	Laparoscopy	Open
No. of cases	13	17
Mean duration of surgery (mins)	114.6	122.6
Mean duration of hospital stay (days)	6.5	9.2
Incidental cholecystectomy	4	2
Cysto biliary communication	3	0
Post OP bile leak	4	4
Post OP infection/seroma	2	3

Intraoperatively, Gall bladder was seen adherent to the cyst in 6 cases. All these patients underwent incidental cholecystectomy. Bile stained content was seen in 2 cases. Hypertonic saline was used in all cases for disinfection. Cysto biliary communication (Figure 3) was identified in 3 patients, all in laparoscopy and a primary closure was done.

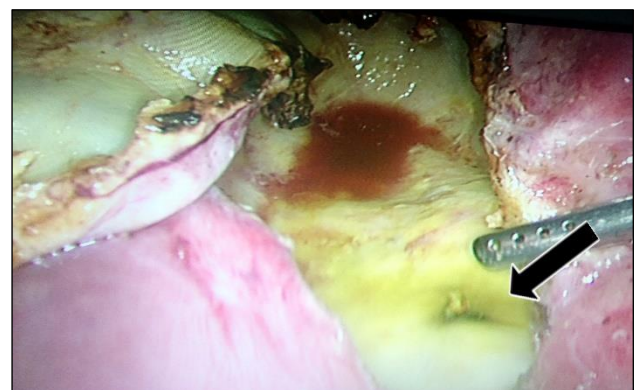

Figure 3: Cysto-biliary communication (arrow) in a hydatid cyst of liver with bile stained fluid.

An intra- abdominal tube drain was placed in all cases. Post-operative bile leak was observed in 8 cases. In 6

cases, there was spontaneous stoppage. In 1 patient, Endoscopic retrograde cholangio pancreatography (ERCP) was done and one patient had failed ERCP and had to undergo re-exploration. She underwent hepatico-jejunostomy. Mean duration of hospital stay in patients undergoing open surgery was 9.2 days and in those undergoing laparoscopies was 6.5 days. All the patients were discharge with the abdominal drain. A review ultrasound was done after 1 week of discharge and the drain was removed. 5 cases had persistent collection in the bed and drain was left in situ for prolonged period. 4 cases developed fever and collection after drain removal and was found to have intra-abdominal collection, were treated with ultrasound guided pig tail insertion and intravenous antibiotics. All the patients were started on albendazole 400 mg twice daily per oral at least 15 days prior to surgery and this treatment was continued for 3 months post-operatively.

DISCUSSION

Hydatid disease is endemic in sheep farming and cattle farming areas of Asia. Dogs and other carnivorous animals are definitive hosts, while sheep, cattle, horses, and goats are intermediate hosts. Humans are aberrant immediate hosts as they accidentally consume eggs of adult tapeworms previously excreted by definitive hosts.¹ More than 80-90% of hydatid cysts occur in the liver, lungs, or both. Hydatid cysts have been infrequently reported in the spleen, kidney, peritoneal cavity, skin, and muscles and rarely involve the heart, brain, vertebral column, ovaries, pancreas, gallbladder, thyroid gland, breast, and bones.⁴

Spleen involvement in 0.5-8% of all cases, usually associated with the presence of cysts in the liver or another intra-abdominal organ. In around 2% of cases, the spleen is the only organ involved (primary infection).⁶ Primary hydatid cyst of the pancreas is rare with an incidence of 0.25%.⁷ Head of pancreas is the most common location (57%), followed by corpus (24%) and tail (19%).⁸ Two types of *E. granulosus* infections in humans are distinguished; namely primary and secondary cystic echinococcosis. In primary infection (most frequent) the orally ingested eggs reach one of the organs (mainly liver) and form a cyst(s). The secondary form occurs when cyst is ruptured and protoscoleces are released into the abdominal cavity or any neighboring sites and the process of new infection is initiated.⁹

Most patients remain asymptomatic for years before presenting with vague abdominal symptoms such as nonspecific pain, abdominal fullness, dyspepsia, anorexia, and vomiting. The most frequent symptoms were abdominal pain and nausea. About one third of the patients with hydatid liver presented with complications. The most common complications were infection and rupture of the cyst into the biliary tree. The other less common complications include intraperitoneal rupture, intrathoracic rupture, internal rupture, rupture into

viscera, rupture into vascular system and external compression leading to portal hypertension.^{10,11}

Diagnosis of hepatic cystic echinococcosis is mainly based upon imaging techniques. The ultrasound screening is still the basis for initial diagnosis. Following initial screening, computed tomography of the abdomen is usually performed. Cysts can be detected using imaging techniques if their size exceeds 1 cm. Ultrasound appearance of the cysts is a basis for Gharbi classification introduced in 1981. Nowadays, the Gharbi's classification has been modified and subsequently the WHO Informal Working Group on Echinococcosis (WHO-IGWE) classification has been introduced.¹² MRI, with its superior contrast resolution on both T1 and T2 weighted images, better demonstrates the pericyst, matrix, and daughter cysts and establishes the diagnosis.¹³ It can also be confirmed after evaluation of specific antibodies. IgG-ELISA should be applied as the first-choice test with sensitivity exceeding 90%. The immunoblot or other immunodiagnostic tests could be indicated when IgG-ELISA test is inconclusive.¹⁴

Treatment is based upon the WHO guidelines. There are no randomised clinical trials to date that could compare different treatment modalities and, accordingly, the strength of recommendations is moderate. Modalities can be divided into interventional and non-interventional. Interventional methods consist of surgery and percutaneous procedures. Non-interventional management is based on administration of antiparasitic drugs. There is also a "watchful waiting" strategy that may be considered in uncomplicated and small lesions.¹⁴ Junghanss et al, the idea of leaving uncomplicated, inactive cysts untreated and solely monitored over time follows the observation that a good proportion of cysts become spontaneously inactive without any treatment and such cysts are likely to remain stable over time.¹⁵

PAIR technique stands for puncture, aspiration, injection and respiration. The solution used is 95% ethanol. Gupta et al published a retrospective study that compared 52 patients treated with the PAIR technique, with or without drainage, with 61 patients treated with radical/excisional surgery and 33 with conservative surgery.¹⁶ It was concluded that for a safe PAIR procedure, it is very important to select only patients with type I or II cysts, according to Gharbi's classification.

Surgery is considered as the modality of choice for symptomatic and complicated cases. The targets of surgical treatment are: (a) inactivation of infectious material, (b) prevention of contamination (spillage), (c) elimination of all viable elements (endocyst), and (d) management of the residual cavity.¹⁷ Surgical techniques usually involve anatomical or non-anatomical liver resections, including cystopericystectomy. Surgery as a radical form of treatment provides a chance for cure. pre- and postoperative courses of albendazole and praziquantel should be considered to sterilize the cyst and

reduce the chance of anaphylaxis and recurrence.⁴ A study by Georgiou et al showed that radical surgical procedures are superior to conservative surgical methods like partial cystectomy.¹⁸

In this era of minimal access surgery, laparoscopic treatment of hydatid disease has gained huge interests. All the advantages of laparoscopy hold good for the treatment of hydatid disease with a drastic decrease in post-operative morbidity and hospital stay. An added advantage is the possibility of better visualization of a cysto-biliary communication in view of enhanced image quality. Zaharie et al compared 59 patients treated with the laparoscopic approach with 172 patients treated with open surgery.¹⁹ They concluded that the laparoscopic approach is safe for the treatment of liver hydatidosis in almost all segments of the liver.

Aclri K in a 23 years retrospective study on hydatid cysts concluded that laparoscopic management of hydatid cysts can be performed safely and successfully with certain precautions and careful patient selection is mandatory to achieve successful results.²⁰ The most common complications after surgical treatment are cavity infection and biliary fistula. Biliary communications are reportedly common. They are mainly of 2 types: complicated and simple.²⁰ Complicated biliary communication denotes presence of rupture on both sides, bile duct and membrane of cyst. Simple biliary communication indicates rupture on the external bile duct, with an intact membrane of the cyst. Most of the fistula close spontaneously and few requires ERCP. In the present study, we performed both open and laparoscopic surgery for hydatid cysts. The results in both groups are comparable in view of operative time, complication rate. However, the post-operative hospital stay and morbidity was less in laparoscopy group. Serological tests may remain positive for years even after complete surgical removal, and do not imply the presence of active (re)infection.

Drawbacks of the study of this study were follow up is inadequate, it was non-randomized, retrospective study.

CONCLUSION

Echinococcal infection usually requires multimodality treatment and the best treatment is always individualized. Surgery along with anti-helminthic treatment holds the best curative measure at present. Despite substantial developments in diagnostic methods, a consensus is yet to be reached regarding the modality of choice. Randomized control trails are required to substantiate the results and provide proper guidelines in the management.

Funding: No funding sources

Conflict of interest: None declared

Ethical approval: The study was approved by the Institutional Ethics Committee

REFERENCES

- McManus DP, Zhang W, Li J, Bartley PB. Echinococcosis. *Lancet*. 2003;362:1295-304.
- Brunetti E, Kern P, Vuitton DA. Expert consensus for the diagnosis and treatment of cystic and alveolar echinococcosis in humans. *Acta Tropica*. 2010;114:1-16.
- Eckert J, Deplazes P. Biological, epidemiological, and clinical aspects of Echinococcosis, a zoonosis of increasing concern. *Clin Microbiol Rev*. 2004;17:107-35.
- Zheng X, Zou Y, Yin C. Rare presentation of multi-organ abdominal echinococcosis: report of a case and review of literature. *Int J Clin Exp Pathol*. 2015;8(9):11814-8.
- Mergen H, Genç H, Tavusbay C. Assessment of liver hydatid cyst cases 10 years' experience in Turkey. *Trop Doct*. 2007;37(1):54e6.
- Malik AA, ul Bari S, Younis M, Wani KA, Rather AA. Primary splenic hydatidosis. *Indian J Gastroenterol*. 2011;30:175-7.
- Masoodi I, Nabi G, Kumar R, Lone MA, Khan BA, Naseer Al Sayari K. Hydatid cyst of pancreas: a case report and brief review. *Turk J Gastroenterol*. 2011;22:430-2.
- Ousadden A, Elboudhaddouti H, Ibnmajdoub KH, Mazaz K, Aittaleb K. Primary Hydatid cyst of pancreas with a hepatic pedicle compression. *Cases J*. 2009;2:201.
- Eckert J, Deplazes P. Biological, epidemiological, and clinical aspects of Echinococcosis, a zoonosis of increasing concern. *Clin Microbiol Rev*. 2004;17:107-35.
- Thomas S, Mishra MC, Kriplani AK, Kapur BM. Hydatidemia: a bizarre presentation of abdominal hydatidosis. *Aust N Z J Surg*. 1993;63:496-8.
- Stamatakis M, Kontzoglou K, Tsaknaki S, Sargeti C, Iannescu R, Safioleas C, et al. Intrahepatic bile duct rupture of hydatid cyst: a severe complication for the patient. *Chirurgia (Bucur)*. 2007;102:257-62.
- WHO Informal Working Group. International classification of ultrasound images in cystic echinococcosis for application in clinical and field epidemiological settings. *Acta Tropica*. 2003;85(2):253-61.
- Kalovidouris A, Gouliamos A, Vlahos L. MRI of abdominal hydatid disease. *Abdom Imaging*. 1994;19:489-94.
- Patkowski W, Krasnodębski M, Grąt M, Masior L, Krawczyk M. Surgical treatment of hepatic Echinococcus granulosus. *Gastroenterolo Rev*. 2017;12(3):199-202.
- Junghans T, da Silva AM, Horton J, Chiodini PL, Brunetti E. Clinical management of cystic echinococcosis: state of the art, problems, and perspectives. *Am J Trop Med Hyg*. 2008;79:301-11.
- Gupta N, Javed A, Puri S, Jain S, Singh S, Agarwal AK. Hepatic hydatid: PAIR, drain or resect? *J Gastrointest Surg*. 2011;15:1829-36.

17. Saidi F. Surgery of hydatid disease. Philadelphia: Saunders; 1976.
18. Georgiou GK, Lianos GD, Lazaros A. Surgical management of hydatid liver disease. *Int J Surg* 2015;20:118-22.
19. Zaharie F, Bartos D, Mocan L, Zaharie R, Iancu C, Tomus C. Open or laparoscopic treatment for hydatid disease of the liver? A 10-year single-institution experience. *Surg Endosc*. 2013;27:2110-6.
20. Acarli K. Controversies in the laparoscopic treatment of hepatic hydatidosis. *HPB*. 2004;6(4):213-21.

Cite this article as: Thota A, Reddy AD, Rao VNV. Surgical treatment of Abdominal Echinococcosis. *Int Surg J* 2018;5:3831-6.