

## Original Research Article

# A comparative study of traditional and digital method in teaching surgical pathology to undergraduate medical students

Hemant K. Nautiyal<sup>1\*</sup>, Priyank Pathak<sup>1</sup>, Ruchira Nautiyal<sup>2</sup>, Guruvansh Sachdev<sup>1</sup>, Shubham Pandey<sup>3</sup>

<sup>1</sup>Department of Surgery, <sup>2</sup>Department of Obstetrics and Gynaecology, <sup>3</sup>Department of Biostatistics, SRH University, Jollygrant, Dehradun, Uttarakhand, India

**Received:** 22 November 2017

**Accepted:** 27 December 2017

### \*Correspondence:

Dr. Hemant K. Nautiyal,  
E-mail: [drnauty1@gmail.com](mailto:drnauty1@gmail.com)

**Copyright:** © the author(s), publisher and licensee Medip Academy. This is an open-access article distributed under the terms of the Creative Commons Attribution Non-Commercial License, which permits unrestricted non-commercial use, distribution, and reproduction in any medium, provided the original work is properly cited.

## ABSTRACT

**Background:** During undergraduate medical course surgical pathology is taught on formalin preserved specimens (FPS), a traditional teaching method. These specimens are morphologically altered in color and size due to chemical effect of formalin. Author believe that surgical pathology and disease process can be better understood by digital pictures and videos of surgical procedures. Hence, author did this intervention study to compare the teaching of surgical pathology by traditional method (i.e. Formalin preserved specimen) with digital method.

**Methods:** This prospective study was conducted at Department of Surgery, Himalayan Institute of Medical Sciences, Swami Rama Himalayan University. Final year MBBS (Bachelor of Medicine, Bachelor of Surgery). Students (Four Batches, 20-25 students, n=91) were taught surgical pathology by digital method (per operative and resected specimen pictures/videos) and traditional method (Formalin preserved specimen). Four specimens were taught with cross over i.e. two specimens with help of digital method and two by traditional method. Before start of teaching pretest (Multiple choice Questions, MCQ) was taken and it was followed by post-test (MCQ) for each topic. All teaching was done by single associate professor of surgery. Response of students was assessed by Likert's scale. Evaluation of the results was done by paired t-test.

**Results:** 94.3% students liked new method of teaching and 90.8% believed that new method leads to better understanding of the subject. In two specimens (Appendix and Gall Bladder) taught by digital method there was statistically significant increase in post test score as compared to FPS method. In specimens (carcinoma colon and breast carcinoma) there was also increase in the post test score though not statistically significant.

**Conclusions:** Digital method was found to be better method for understanding surgical pathology and clinical correlation and should be used to complement traditional method.

**Keywords:** Digital pictures, Digital teaching, Formalin preserved specimen, Preoperative videos, Surgical pathology, Traditional teaching

## INTRODUCTION

Pathology bridges the gap between basic sciences and clinical medicine, so a proper understanding of pathological processes is vitally important for medical practice. The main goal of undergraduate pathology

teaching has always been to provide a language or framework for the description of disease and to provide students with knowledge of the functional and structural changes in disease so that clinical signs and symptoms can be understood and interpreted.<sup>1</sup> In Indian subcontinent during MBBS course for understanding of

surgical pathology and disease process formalin preserved specimens (FPS) are taught. The disadvantage of formalin preserved specimen is that the preservative chemically alters the morphology and color of specimen. Most preservatives also cause shrinkage in size.<sup>2</sup> The specimen morphologically does not resemble the pathology for which it was removed, and many times students fail to even identify the organ leave aside the pathology. It leads to poor understanding of the pathology of surgical diseases and poor clinical correlation with sign and symptoms. Formalin has also been classified as carcinogen by international agency for research on cancer (IARC) hence its use in preserving specimen should be avoided.<sup>3</sup> It is also inflammable and toxic as there is evaporation in the form of gases or spillage of liquid during handling. Apart from that author can preserve limited number of specimen as it requires space and man power while by using digital technology several specimens may be filmed at different times, later transferred to the computer and edited for teaching purpose. With new technologies allowing digital capture and recording of surgical procedures the use of such technologies could play a role in the surgical training.<sup>4</sup> Author conducted this study with premise that teaching surgical pathology with per operative and resected specimen pictures and videos will lead to better understanding and insight into the disease process, and students will be able to correlate clinical signs and symptoms better.

## METHODS

This study was conducted at Himalayan Institute of Medical Sciences, Dehradun on 2011 batch MBBS students from December 2015 to September 2016. It is an intervention study with cross over design and sample size of 91 students. Final year students (Four Batches, each batch 20-25 students, n=91) were taught surgical pathology on formalin preserved specimen and by per operative and resected specimen pictures and videos (Digital method) of same difficulty. Batches were preformed groups made by Swami Rama University for their clinical posting (2011) batch. All teaching was done by single Associate Professor of surgery (corresponding author)

Four specimens were taught with cross over design:

- Cholecystectomy specimen for chronic cholecystitis and cholelithiasis
- Appendicectomy specimen for appendicitis
- Right Hemicolectomy specimen for carcinoma ascending colon
- Modified Radical Mastectomy (MRM) specimen for Carcinoma Breast

Specimens were selected on the basis of most commonly asked specimen in exams and most common surgical procedures performed. Combination was made with one relatively easy to answer and one difficult specimen

based on performance of students of previous batches. (Table 1).

**Table 1: Teaching method and specimen.**

Batch (2011)	Digital method	FPS method
A	Appendix/breast	Gall bladder/colon
B	Gall bladder/colon	Appendix/breast
C	Appendix/breast	Gall bladder/colon
D	Gall bladder/colon	Appendix/breast

Pre-test and post-test was taken to see change in student performance level. A MCQ-based pre-test, comprising of 10 questions was taken before teaching followed by post-test after teaching by scheduled method. Questionnaire was prepared by Face validity and Content validity. Each question was of one mark with total 10 marks in each pre-and post-test. Pre-and post-test Questionnaire were same and there was no negative marking. These questions were framed keeping in mind higher order of learning like how, why etc.

Questionnaire (Five-point Likert's Scale) for student feedback regarding the teaching methods, was given to students to evaluate which method they liked, which method is more interesting, which method led to better understanding of the subject, which method led to better understanding of signs and symptoms.

## Likert's Scale

- Strongly agree
- Agree
- Neutral
- Disagree
- Strongly disagree

## Statistics analysis

5-point Likert's scale was used to assess the response of students for the new method. Results were expressed in percentages. Independent 't' test was applied to analyse the difference of score between pre-test and post-test.

## RESULTS

**Table 2: Appendix (appendicectomy).**

	Digital (n=42)	FPS (n=43)	P value
Pre-test	6.78±1.37	6.60±1.17	0.515
Post-test	8.74±1.06	8.26±1.11	0.044

Total 42 (two batches) students were taught appendicectomy specimen by digital pictures and per operative videos of acute appendicitis and 43 students (two batches) were taught by Traditional method i.e. FPS (Table 2). There was statistically significant ( $p<0.044$ ) more increase in post-test score of Digital method as

compared to traditional method Mean pre-test score was  $(6.78+6.60/2)$  6.69 (Table 2).

Total 44 (two batches) students were taught Cholecystectomy (Gall Bladder) specimen by digital pictures and per-operative videos of chronic cholecystitis and 40 students (two batches) were taught by traditional method i.e. FPS. There was statistically significant ( $p<0.002$ ) more increase in post-test score of digital method as compared to traditional method. Mean pre-test score was  $(6.89+6.40/2)$  was 6.65 (Table 3).

**Table 3: Gall bladder (cholecystectomy).**

	Digital (n=44)	FPS (n=40)	P value
Pre-test	6.89±1.28	6.40±1.0	0.065
Post-test	8.57±0.95	7.85±1.14	0.002

Total 41 (two batches) students were taught breast carcinoma (MRM) specimen by digital pictures and per-operative videos and 42 students (two batches) were taught by Traditional method i.e. FPS. There was more increase in post-test score in digital method  $(7.71-4.71=3)$  as compared to Traditional method  $(7.60-5.14=2.46)$ , though this increase was not statistically significant ( $p=0.69$ ). Mean pre-test score was  $(4.71+5.14/2)$  was 4.93 (Table 4).

**Table 4: Breast carcinoma (modified radical mastectomy).**

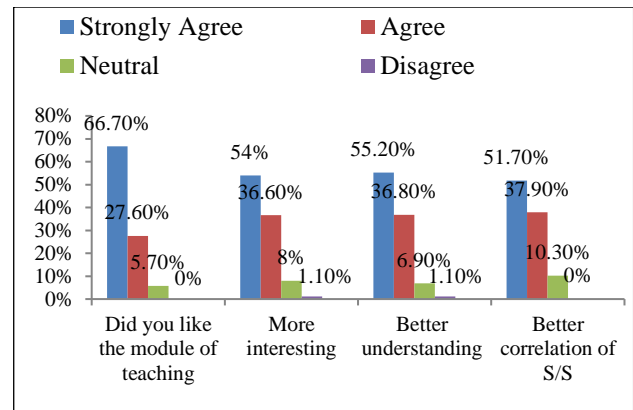
	Digital (n=41)	FPS (n=42)	P value
Pre-test	4.71±1.52	5.14±1.37	0.174
Post-test	7.71±1.41	7.60±1.17	0.695

Total 47 (two batches) students were taught carcinoma ascending colon (Right hemicolectomy) specimen by digital pictures and per-operative videos and 44 students (two batches) were taught by traditional method i.e. FPS. There was more increase in post-test score in digital method  $(7.74-4.89=2.85)$  as compared to traditional method  $(7.25-4.73=2.52)$ , though this increase was not statistically significant ( $p=0.06$ ). Mean pre-test score was  $(4.89+4.73/2)$  was 4.81 (Table 5).

**Table 5: Colon carcinoma (right hemicolectomy).**

	Digital (n=47)	FPS (n=44)	P value
Pre-test	4.89±1.40	4.73±1.33	0.564
Post-test	7.74±1.13	7.25±1.34	0.061

94.3% (Strongly agree and agree) students liked new method (Digital method) of teaching. 90.8% (Strongly agree and agree) students found this digital method to be more interesting. 90.8% (Strongly agree and agree) believed that digital method leads to better understanding of the subject. 89.8% (Strongly agree and agree) found digital method leads to better correlation of signs and symptoms (Figure 1).



**Figure 1: Response of students to teaching method (Likert's Scale).**

## DISCUSSION

In November 1906, Hubert Maitland Turnbull, a founder member of The Pathological Society, was appointed Director of the Institute of Pathology at the London Hospital. He recalls in his memoirs that shortly after taking up the post. Author realized how greatly handicapped my students were by having no knowledge of what for instance a solid lung or fibrotic liver was like or even understanding pathological terms.<sup>1</sup> A century later, Turnbull's words strike a familiar chord with pathology teachers as well as surgeons nationwide.<sup>1</sup>

In the last 100 years, the role of pathology in the undergraduate curriculum has turned full circle from being a supporting act, to playing a major role, to be a bit-part player once again. But method used to teach surgical pathology in undergraduate course has remained the same (Teaching on formalin preserved specimens), which were decades back.

While most of the undergraduates in medical colleges of India are Millennials. Millennials, defined as those individuals born between 1982 and 2001, are digital natives who are accustomed to multitasking and the continuous use of digital devices.<sup>5,6</sup> Recent advances in photographic and computer technology allow pathologists to easily capture digital images of surgical specimens. Because of these advances, digital technology has greatly improved the process of manipulation, presentation, distribution, and archiving of image. Digital video files can easily be incorporated into the digital materials already used for teaching medical students and residents and for continuing medical education.

Digital technology has greatly facilitated the documentation of surgical specimens by pathologists, both in surgical and autopsy pathology, by improving the processes of acquisition, distribution, and presentation of specimen photographs.<sup>7-9</sup> Digital photographs document the true appearances of the pathological changes and may eliminate inaccuracies resulting from storage in formalin.

Since pathology is a visual science, the inclusion of quality digital images into lectures, teaching handouts and electronic documents is crucial.<sup>9</sup> Virtual reality (VR) technology, also described as immersive imaging, provides the opportunity to present, and interact with, specimens as three-dimensional structures. This approach permits a better understanding of the features of the specimen by allowing the demonstration of structural details from many angles.<sup>10,11</sup>

Melin-Aldana H and Sciortino D found that QTVR movies are also of great potential use in teaching, when it is not possible or practical to maintain an adequate organ “museum,” such as a collection of hearts with congenital anomalies and subjects in their study reported more efficient learning of object structure using this interactive technology, compared with using passive observation. They proposed that the use of QTVR technology has an important place in the demonstration of surgical specimens, making a significant contribution to the teaching of anatomic pathology.<sup>12</sup>

Even in training of surgical resident’s role of digital photography and videos have been documented. Advances in computer technology, video cameras, and smartphones play a vital role in clinical medicine and have revolutionized how surgeons care for patients both inside and outside of the operation room.<sup>13</sup>

Video recordings of training and intraoperative sessions give residents further exposure to the steps and skills employed in specific operations, augmenting their preparation for the OR and compensating for the decreased amount of time spent therein.<sup>14</sup>

Additionally, utilizing digital images for teaching and consultation can be more effective for storage purposes and have easier accessibility as compared to FPS. Assessment in Digital method also becomes easy by inclusion of annotations to pictures and videos of specimens.

Despite of these advantages digital technology is not used in Indian Medical colleges for teaching of surgical pathology though its advantages have been proven in training of surgical pathology and surgical residents training in particular worldwide. Apart from this FPS teaching has its own problems even when specimens could be kept in their original state for teaching purposes, such as hearts with congenital malformations, some pathology departments lack the facilities for storing these specimens after they accumulate through the years the potential legal implications of the storage of the actual specimens have been well documented.<sup>15</sup>

Interestingly author found very encouraging results on use of digital method in our study. When response of undergraduate students was assessed using Likert’s scale more than 90 percent students liked the new method of teaching and found it more interesting. More than 90

percent believed that it has led to better understanding of the subject and better correlation of signs and symptoms (Figure 1). Our study provided objective evidence by conducting pre-and post-tests with both methods of teaching. MCQ questions were designed to evaluate the higher domains of learning like how and why. In two specimens (Appendix and Gall Bladder) taught by Digital Method there was statistically significant increase in post-test score as compared to FPS method proving that teaching surgical pathology with digital technology leads to better learning.

While in other two specimens (Breast and colon) there was more increase in post-test score in digital method as compared to Traditional method though this increase was not statistically significant. Mean pre-test score was low in breast as well as colon (4.93 and 4.81 respectively) in comparison to appendix and gall bladder (6.69 and 6.65 respectively) (Table 2,3,4,5). This could be due to the fact that appendix and gall bladder diseases are more frequently taught in surgery as these are common surgical diseases and more commonly performed surgeries. Hence students have more base line knowledge of these topics. So, during surgical pathology teaching there is more increase in knowledge as compared to diseases less commonly seen in surgery wards. And when dealing with less common diseases increase in post-test is less as compared to more common diseases. But further studies are required to validate this point. The limitations of this study were inconsistent attendance of students during the project i.e. all students didn’t attend all classes, all students were not of same caliber and also few digital pictures and videos were not of very good quality.

As Pitler said “Applied effectively technology not only increases students’ learning, understanding, and achievement, but also augments their motivation to learn, encourages collaborative learning, and develops critical thinking and problem-solving strategies.<sup>16</sup> Hence, we believe that, the future holds an incredible opportunity to harness technology for the education. To encourage innovation in surgical education is to open new portals for communication, assessment, and progress.

## CONCLUSION

Teaching surgical pathology by digital method not only leads to better understanding of signs and symptoms of disease but also is a more interesting method for understanding of the subject.

## ACKNOWLEDGEMENTS

Authors would like to thank Dr. Juhi Kalra, Professor and Head, Department of Pharmacology, SRH University, for assistance in planning the methodology and for comments that greatly improved the manuscript.

*Funding: No funding sources*

*Conflict of interest: None declared*

*Ethical approval: The study was approved by the Institutional Ethics Committee*

## REFERENCES

- Domizio P. The changing role of Pathology in the Undergraduate Curriculum. Available at: [www.pathsoc.org/files/history/c12.pdf?php](http://www.pathsoc.org/files/history/c12.pdf?php).
- Selecting carpets and floor coverings for exhibit galleries and visitor centers. Available at: <https://www.nps.gov/museum/publications/conservation/01-11.pdf>. Accessed 03 November 2001.
- Lester SC. Manual of Surgical Pathology E-Book. Elsevier Health Sciences; 2010 Jul 27.
- Gambauro P, Magos A. Digital recording of surgical procedures using a personal computer. *Eur Clin Obstet Gynaecol.* 2007;3(1):31-4.
- DiLullo C, McGee P, Kriebel RM. Demystifying the Millennial student: A reassessment in measures of character and engagement in professional education. *Anat Sci Edu.* 2011;4(4):214-26.
- Moreno-Walton L, Brunett P, Akhtar S, De-Blieux PM. Teaching across the generation gap: A consensus from the Council of Emergency Medicine Residency Directors 2009 academic assembly. *Acad Emerg Med.* 2009;16(12):S19-S24.
- Belanger AJ, Lopes AE, Sinard JH. Implementation of a practical digital imaging system for routine gross photography in an autopsy environment. *Arch Pathol Lab Med.* 2000;124:160-5.
- Leong AS, Visinoni F, Visinoni C, Milios J. An advanced digital image-capture computer system for gross specimens: a substitute for gross description. *Pathology.* 2000;32:131-5.
- Riley RS, Ben-Ezra JM, Massey D, Slyter RL, Romagnoli G. Digital photography: a primer for pathologists. *J Clin Lab Anal.* 2004;18:91-128.
- Trelease RB, Nieder GL, Dorup J, Hansen MS. Going virtual with QuickTime VR: new methods and standardized tools for interactive dynamic visualization of anatomical structures. *Anat Rec.* 2000;261:64-77.
- Nieder GL, Scott JN, Anderson MD. Using quick time virtual reality objects in computer-assisted instruction of gross anatomy: Yorick the VR skull. *Clin Anat.* 2000;13:287-93.
- Melin-Aldana H, Sciortino D. *Mod Pathol.* 2003;16(9):958-61.
- Rogers FB, Ricci M, Caputo M. The use of telemedicine for real-time video consultation between trauma center and community hospital in a rural setting improves early trauma care: preliminary results. *J Trauma.* 2001;51(6):1037-41.
- Kelly CR, Hogle NJ, Landman J, Fowler DL. High definition in minimally invasive surgery: A review of methods for recording, editing, and distributing video. *Surg Inn.* 2008;15(3):188-93.
- Bradbury J, Weber W. Consent requirements for necropsy may change in UK. *Lancet.* 1999;354:2055.
- Pitler H. Viewing technology through three lenses. *Principal Arlington.* 2006;85(5):38-42.

**Cite this article as:** Nautiyal HK, Pathak P, Nautiyal R, Sachdev G, Pandey S. A comparative study of traditional and digital method in teaching surgical pathology to undergraduate medical students. *Int Surg J* 2018;5:557-61.