

## Case Report

# An intraluminal jejunal gastrointestinal stromal tumor near DJ flexure with gastrointestinal bleed: a rare case report

Manish Bansal<sup>1\*</sup>, Sameer Gupta<sup>2</sup>, Kanika Goel<sup>3</sup>, Sulbha Mittal<sup>4</sup>

<sup>1</sup>Department of General Surgery, Haryana Civil Medical Services, Haryana, India

<sup>2</sup>Department of Oncosurgery, Command Hospital (WC), Panchkula, Haryana, India

<sup>3</sup>Department of Biochemistry, Haryana Civil Medical Services, Haryana, India

<sup>4</sup>Department of Radiation Oncology, Haryana Civil Medical Services, Haryana, India

**Received:** 13 August 2017

**Accepted:** 07 September 2017

### \*Correspondence:

Dr. Manish Bansal,

E-mail: [dr\\_mann2007@yahoo.co.in](mailto:dr_mann2007@yahoo.co.in)

**Copyright:** © the author(s), publisher and licensee Medip Academy. This is an open-access article distributed under the terms of the Creative Commons Attribution Non-Commercial License, which permits unrestricted non-commercial use, distribution, and reproduction in any medium, provided the original work is properly cited.

## ABSTRACT

Gastrointestinal stromal tumours (GISTs) are mesenchymal tumors arising in the gastrointestinal tract (GIT). In GIT, the most common site of presentation is stomach followed by small intestine, colon, rectum and oesophagus. Here we report a rare case of intraluminal jejunal GIST with history of pain abdomen, occasional vomiting and GI bleed. Patient was taken up for exploratory laparotomy. Intraoperative findings revealed a hard-nodular growth in antimesenteric border of jejunum, 5 cm distal to duodenojejunal flexure (DJ) partially obstructing the lumen. Anastomosis was quite difficult due to presence of growth near DJ flexure and chances of leak were high. The patient had an uneventful postoperative course and doing well after 1 year of follow up with no recurrence.

**Keywords:** CD 117, DJ flexure, Gastrointestinal bleed, Gastrointestinal stromal tumours

## INTRODUCTION

Gastrointestinal stromal tumours (GISTs) are mesenchymal tumors arising in the gastrointestinal tract (GIT) and occasionally elsewhere within the abdomen (omentum, peritoneum and retroperitoneum).<sup>1</sup> In GIT, the most common site of presentation is stomach followed by small intestine, colon, rectum and oesophagus.<sup>2</sup> The incidence of GIST is very low (i.e., 2 in 1,00,000) while jejunal GIST is extremely rare accounting for 0.1-3% of all gastrointestinal (GI) tumors.<sup>3</sup> Usually these are asymptomatic. Here we report a rare case of intraluminal jejunal GIST with history of pain abdomen, occasional vomiting and GI bleed.

## CASE REPORT

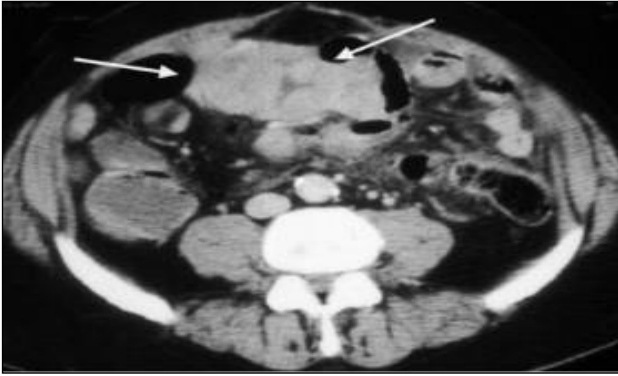A 48 year old female with no comorbidities presented with 1 month history of dull aching pain in umbilical

region and occasional vomiting. There were 3 episodes of melaena in last one week. On admission, her haemoglobin was 9.7 gm/dl. On examination, per abdomen findings were normal. No abnormality was detected on oesophagogastroduodenoscopy and colonoscopy. CECT abdomen revealed 4.5×4.0 cm well defined enhancing mass in proximal jejunum (Figure 1).

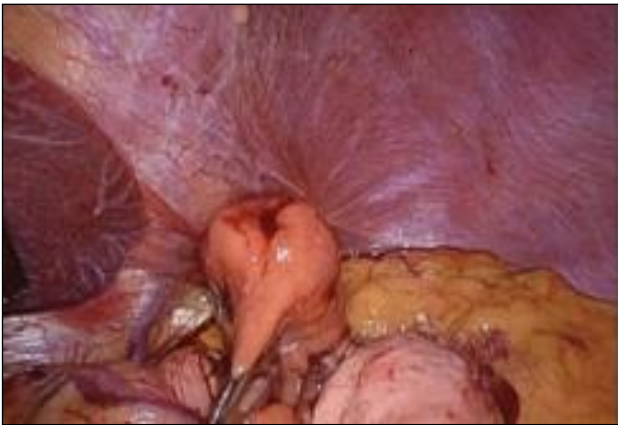Within this mass there was a hypodense area representing central necrosis. There was no lymphadenopathy or metastasis. Patient was taken up for exploratory laparotomy. Intraoperative findings revealed a hard-nodular growth in antimesenteric border of jejunum, 5 cm distal to duodenojejunal flexure (DJ) partially obstructing the lumen (Figure 2).

Haemorrhagic spots were seen in the growth. Resection of tumour with primary anastomosis was done. Anastomosis was quite difficult due to presence of

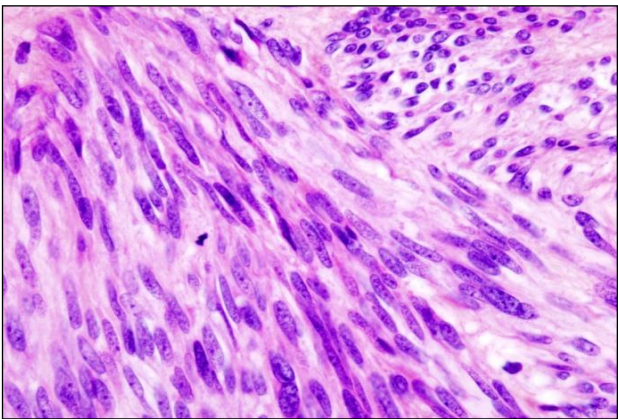
growth near DJ flexure and chances of leak were high. The patient had an uneventful postoperative course and doing well after 1 year of follow up with no recurrence.



**Figure 1: CECT of whole abdomen.**



**Figure 2: Intraoperative picture of jejunal tumour mass.**



**Figure 3: Histopathology slide of specimen.**

The histopathological examination (HPE) revealed submucosal tumour with central necrosis and areas of hemorrhages. The tumour consists of predominantly spindle cells with eosinophilic to clear cytoplasm (Figure 3).

The excision was complete with clear margins. Immunohistochemistry revealed c-kit (CD 117) positivity, which further confirmed the diagnosis of GIST.

## DISCUSSION

GIST constitutes a distinct group of rare gastrointestinal tract tumors that originate from or differentiate towards the interstitial cells of Cajal which are involved in regulation of gastrointestinal motility by pacemaker activity and also have a role in muscle relaxation.<sup>1</sup> GISTs are most common in adults predominantly at 50-60 years of age.<sup>1</sup> Both men and women are equally affected.<sup>4</sup> 20-30% of GISTs are malignant in nature but most (70-80%) are benign.<sup>2</sup>

GISTs occur most commonly in stomach (70%) followed by small intestine (20-30%) and remaining 10% in colon, rectum and oesophagus.<sup>2,5</sup> Jejunal GISTs are the rarest type among all types of GISTs.<sup>3</sup> The most common clinical manifestation for symptomatic GIST is occult gastrointestinal bleeding from mucosal ulceration. The tumor may also present as pain abdomen, lump abdomen, GI obstruction or may be an incidental finding in case of small lesion.

The diagnosis in small bowel GIST is difficult as these are inaccessible to endoscopy. CT imaging is done which shows heterogenous enhancement due to haemorrhage and necrosis. Diagnosis is confirmed with help of histopathology and immunohistochemistry. Immunocytochemical studies showed c-kit (CD117) and CD34 immunopositivity. The standard angiography has low specificity especially in light or intermittent bleeding. These patients usually end up with exploratory laparotomy to identify the source of the bleeding. CT angiography can overcome the shortage of standard angiography; multi detector row CT has an accuracy of 100% for localization of acute GI Bleeding.

The mainstay of management for jejunal GIST is a complete surgical excision. The surgical imperative is a complete gross resection with an intact pseudo-capsule and negative microscopic margins. Adjacent organs adherent to the mass should be resected en bloc with the tumour, in order to avoid capsule rupture and intra-abdominal spillage. Lymphadenectomy is usually not required because these tumours do not show lymph node metastases.<sup>6</sup> The presence of GIST near DJ flexure makes it difficult to make an anastomosis and chances of complications are high.

Imatinib mesylate is the first and only effective drug for treatment of GIST. It is used as an adjuvant therapy in high risk cases (tumour size >10 cm) after surgery. It is also recommended in metastatic, residual or recurrent cases of GISTs or which are surgically not removable.

Favourable prognosis for GIST are tumour size <10 cm, the lesion without metastases, low mitotic index and complete resection of the tumour with negative microscopic margins and with no intraperitoneal dissemination. However, regardless of the mitotic index, the location of the tumour in the small intestine and its size more than 5 cm predict an intermediate malignant potential. In patients who have undergone surgical resection of the GISTs, CT abdomen and pelvis is performed every 3-6 months for surveillance of metastatic or recurrent disease.

## CONCLUSION

Bleeding jejunal GIST is rare cause of GI bleeding and can be extremely difficult to diagnose due to inaccessibility of endoscopy. The mainstay of management for jejunal GIST is a complete surgical excision. The presence of GIST near DJ flexure makes it difficult to make an anastomosis and chances of anastomotic leak are high. Survival rate is increased with the use of imatinib mesylate.

*Funding: No funding sources*

*Conflict of interest: None declared*

*Ethical approval: Not required*

## REFERENCES

1. Fisher C. Gastrointestinal stromal tumors. In: Pignatelli M, Underwood JCE, editors. Recent Advances in Histopathology 21. The Royal Society of Medicine Press Limited; 2005:71-88.
2. Miettinen M, Lasota J. Gastrointestinal stromal tumours definition, clinical, histological, immunohistochemical and molecular genetic features and differential diagnosis. Virchows Arch. 2001;438(1):1-12.
3. Kramer K, Siech M, Sträter J, Aschoff AJ, Henne-Bruns D. GI hemorrhage with fulminant shock induced by jejunal gastrointestinal stromal tumor (GIST) coincident with duodenal neuroendocrine carcinoma (NET)+ neurofibromatosis (NF): case report and review of the literature. J Gastroenterol. 2005;43(3):281-8.
4. Gastrointestinal Stromal Tumors Treatment (PDQ)-National Cancer Institute[Internet]. USA: National Cancer Institute; 2009 [updated 2017 May 10]. Available at <https://www.cancer.gov/types/soft-tissue-sarcoma/hp/gist-treatment-pdq>.
5. Shanmugam S, Vijaysekaran D, Marimuthu MG. Gastro intestinal stromal tumor: a case report. Ind J Radiol Imaging. 2006;16:373-6.
6. Daldoul S, Moussi A, Triki W, Baraket RB, Zaouche A. Jejunal GIST causing acute massive gastrointestinal bleeding: role of multidetector row helical CT in the preoperative diagnosis and management. Arab J Gastroenterol. 2012;3(3):153-7.

**Cite this article as:** Bansal M, Gupta S, Goel K, Mittal S. An intraluminal jejunal gastrointestinal stromal tumor near DJ flexure with gastrointestinal bleed: a rare case report. Int Surg J 2017;4:3564-6.