

## Case Report

# 'Double Trouble' - management of iridodialysis and subluxated cataract in an eye with blunt injury

Arjun Srirampur\*, Sunny Manwani, Gangaprasad Amula, Pavani Reddy Andru

Department of Ophthalmology, Anand Eye Institute, Habsiguda, Hyderabad, Telangana, India

**Received:** 30 June 2017

**Accepted:** 26 July 2017

### \*Correspondence:

Dr. Arjun Srirampur,

E-mail: sarjuneye@gmail.com

**Copyright:** © the author(s), publisher and licensee Medip Academy. This is an open-access article distributed under the terms of the Creative Commons Attribution Non-Commercial License, which permits unrestricted non-commercial use, distribution, and reproduction in any medium, provided the original work is properly cited.

### ABSTRACT

The aim of this study was to report a case of iridodialysis repair along with cataract extraction and iris claw lens implantation in a case of superior iridodialysis with subluxated cataractous lens following a blunt ocular trauma.

**Keywords:** Iridodialysis, Retropupillary iris claw IOL, Subluxated cataract

## INTRODUCTION

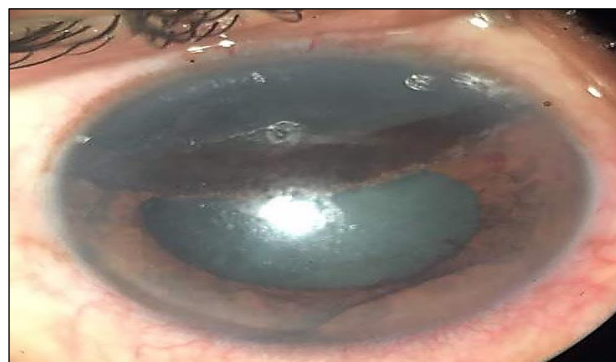Iris-lens injuries like iridodialysis, lens subluxation, and lens capsular rupture are the most common complications following a blunt ocular trauma. To achieve a good anatomical and functional outcome is a big challenge in these cases. The solution to such complication is to do an iridodialysis repair and lens implantation either as a combined procedure or a two-staged procedure.

To reach the goal of relieving uncomfortable symptoms such as photophobia, diplopia, or glare and to achieve a better cosmesis, reconstruction of the injured iris is required. To restore the anatomic integrity of the ruptured iris non-absorbable 10-0 prolene sutures are used either with a McCannel suturing technique or with a sewing machine technique.

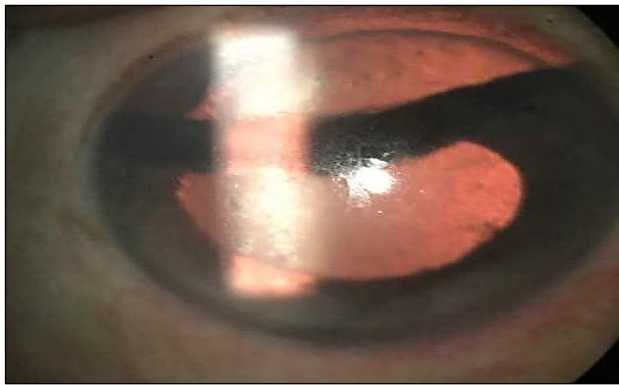The intraocular lens (IOL) options available for correcting the aphakia after cataractous lens removal in such cases are either anterior chamber, scleral fixated or iris fixated.<sup>1,2</sup> Preference is dependent upon an IOL's characteristics and a surgeon's experience.<sup>3</sup> We report a case of fixing Retropupillary Iris claw IOL after the complete repair of iridodialysis with an adequate midperipheral iris support.

## CASE REPORT

A 55-year-old male presented to us with a complaint of diminution of vision in the right eye following a blunt ocular trauma 3 months back. There were no relevant systemic complaints. No history of any past ocular surgery. Visual acuity in the right eye was counting fingers 1 meter and the left eye was 6/6. On examination left anterior segment and fundus were within normal limits.



**Figure 1: Slit lamp photo showing a large superior iridodialysis from 10 to 2'o clock position.**



**Figure 2: Retroillumination photo confirming the iridodialysis and subluxated cataract.**

Anterior segment examination in the right eye was suggestive of clear cornea with irregular anterior chamber depth, pigment dispersion and vitreous strands in the pupillary area. There was a presence of large superior iridodialysis extending from 10'o clock to 2'o clock (Figure 1) along with inferiorly subluxated and anteriorly dislocated cataractous lens of grade 3 (Figure 2) with phacodonesis and zonular dialysis superiorly from 10'o clock to 2'o clock. The fundus examination in the right eye was suggestive of retinal pigment epithelium (RPE) alterations in the macular area. The intraocular pressure (IOP) was within normal limits. Hence a iridodialysis repair along with cataract extraction with IOL placement was planned in his right eye.

#### **Surgical technique**

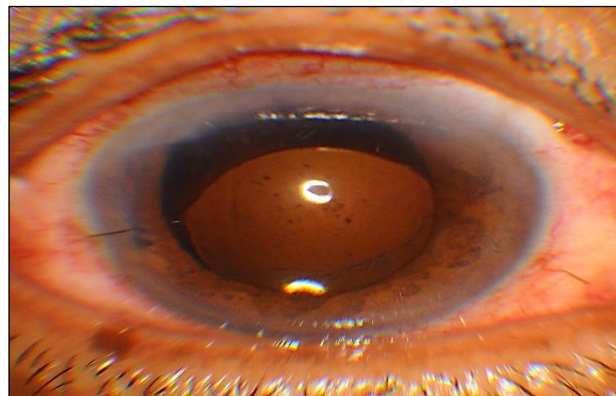
The surgery done under all aseptic precautions and with peribulbar anaesthesia with 2% lignocaine with adrenaline and 0.5% bupivacaine. Iridodialysis was first repaired by making a scleral tunnel incision 2-3 mm posterior to the limbus around the site of the iridodialysis. The IOP and anterior chamber was maintained throughout the surgery by inserting a 20-gauge infusion cannula in the inferior temporal scleral quadrant.

The McCannel suturing technique was used to put the sutures at 11'o clock, 12'o clock, and 1'o clock. A cataract surgery-type incision is made at the site of iridodialysis or iris disinsertion. A double-armed, 10-0 polypropylene suture was passed through the scleral bed within the tunnel, then the iris root, then through the detached iris and reversed in direction from an already performed limbal stab incision at 6'o clock position. Then the needle was brought out through the scleral bed and tied on the surface of the sclera under a partial-thickness scleral flap.

Then the tunnel (sclerocorneal incision) was extended to 5.5 mm. The intracapsular cataract surgery was performed to take out the subluxated cataractous lens in view of large subluxation (>3 clock hours). After doing good anterior vitrectomy the iris claw lens was fixed with

the claws tucked at 3 and 9'o clock positions behind the pupillary area under the iris. The corneoscleral wound is then closed with 10-0 nylon interrupted sutures.

Post operatively his visual acuity improved to 6/24 with no complaints of glare or diplopia. There was a good anatomical outcome of iridodialysis repair with a round central reacting pupil at 3 months follow-up (Figure 3). The IOL was stable and the cornea clear. His IOP and fundus examination were within normal limits.



**Figure 3: Post dilated state showing round pupil with iris claw IOL in place.**

#### **DISCUSSION**

There are many procedures to do iridodialysis repair. The most common procedures used to repair the iridodialysis are McCannel suture technique and sewing machine technique or the cobbler's method of iridodialysis repair.<sup>4-6</sup> McCannel suture technique is simple and provides the least amount of ocular manipulation for iridodialysis repair. Implantation of an IOL in an aphakic eye without capsular support is technically complicated and varies based on patient age, iris and pupil status, as well as surgeons' preferences. Suspension of a scleral or sulcus-fixated PCIOL is frequently used surgical technique, particularly since modified novel procedures have been introduced.<sup>7</sup> The advantages of this type of procedure are a natural position, lack of corneal endothelial cell decompensation, and lack of pressure, which could rupture the iris or pupil. An anterior chamber IOL needs the iris support and is easy to insert; however, there is the possibility of endothelial cell loss and pupil deformation. Many reports have shown the implantation of an iris-claw IOL is simple, safe, and efficient for short-term or long-term use.<sup>8,9</sup> The advantages of the iris-claw IOL are that insertion is easy, no suture is needed for fixation, it is reversible, and there is little corneal endothelial cell loss.

Whether the sutured iris was sufficiently strong to support an iris-claw IOL was our concern, for example, unknotting of the iridodialysis suture or posterior dislocation of the iris-claw IOL. In a study done by Shufang Hu et al, 4 years of follow-up demonstrated the

sutured iris remained well-shaped, except in one child who had a loose knot, but his IOL remained in the proper position without dislocation.<sup>10</sup> All the 11 patients, both children and adults, maintained their regular daily activities after surgery. Hence, we can assume that the iris-claw IOL may not interfere with the sutured iris. Our patient could not improve visual acuity of more than 6/24 due loss of the photoreceptors under the foveal area confirmed on OCT which might have due to blunt trauma after the berlins edema has resolved. But there was an excellent anatomical improvement.

## CONCLUSION

Our case highlights the possibility of repairing the iridodialysis and also tackling the subluxated cataract in a single sitting. A retrofixed iris claw lens fixation can be a simple, safe and effective option in the presence of good iris tissue and absence of capsular support. Also fixing an iris claw lens to a sutured iris tissue has shown a good anatomical outcome and visual rehabilitation.

*Funding: No funding sources*

*Conflict of interest: None declared*

*Ethical approval: Not required*

## REFERENCES

1. Bellamy JP, Queguiner F, Salamé N, Montard M. Secondary intraocular lens implantation: methods and complications. J Fr Ophtalmol. 2000;23(1):73-80.
2. Kumar DA, Agarwal A. Glued intraocular lens: a major review on surgical technique and results. Curr Opin Ophthalmol. 2013;24(1):21-9.
3. Rao R, Sasidharan A. Iris claw intraocular lens: a viable option in monocular surgical aphakia. Indi J Ophthalmol. 2013;61(2):74.
4. McCannel MA. A retrievable suture idea for anterior uveal problems. Ophthalmic Surg. 1976;7(2):98-103.
5. Pandav SS, Gupta PC, Singh RR, Das K, Kaushik S, Raj S, et al. Cobbler's technique for Iridodialysis repair. Middle East Afr J Ophthalmol. 2016;23(1):142-4.
6. Blackmon DM, Lambert SR. Congenital iris coloboma repair using a modified McCannel suture technique. Am J Ophthalmol. 2003;135(5):730-2.
7. Hoffman RS, Fine IH, Packer M. Scleral fixation without conjunctival dissection. J Cataract Refract Surg. 2006;32(11):1907-12.
8. Budo C. Another view of iris-claw IOL implantation. J Cataract Refract Surg. 2010;36:1801.
9. Tahzib NG, Nuijts RM, Wu WY, Budo CJ. Long-term study of Artisan phakic intraocular lens implantation for the correction of moderate to high myopia: Ten-year follow-up results. Ophthalmol. 2007;114:1133-42.
10. Hu S, Wang M, Xiao T, Zhao Z. Iris reconstruction combined with iris-claw intraocular lens implantation for the management of iris-lens injured patients. Indian J Ophthalmol. 2016;64(3):216-21.

**Cite this article as:** Srirampur A, Manwani S, Amula G, Andru PR. 'Double Trouble' - management of iridodialysis and subluxated cataract in an eye with blunt injury. Int Surg J 2017;4:3159-61.